

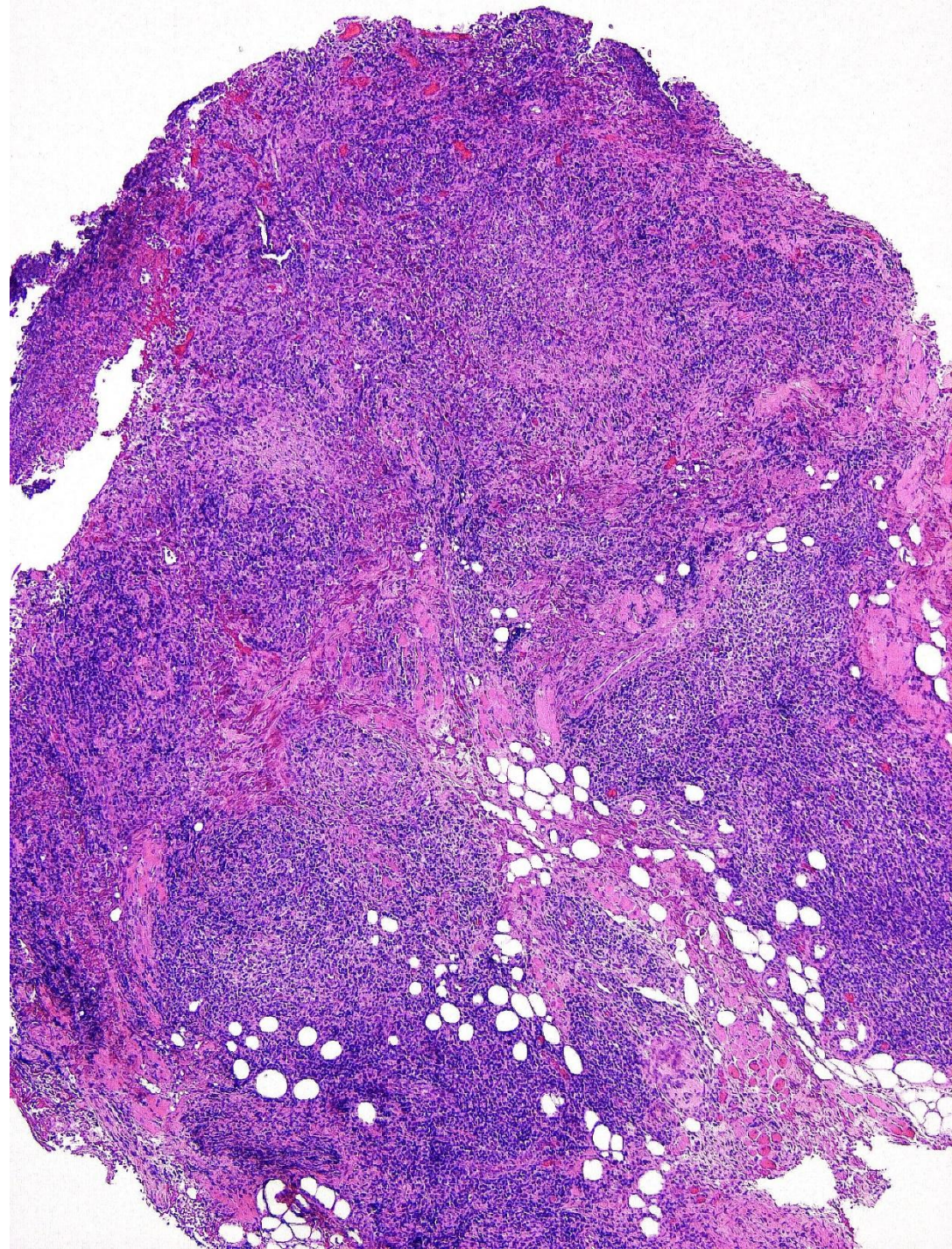
**DERMATOPATHOLOGY WORKSHOP
SELF-ASSESSMENT
ARAB DIVISION OF THE IAP
25 NOVEMBER 2015**

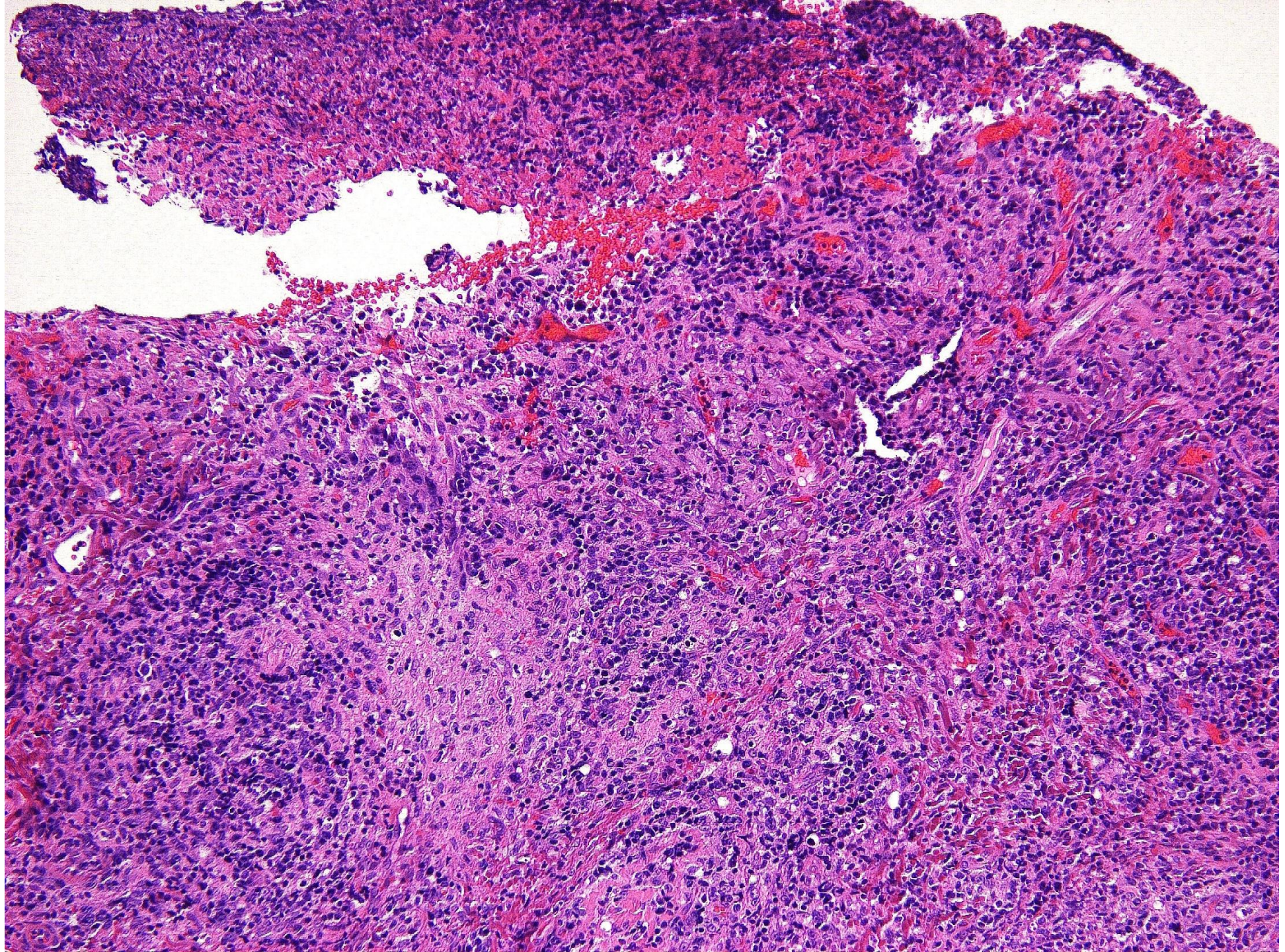
**Dr Eduardo Calonje
London, United Kingdom**

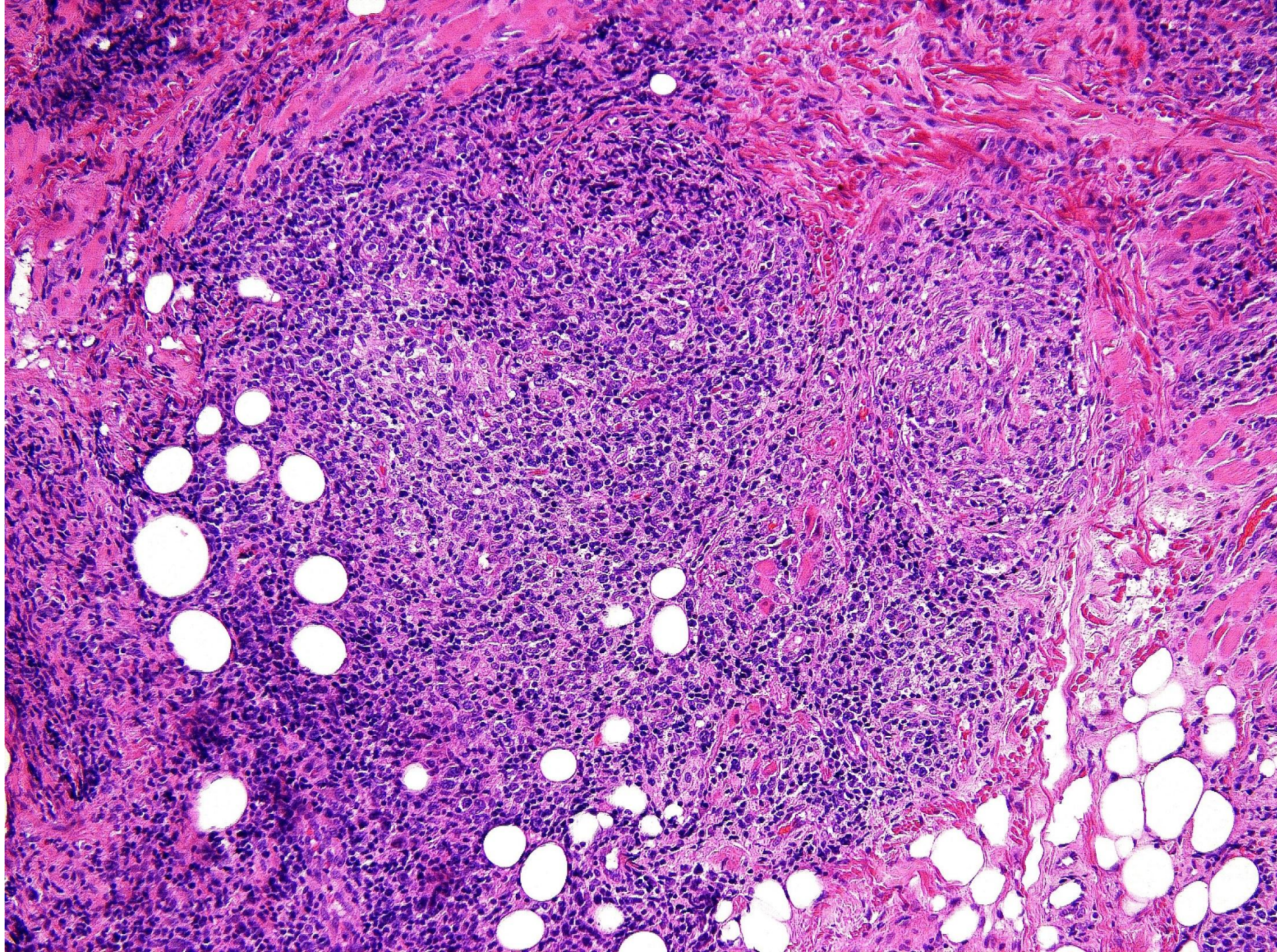
CASE 1

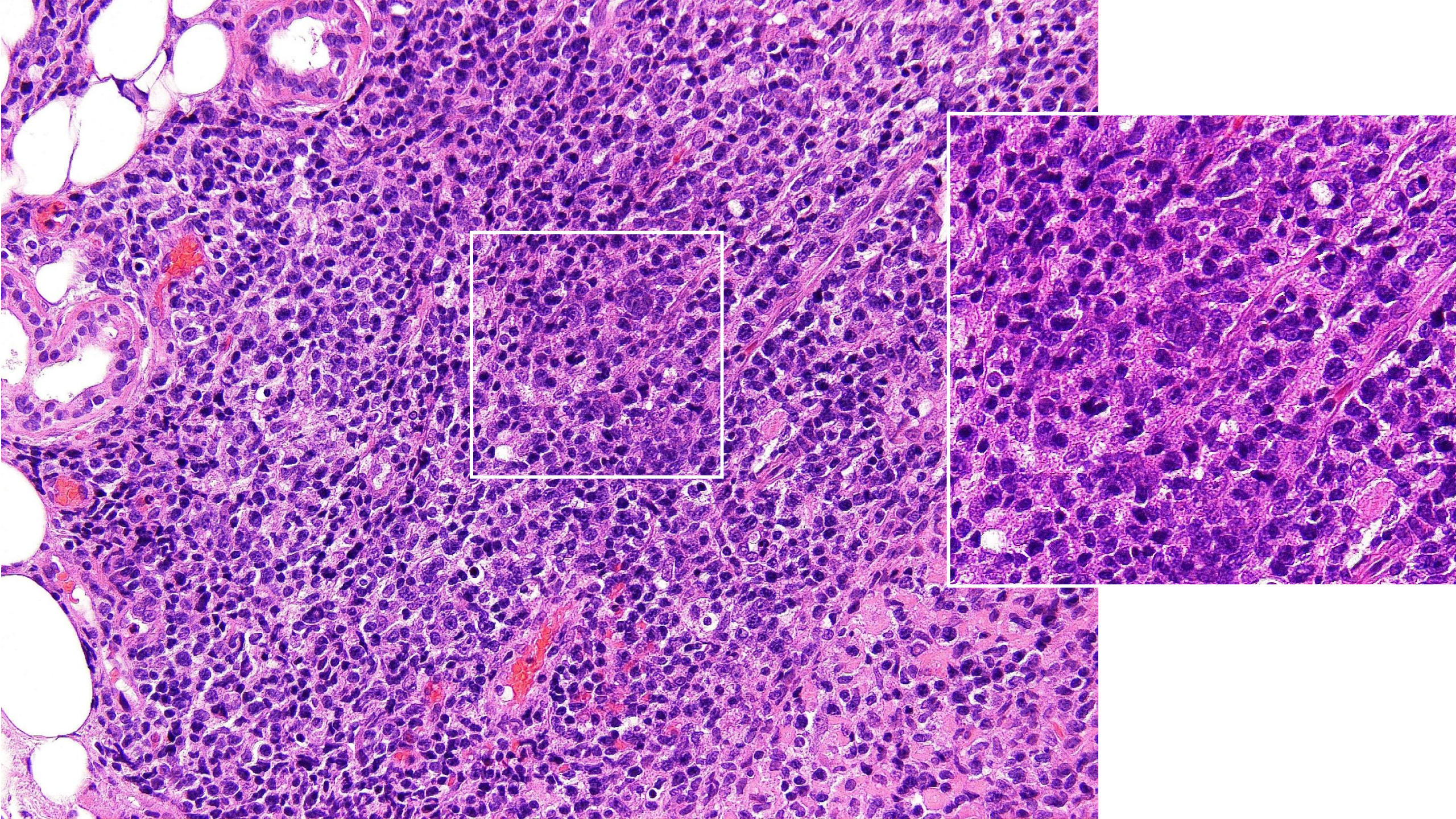
- 81-year-old man
- Develop two ulcerated cutaneous nodules on the upper lip and left cheek
- History of rheumatoid arthritis (AR), chronic kidney disease and atrial fibrillation
- Currently treated with Digoxin and Methotrexate (MTX)

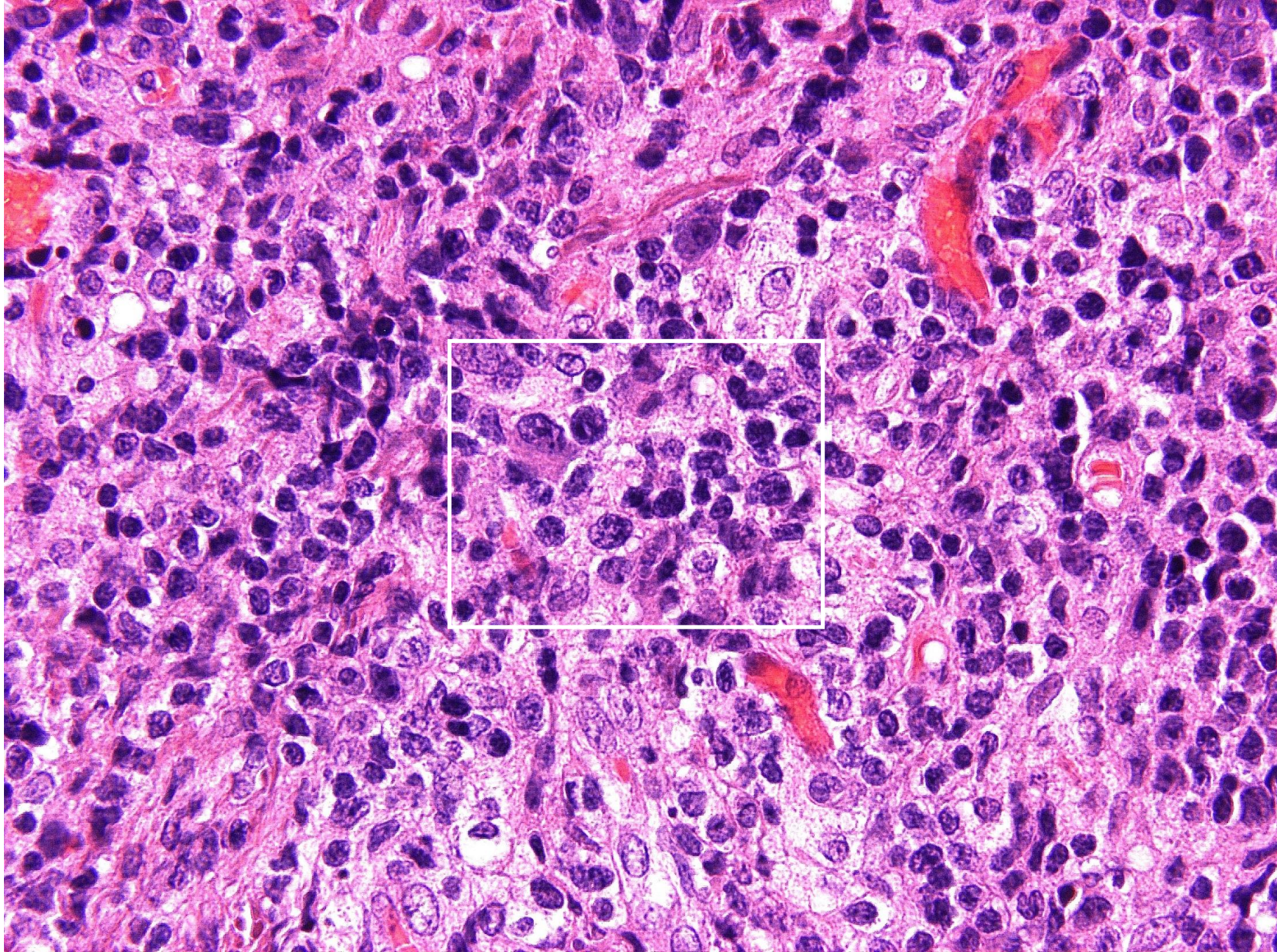
Histopathology

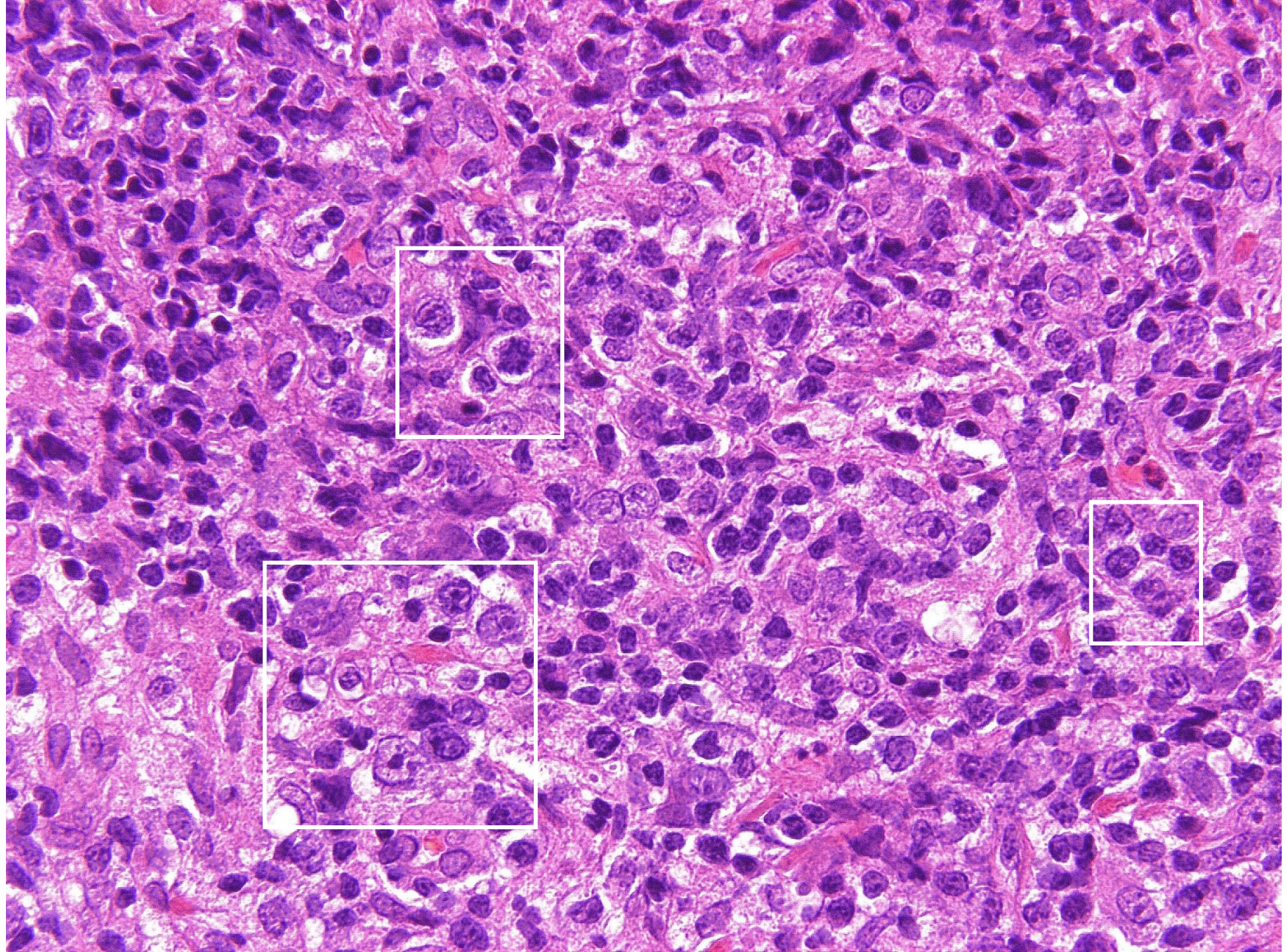


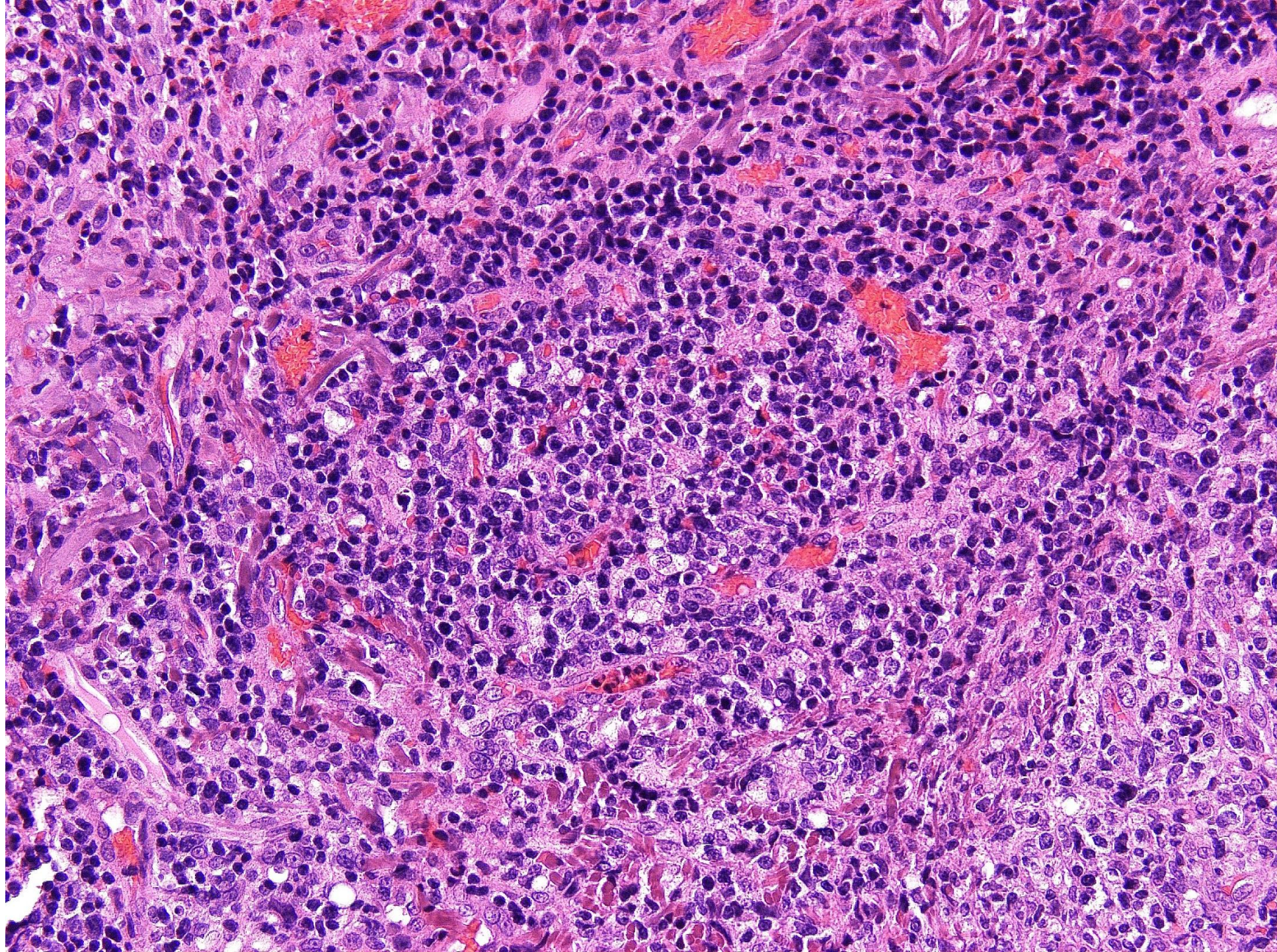




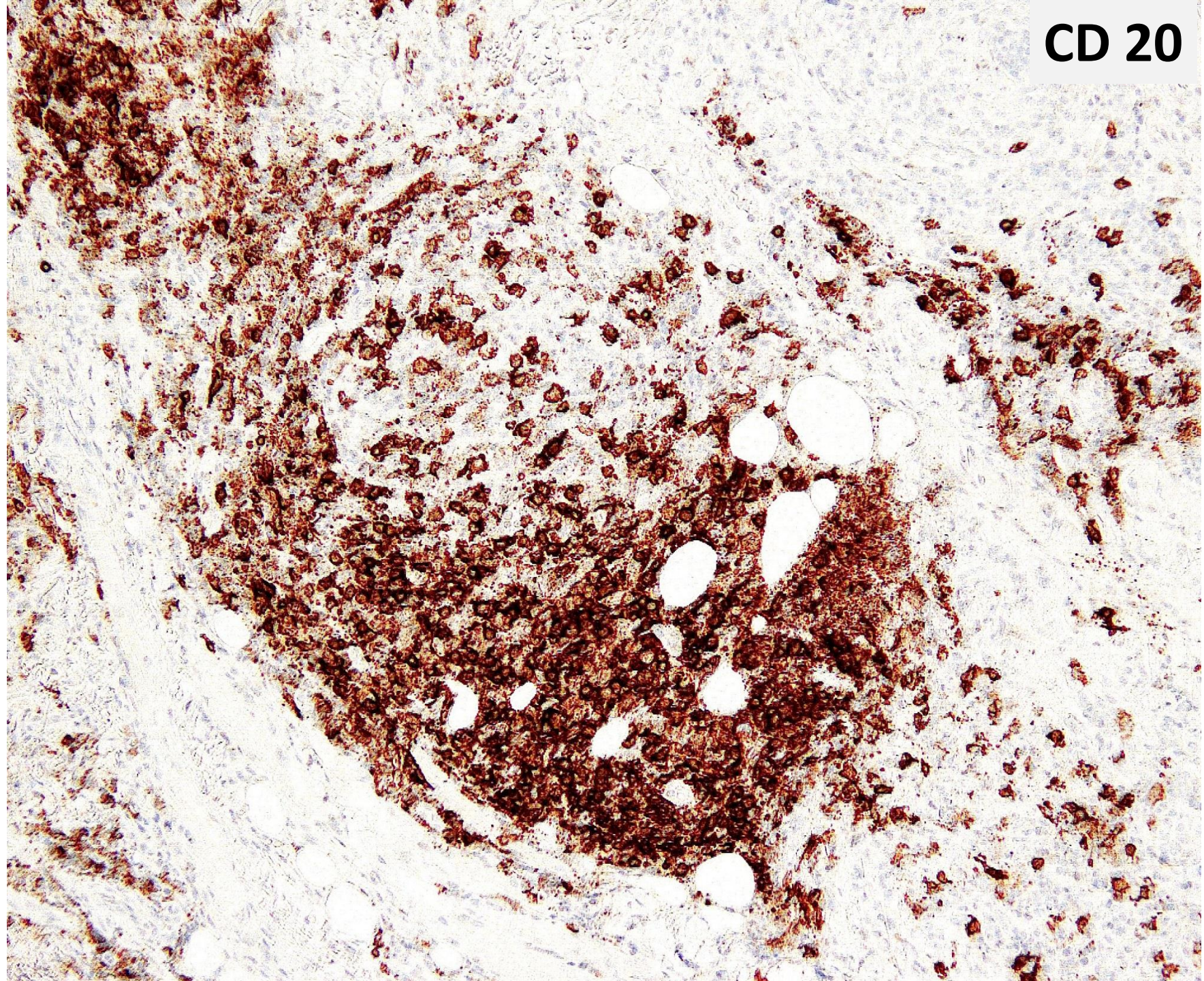


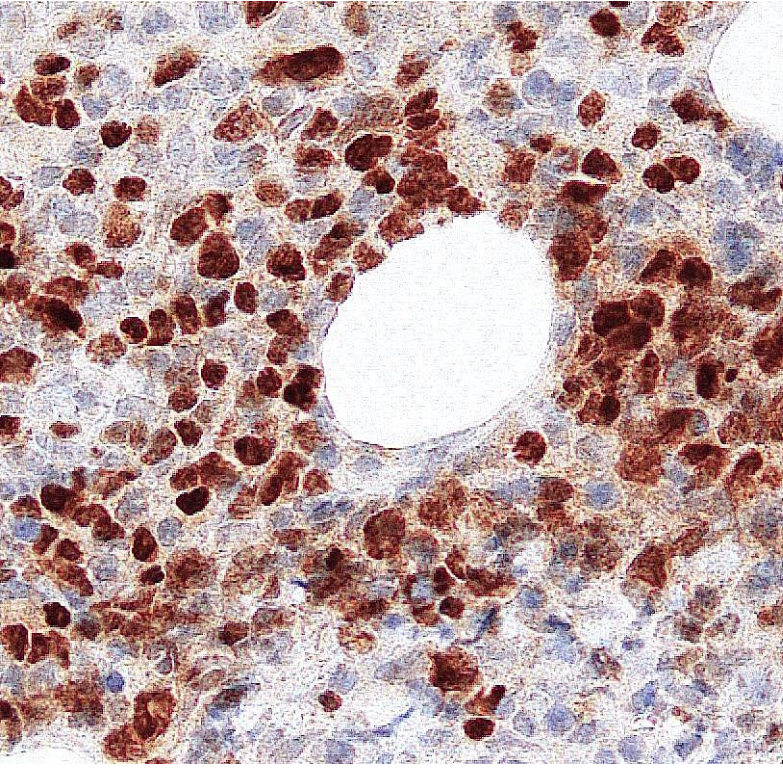




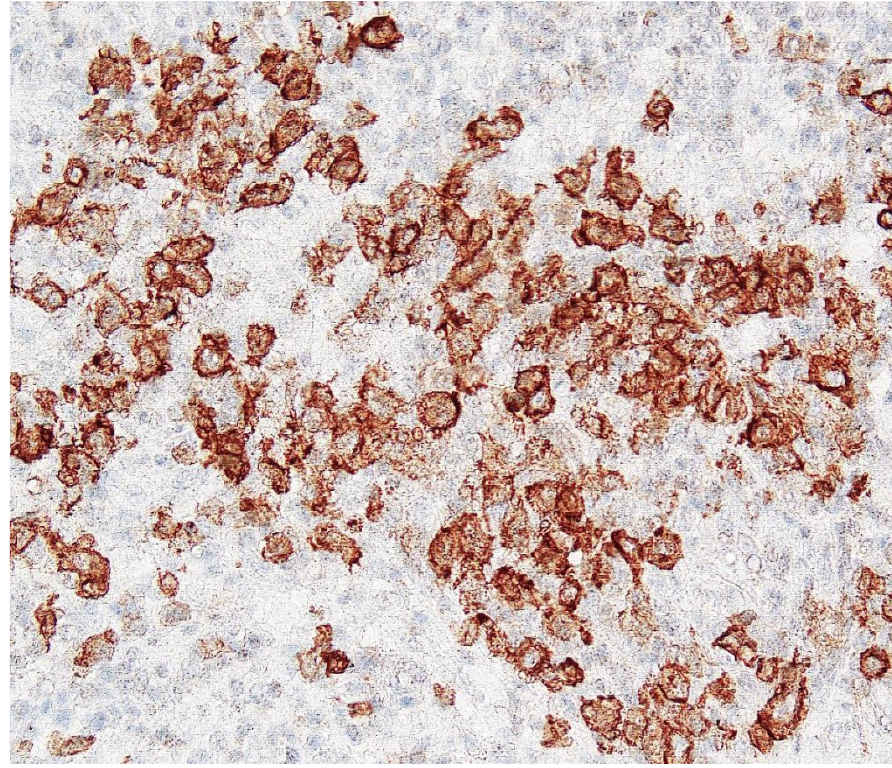


CD 20

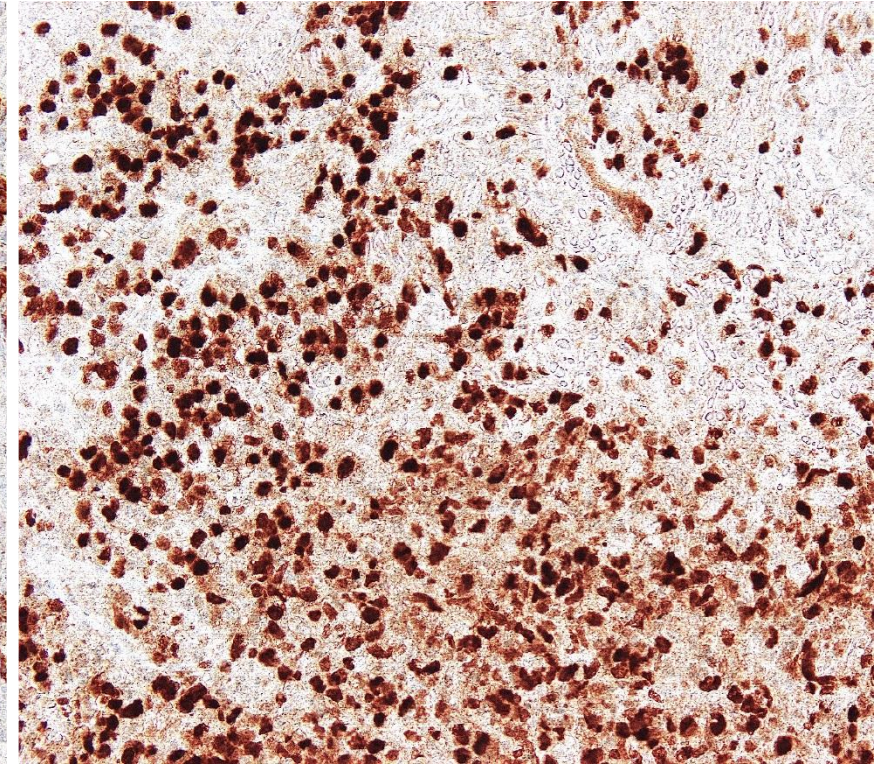




PAX-5



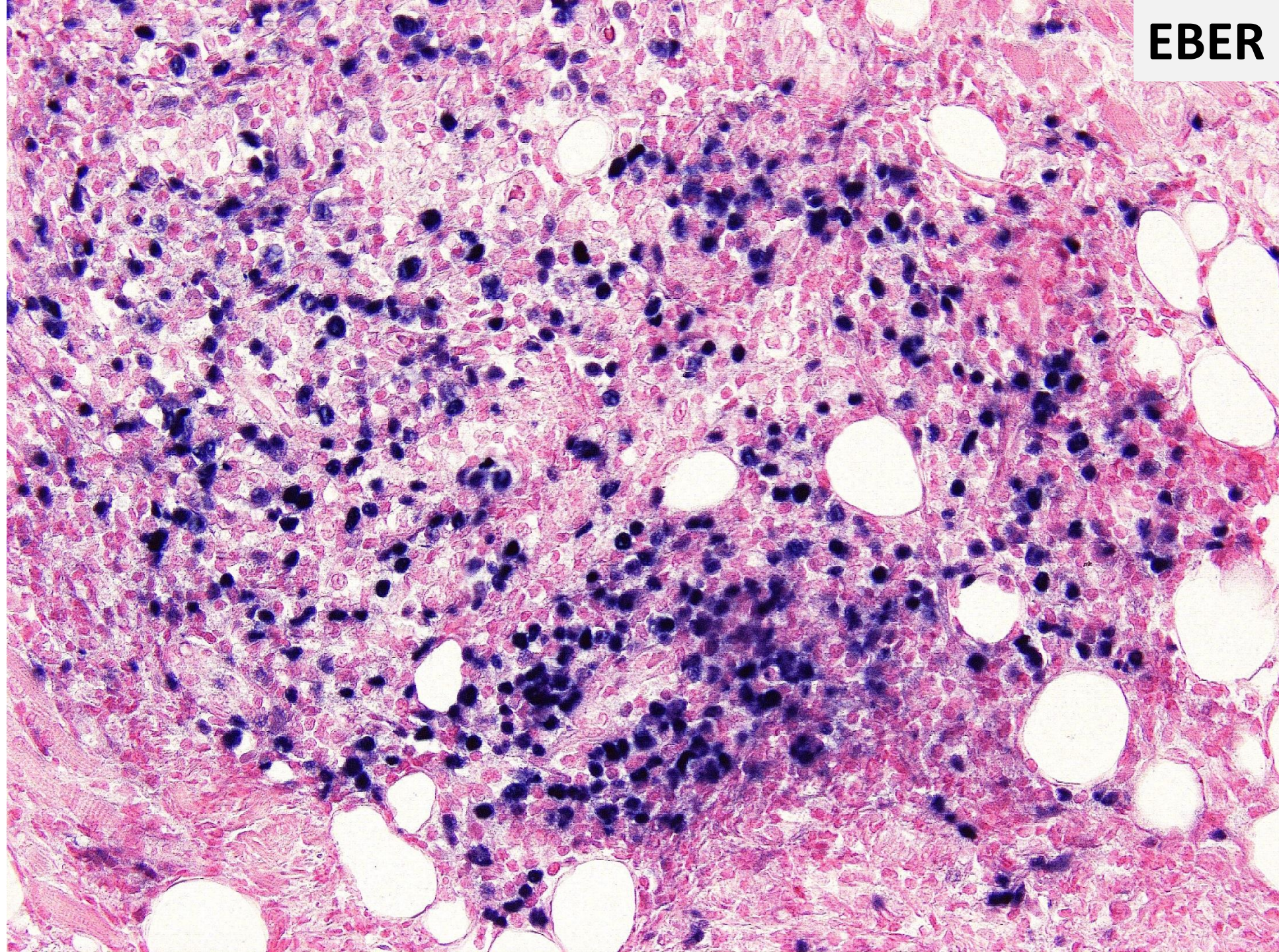
CD 30



MUM-1

**BCL-6 +
CD 10 -**

EBER



EXTRA IMMUNOHISTOCHEMICAL STAINS AND MOLECULAR BIOLOGY STUDIES

- Kappa and lambda light chains: non-contributory
- Background: T cells with normal phenotype
- IgH rearrangement: failed twice due to poor DNA quality

CASE 1

The main diagnosis to consider is:

- A. Herpetic infection associated with pseudolymphoma
- B. Lymphomatoid papulosis type C
- C. Methotrexate-Induced lymphoproliferative Disease
- D. EBV positive mucocutaneous ulcer
- E. EBV-related diffuse large B-cell lymphoma of the elderly

CASE 1

The main diagnosis to consider is:

- A. Herpetic infection associated with pseudolymphoma
- B. Lymphomatoid papulosis type C
- C. Methotrexate-induced lymphoproliferative disease**
- D. EBV positive mucocutaneous ulcer
- E. EBV-related diffuse large B-cell lymphoma of the elderly

74 years, female

1996 Rheumatoid arthritis

1999 Methotrexate (25mg)

2004 Leflunamide

August 2004

- Nausea, Vomiting, Lymphadenopathy
- Diarrhoea
- ?vasculitis
- Leflunamide stopped

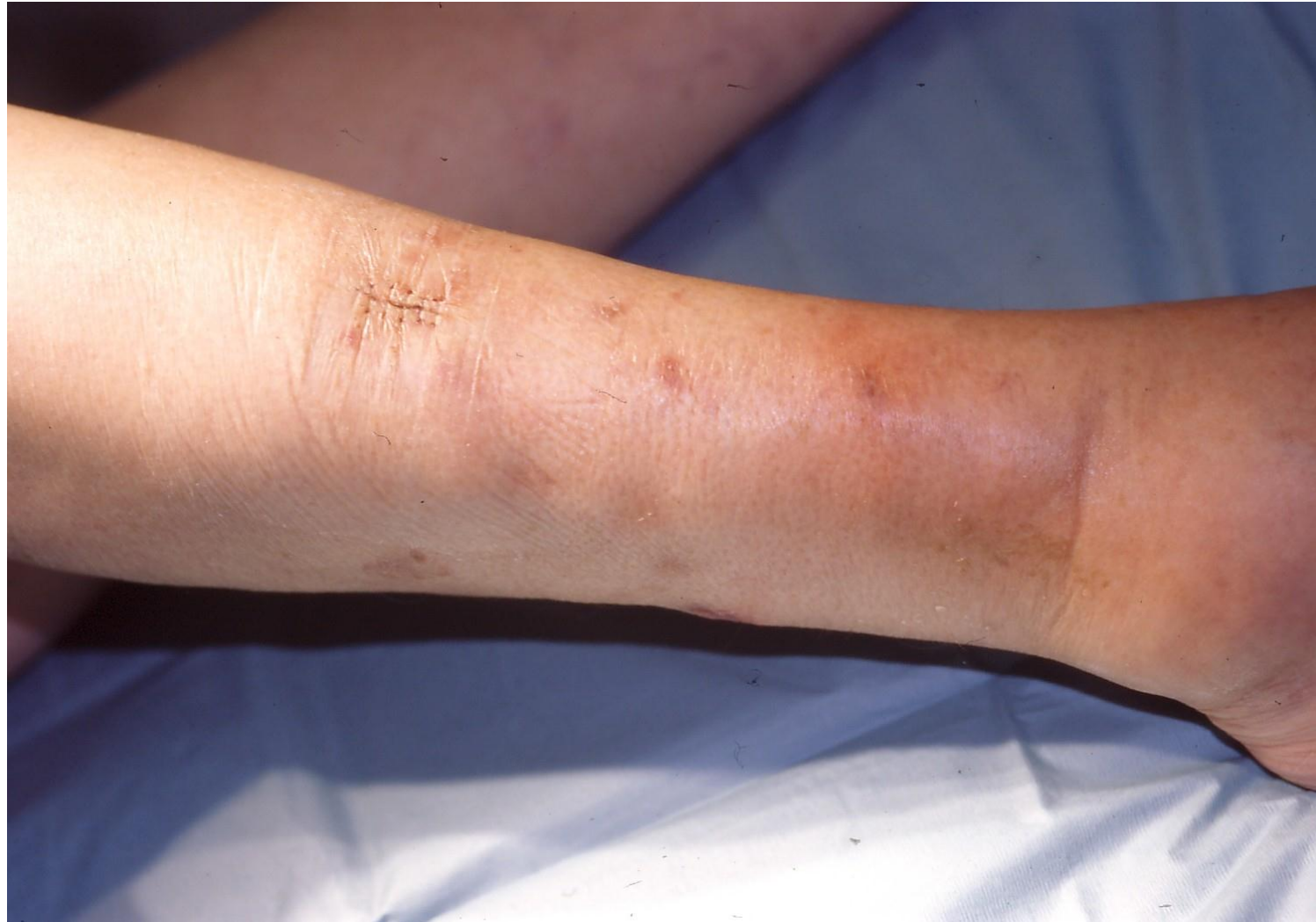Sept 2004

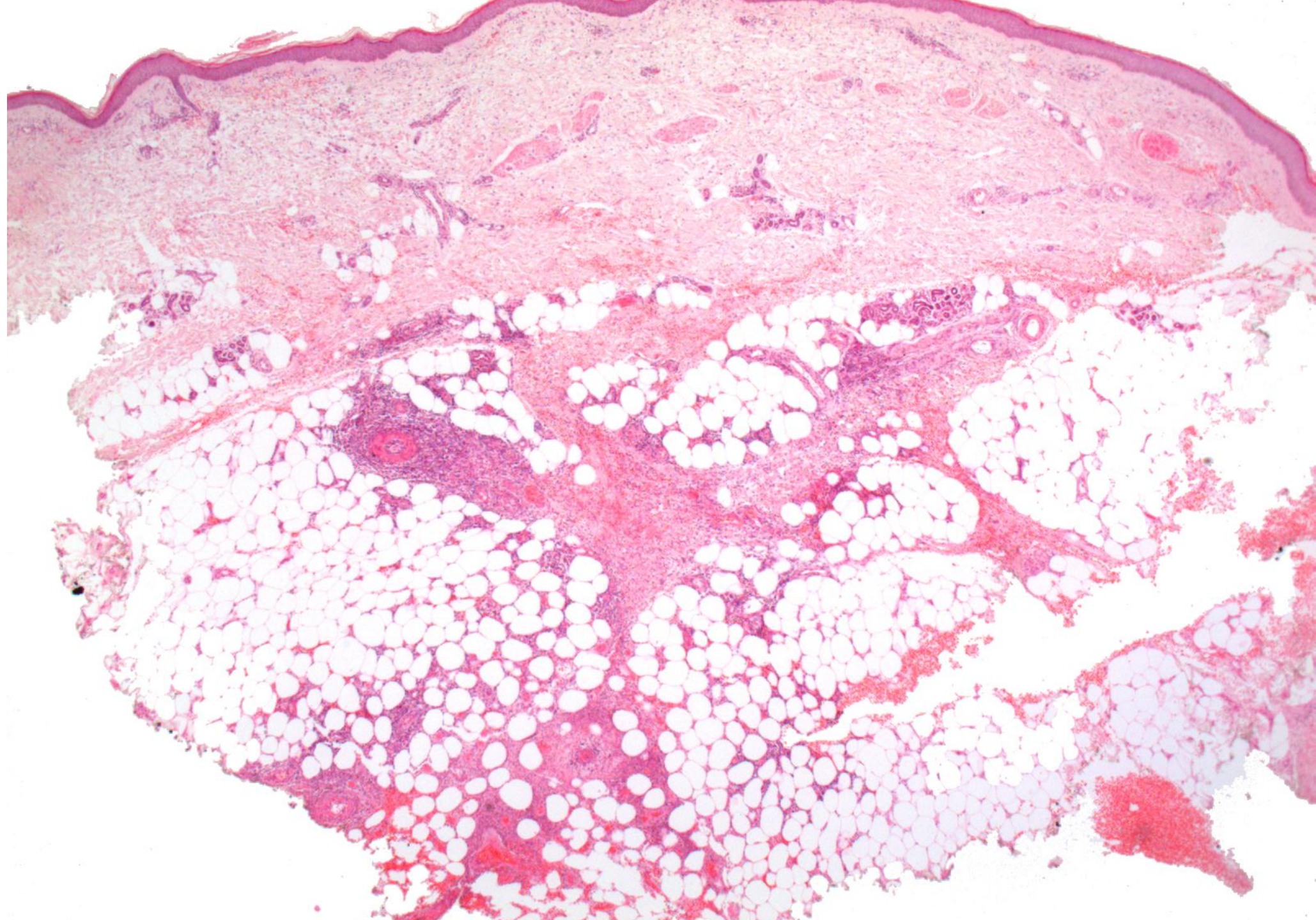
- Diffuse swelling right ankle
 - ?Lipodermatosclerosis
- Compression stockings

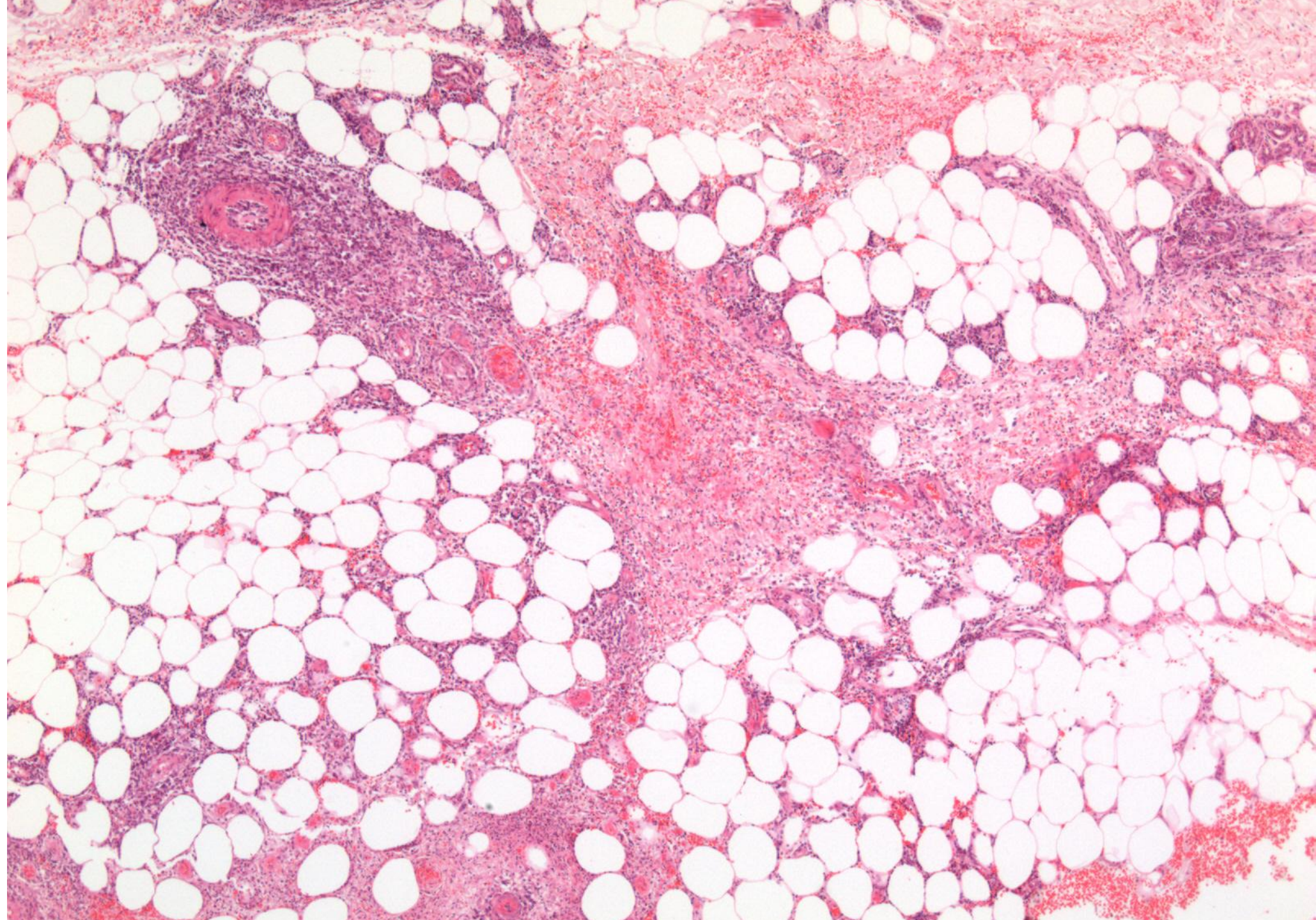
November 2005

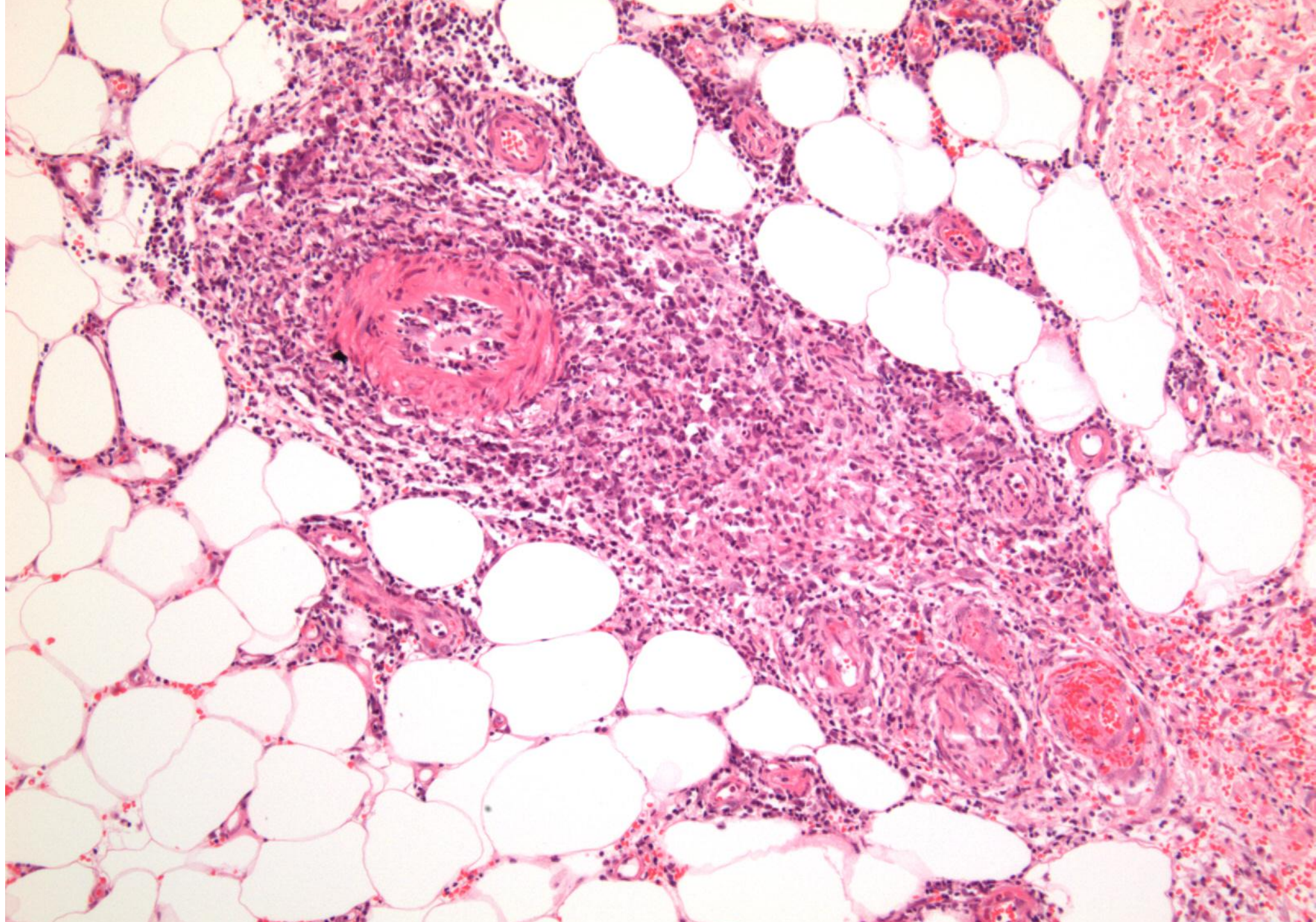
- Discrete nodules on legs
- Skin biopsy

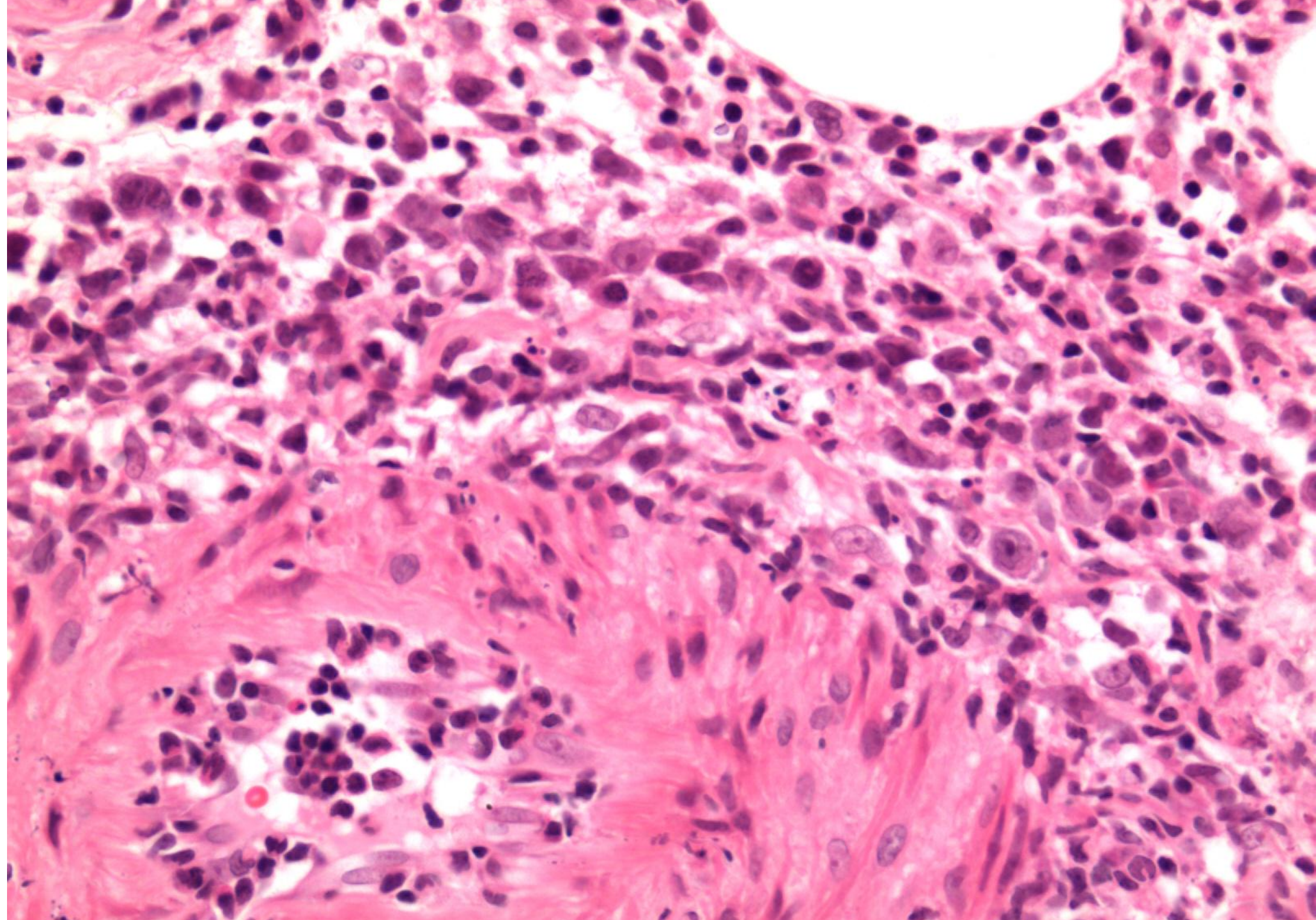
Nov 05 - Erythematous nodule on right shin

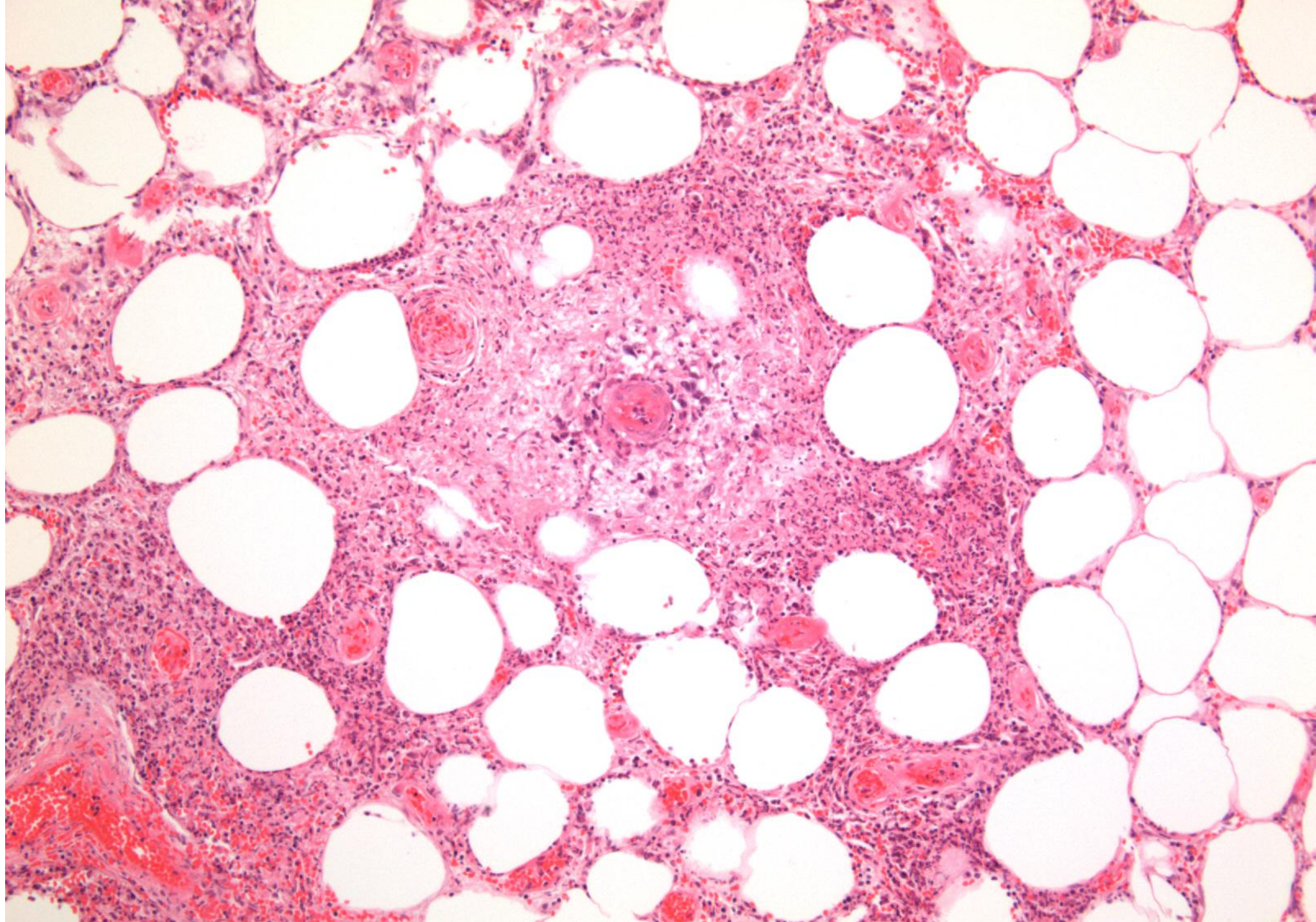


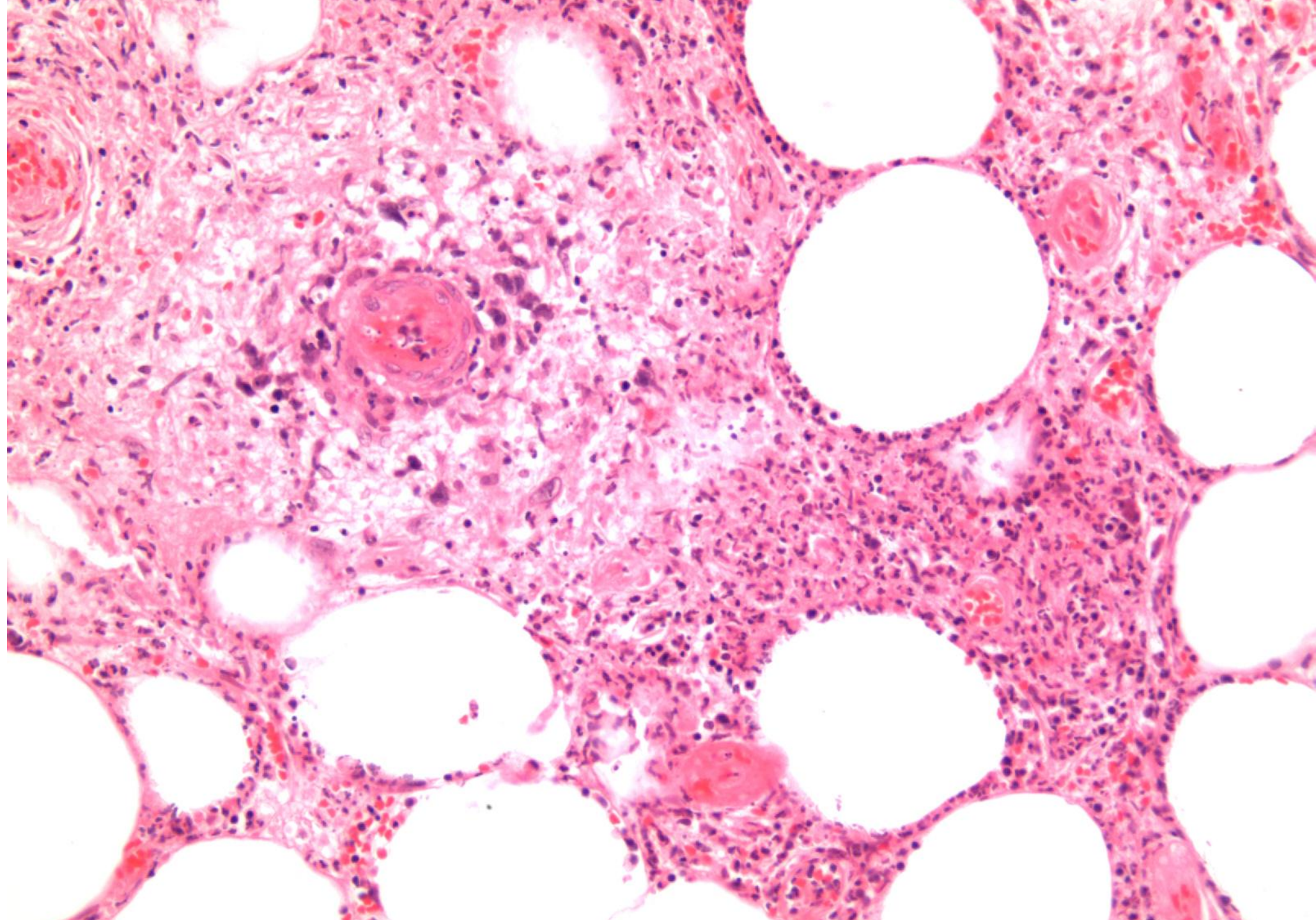


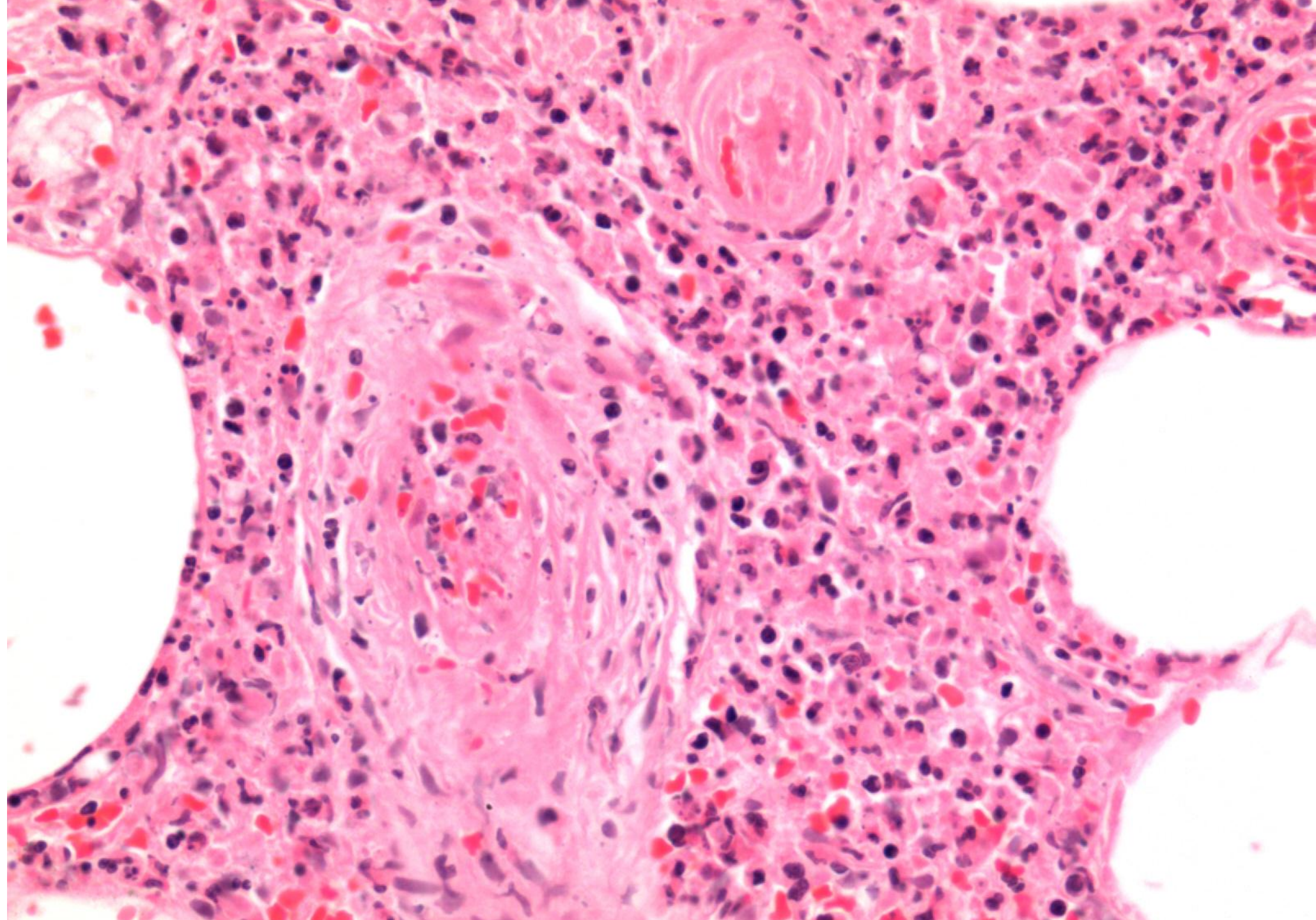


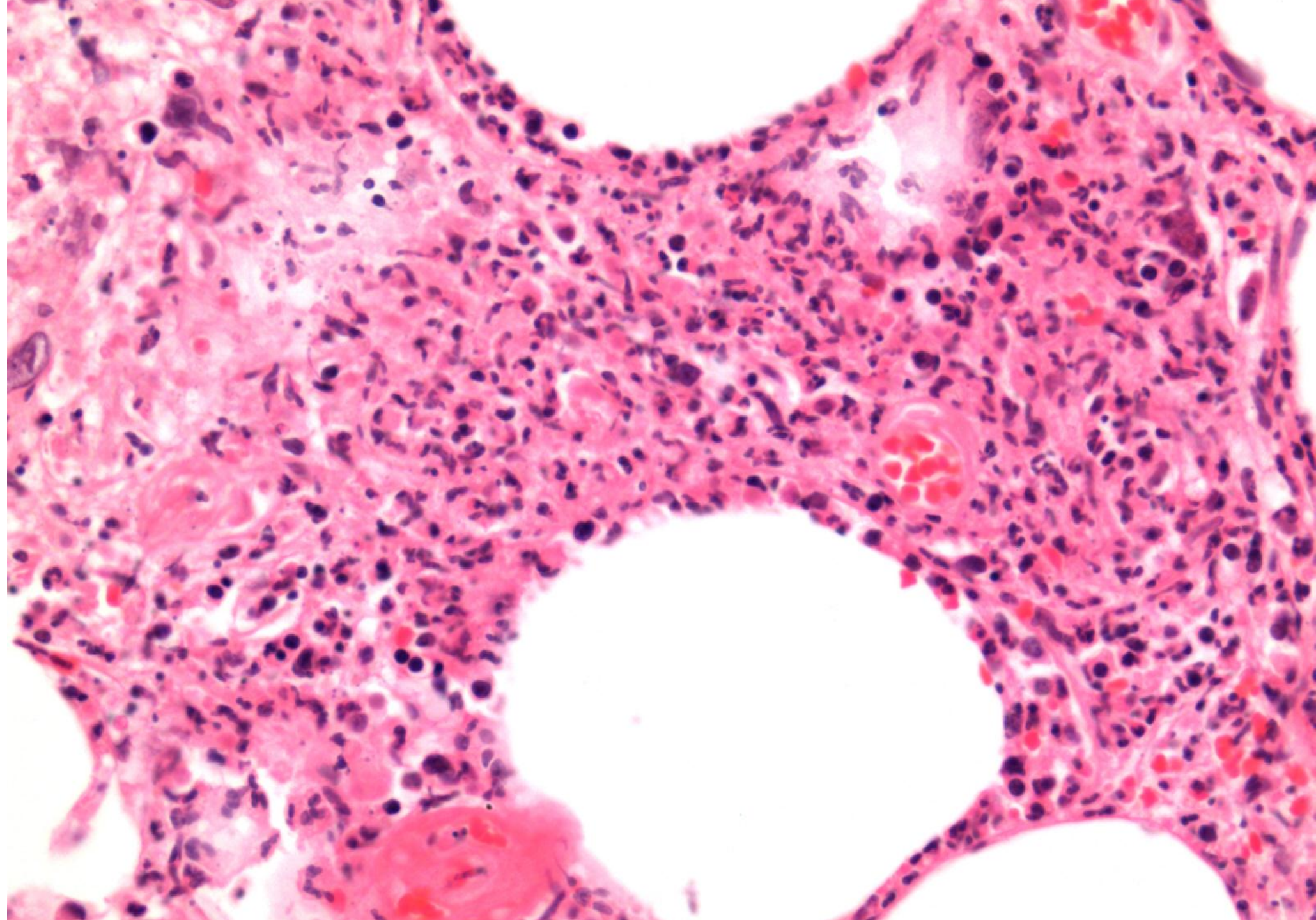


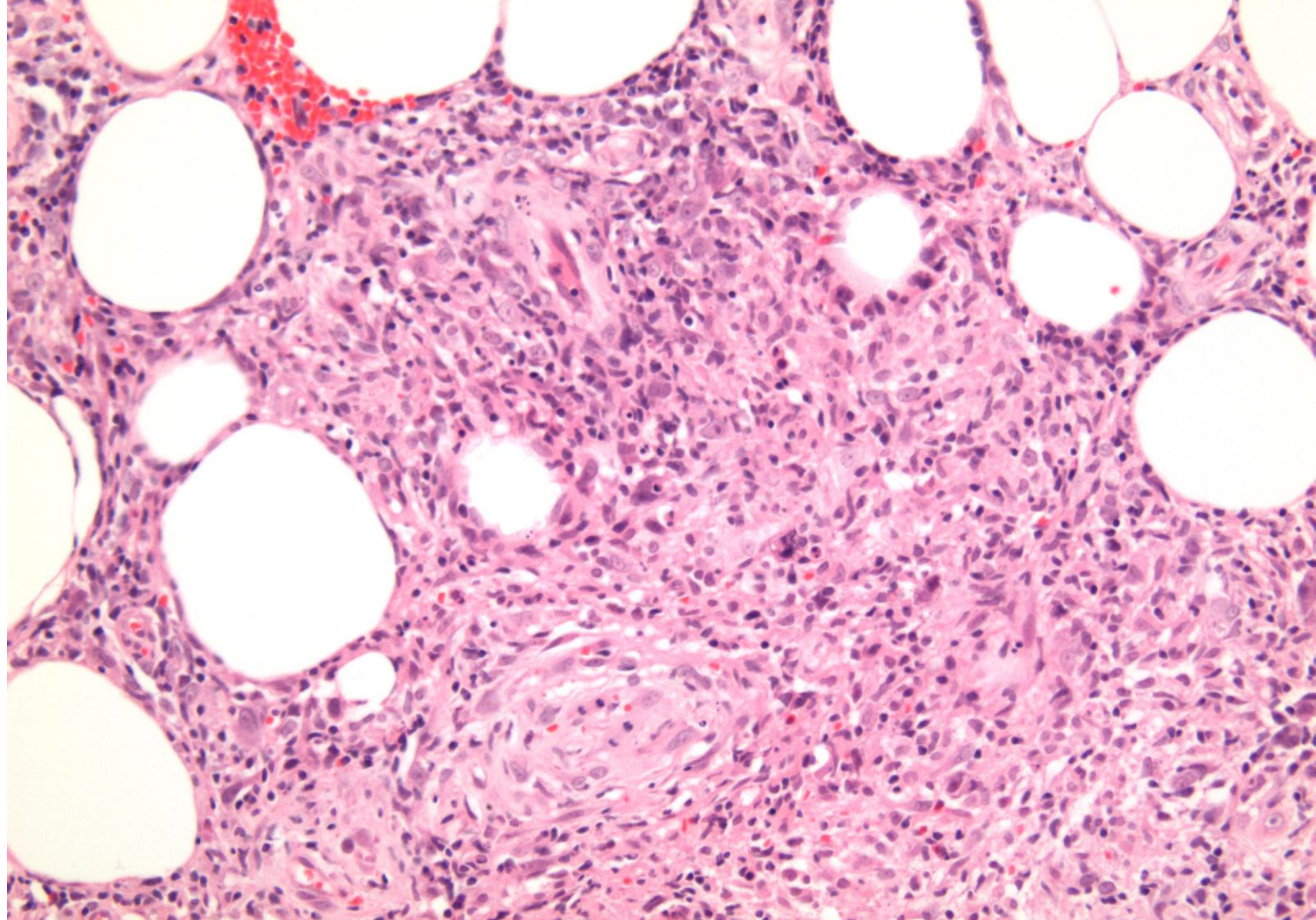


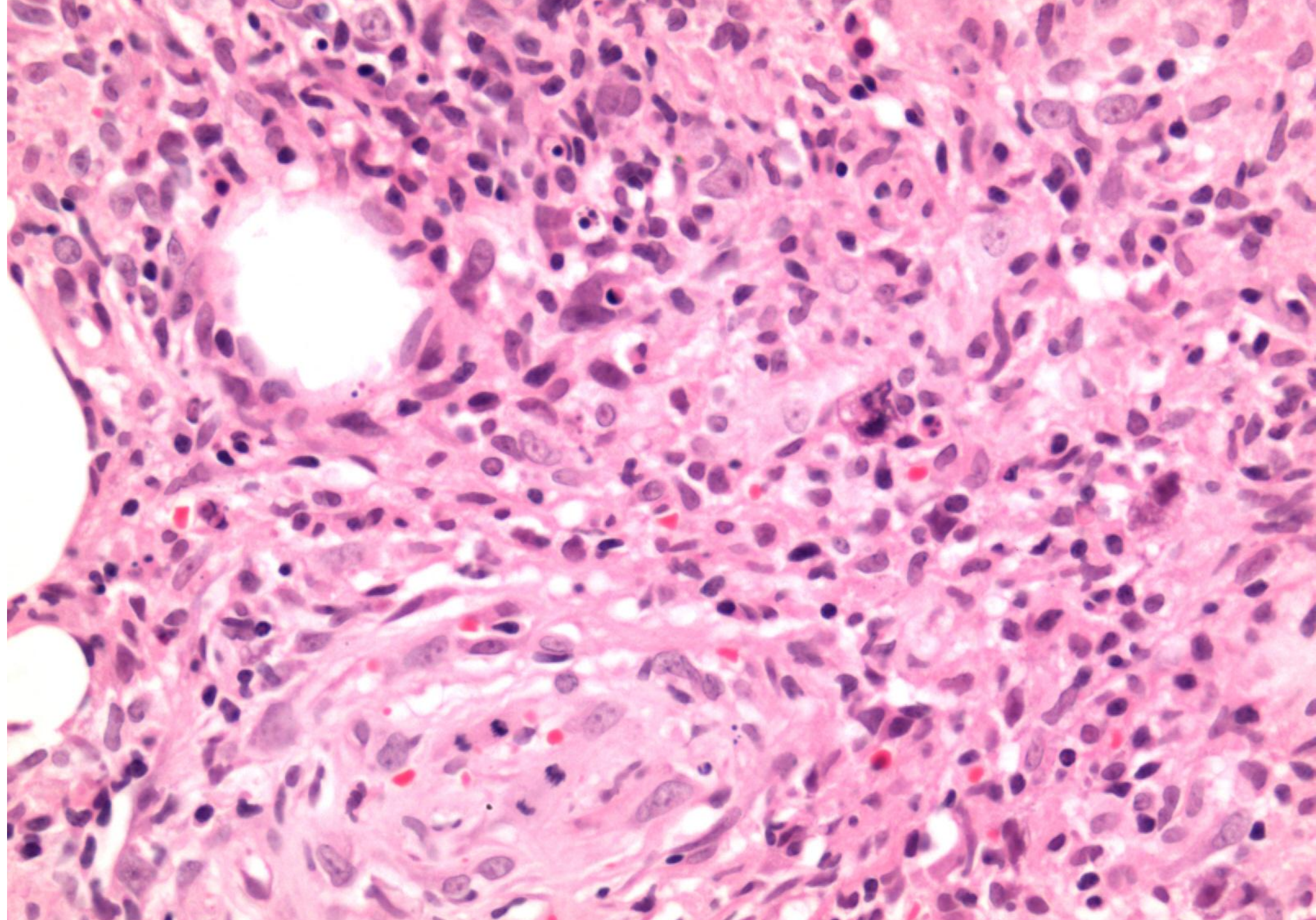


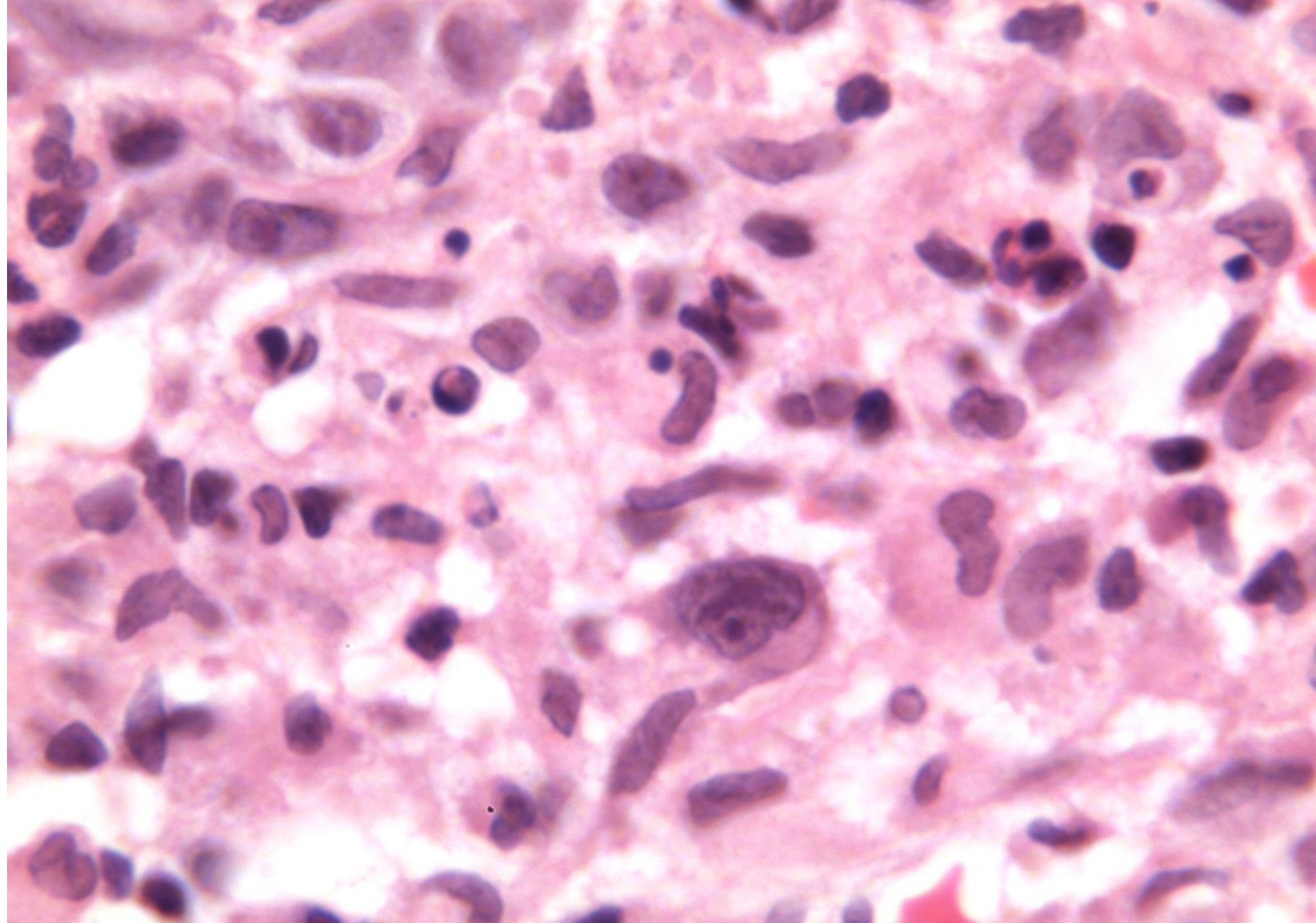


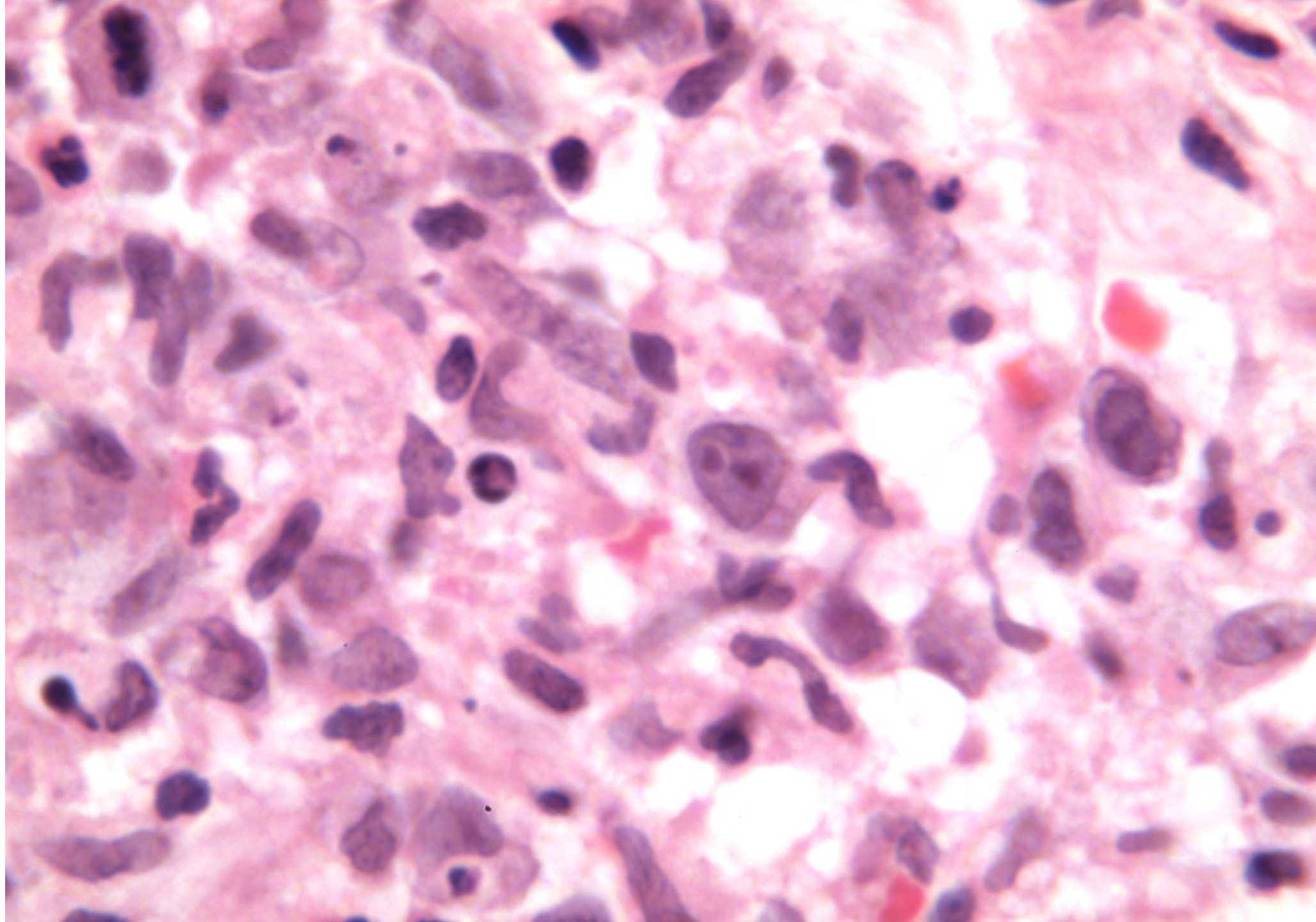


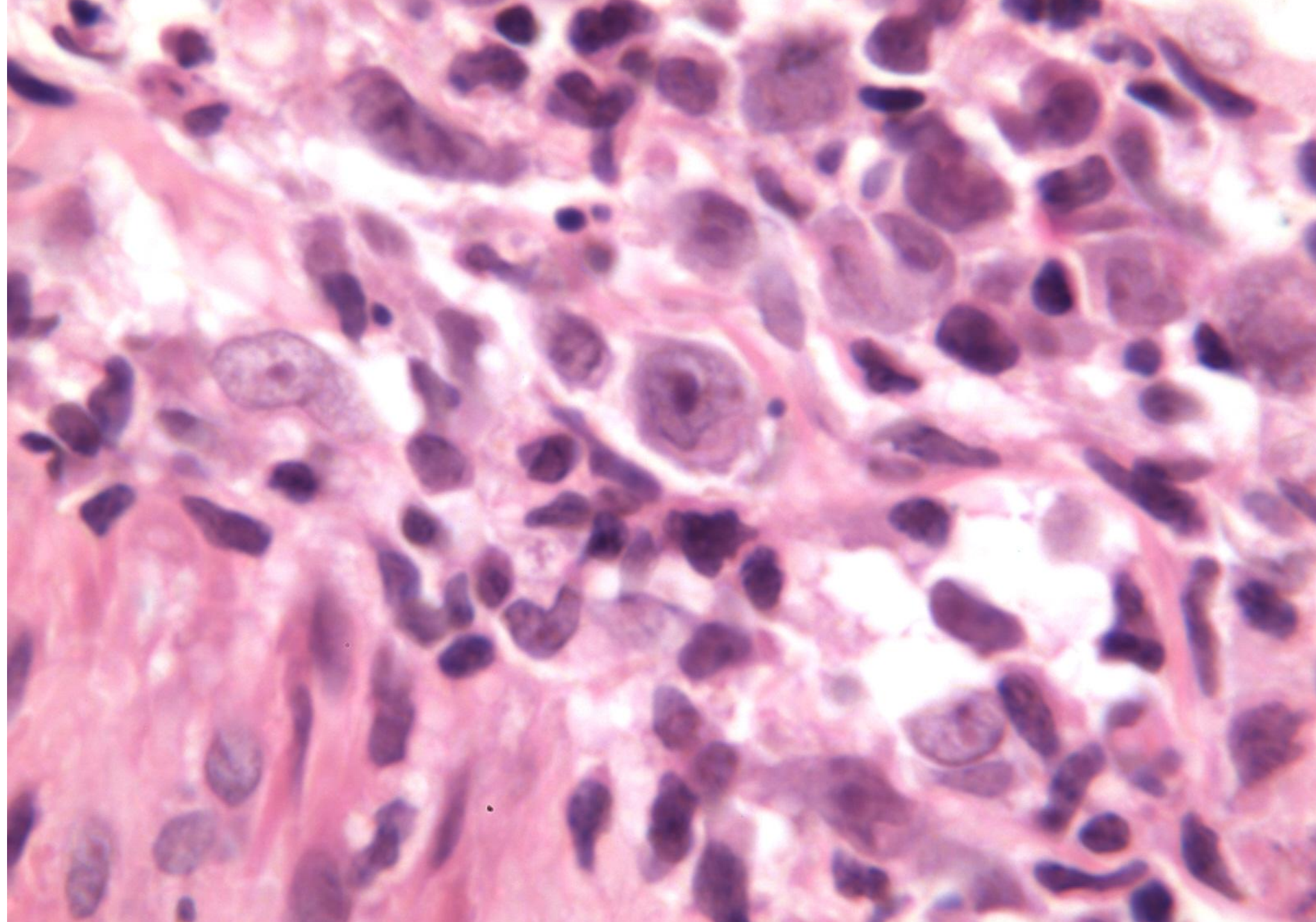




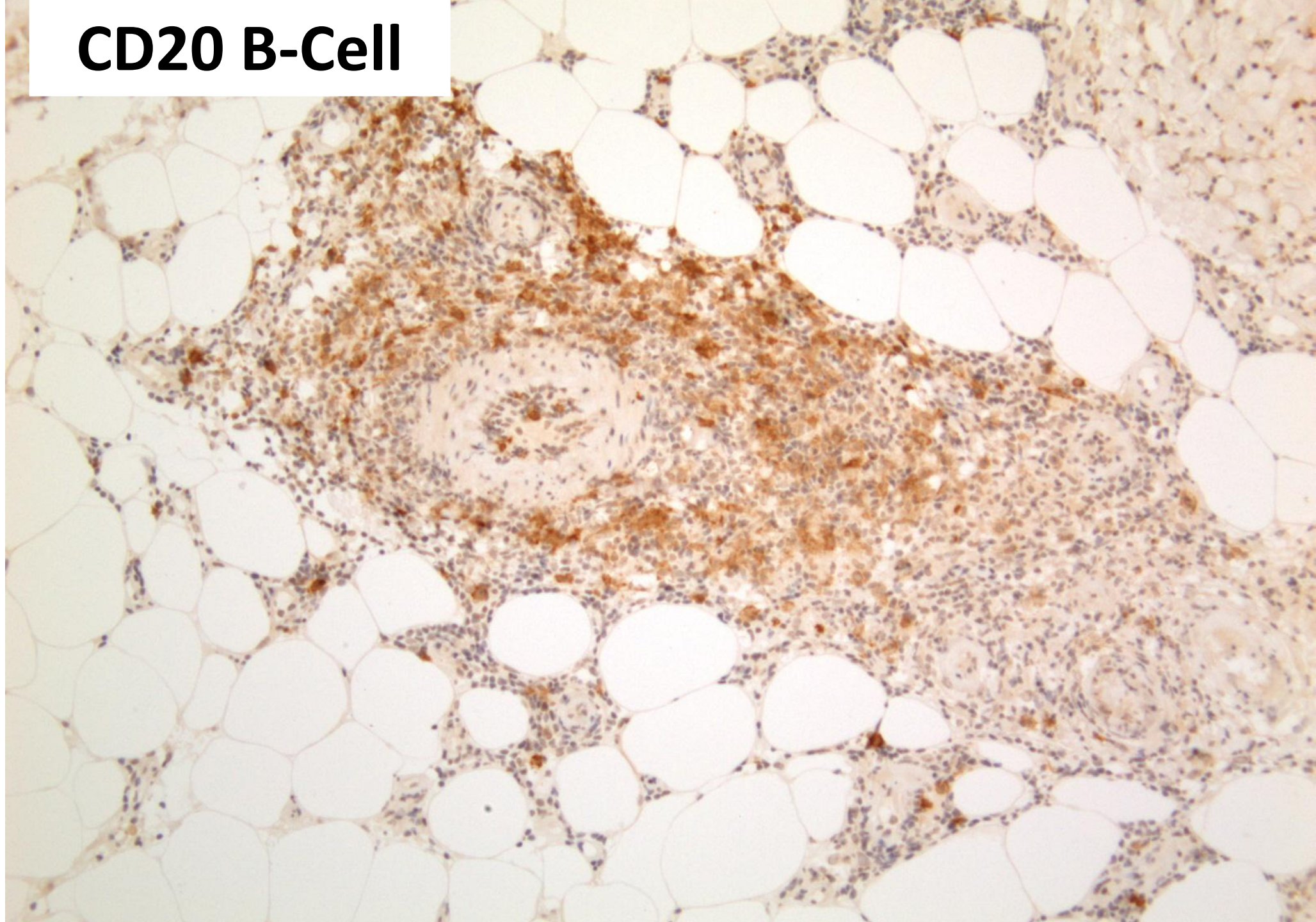




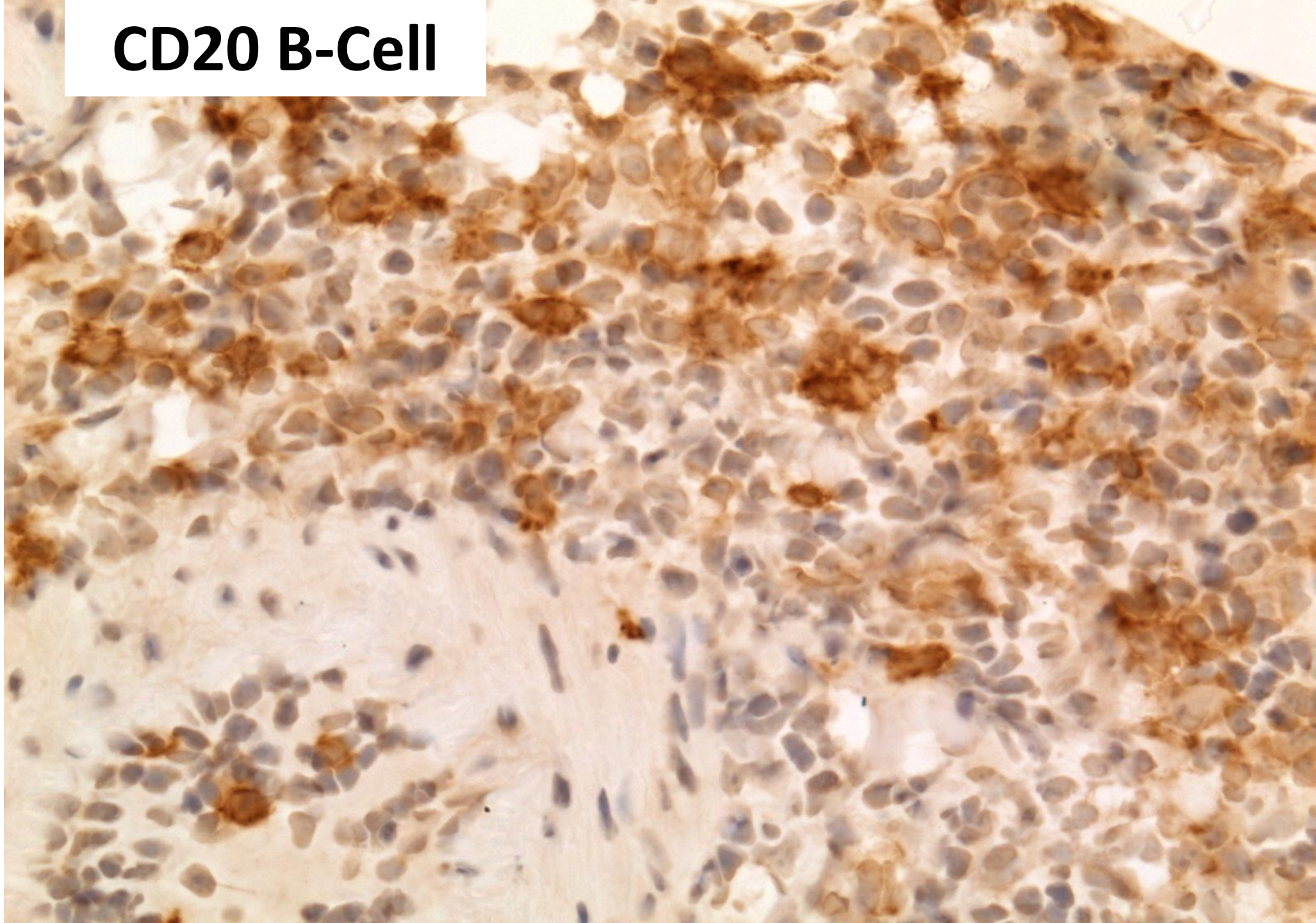




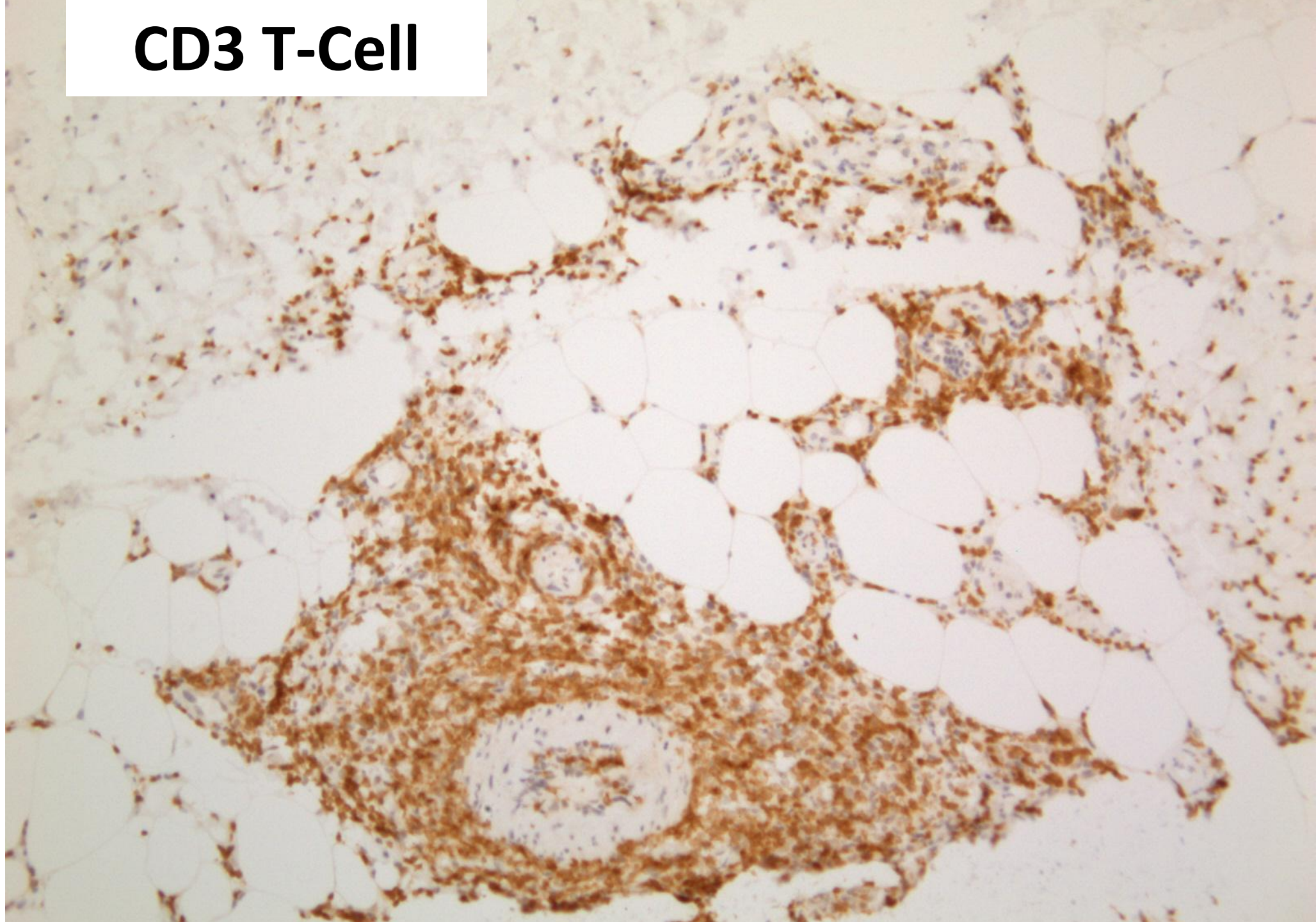
CD20 B-Cell



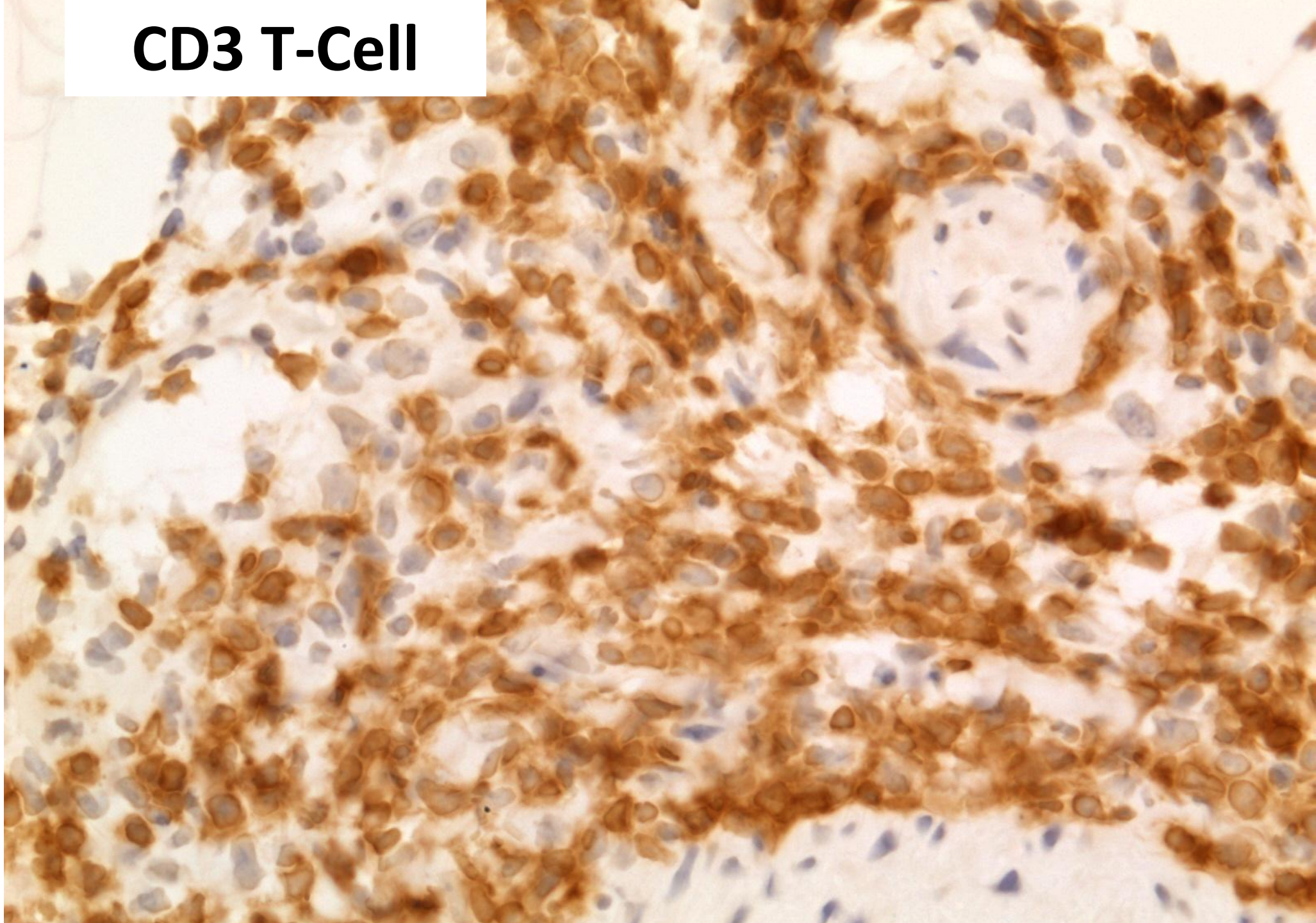
CD20 B-Cell



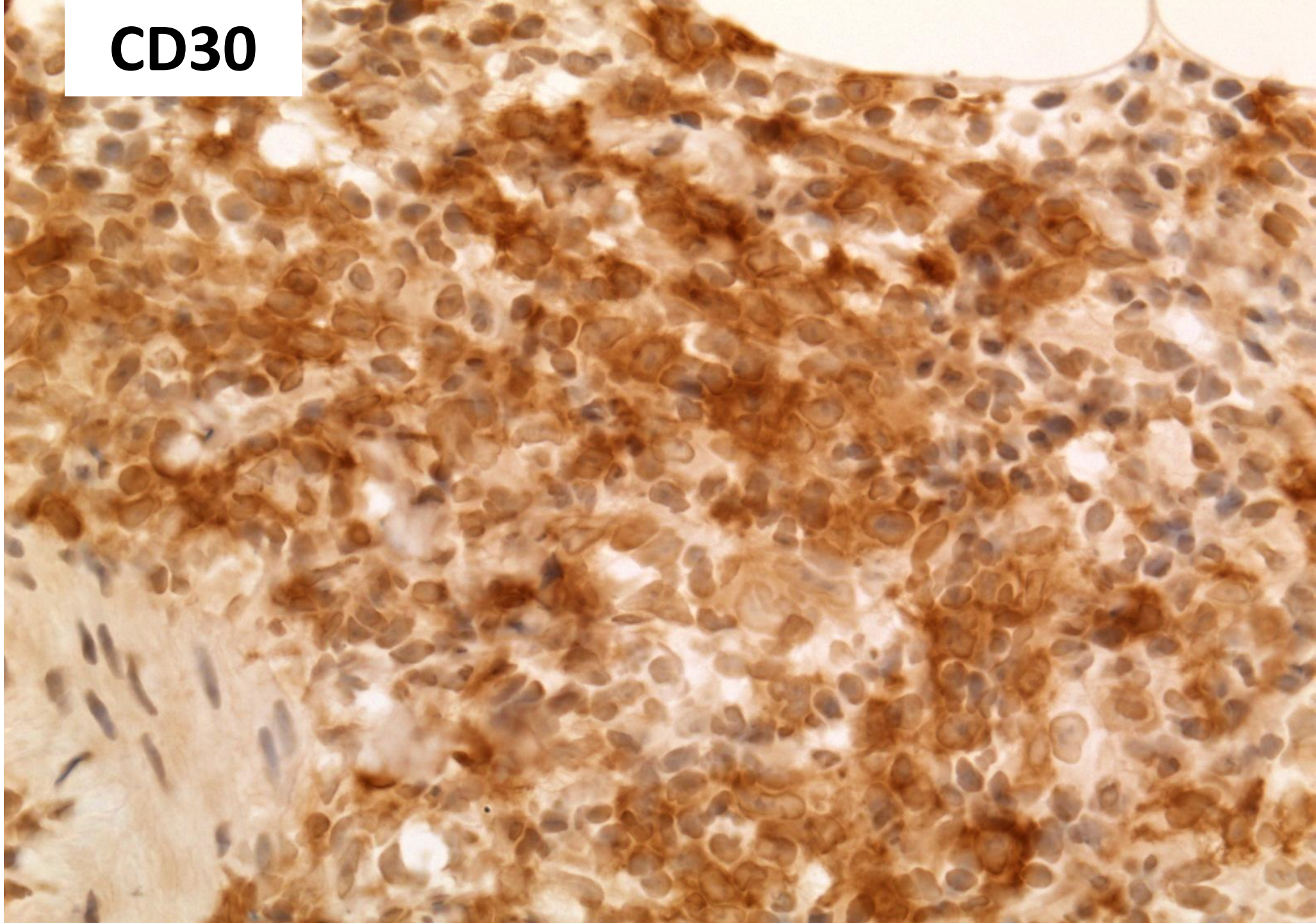
CD3 T-Cell



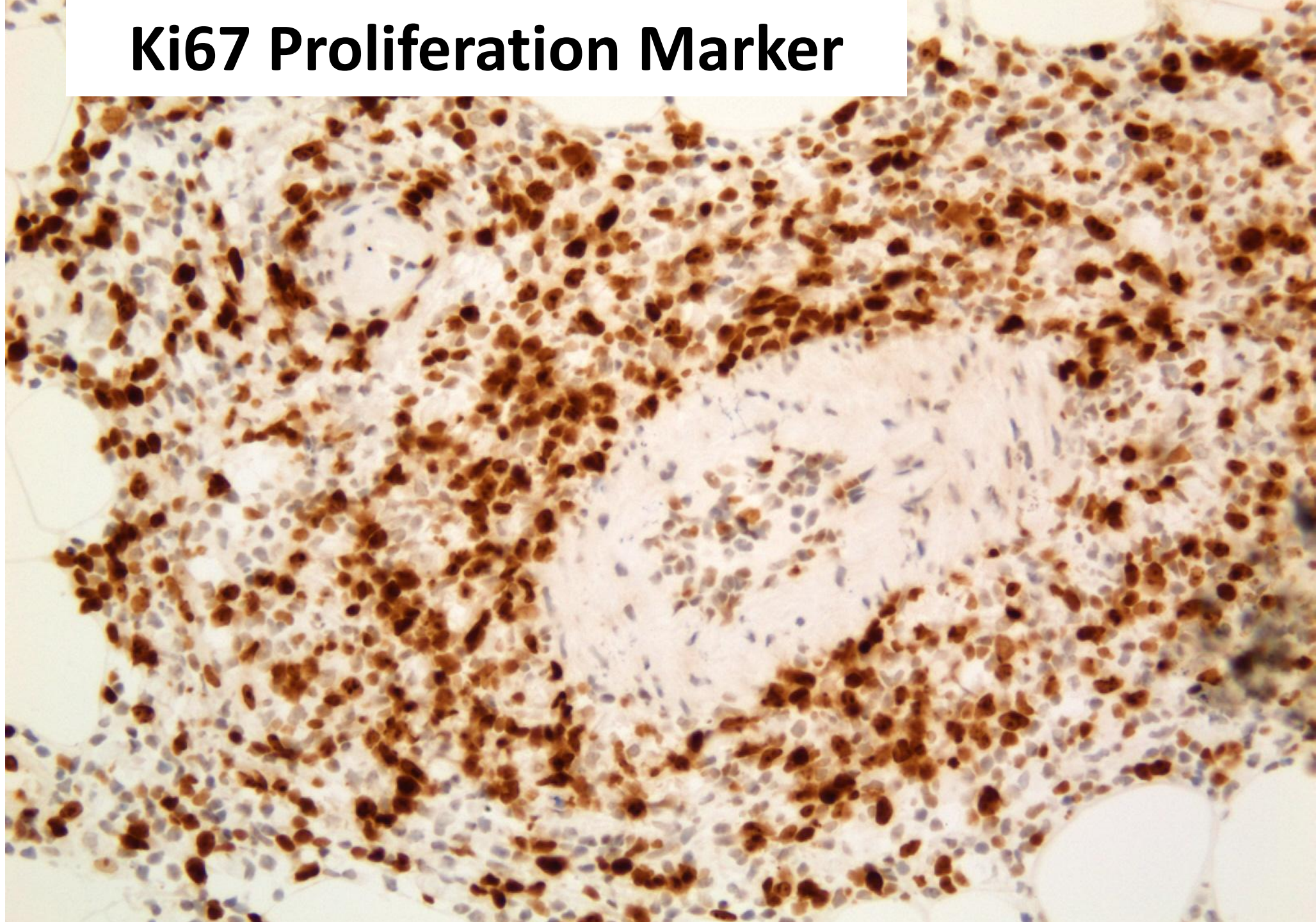
CD3 T-Cell



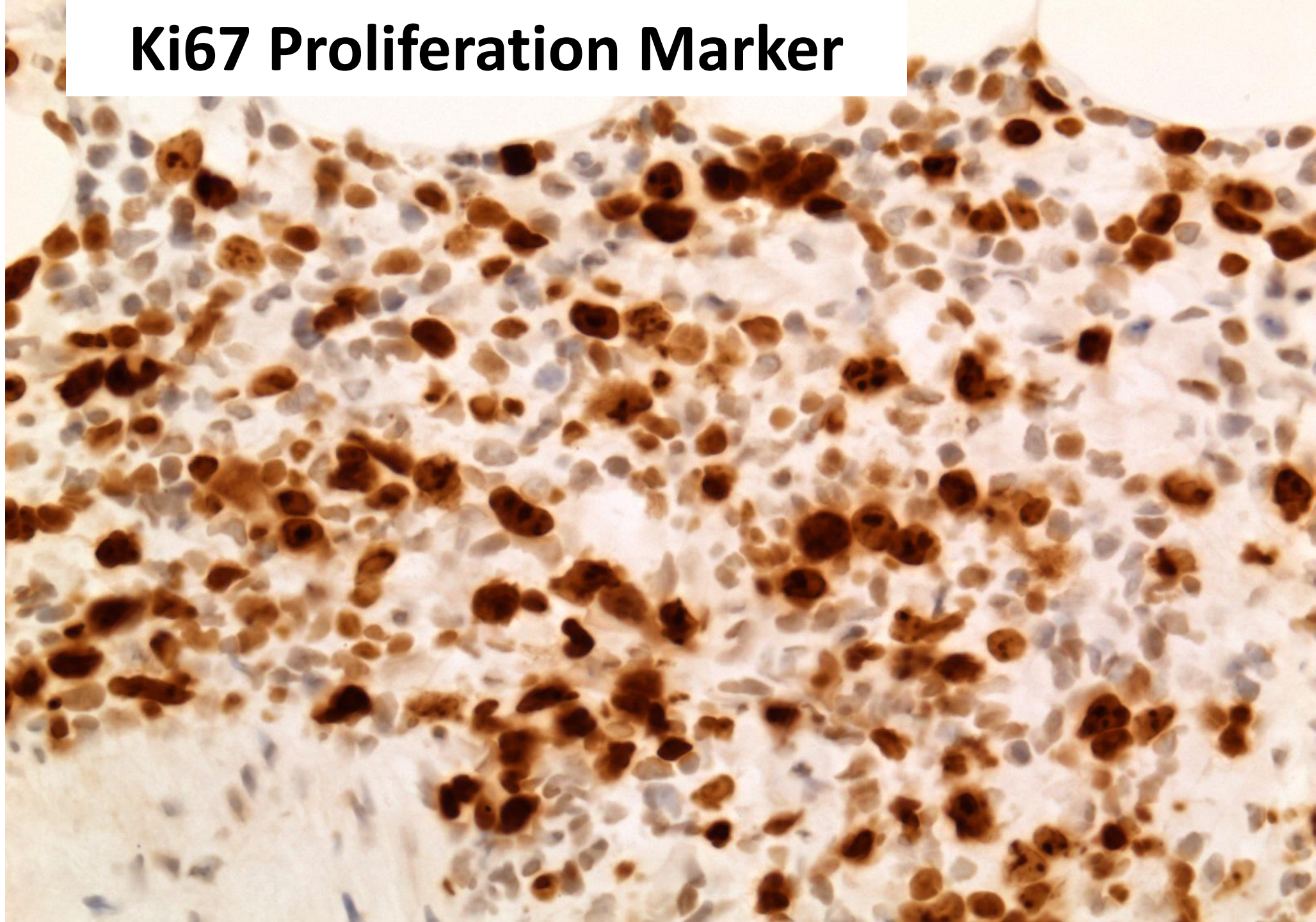
CD30

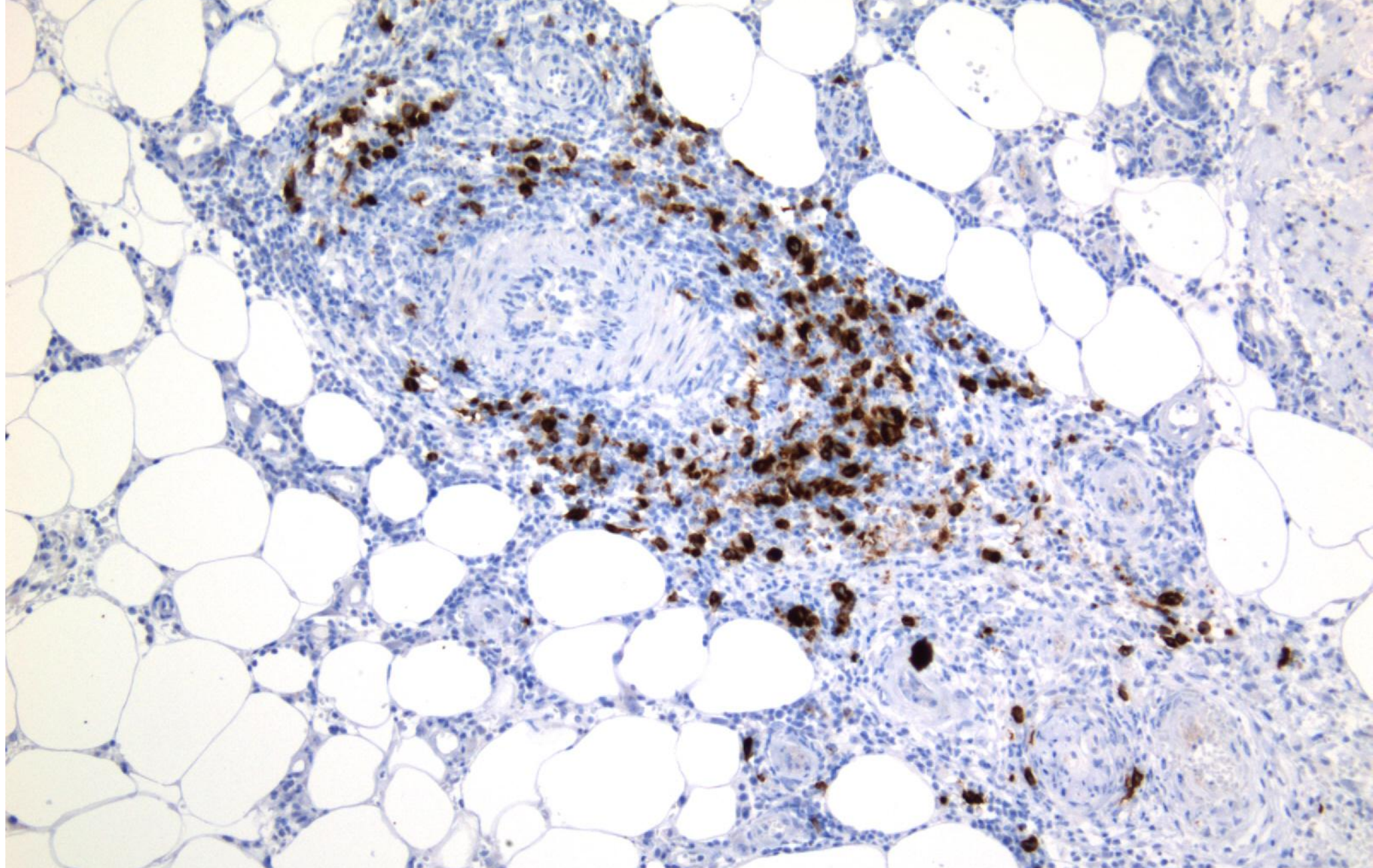


Ki67 Proliferation Marker



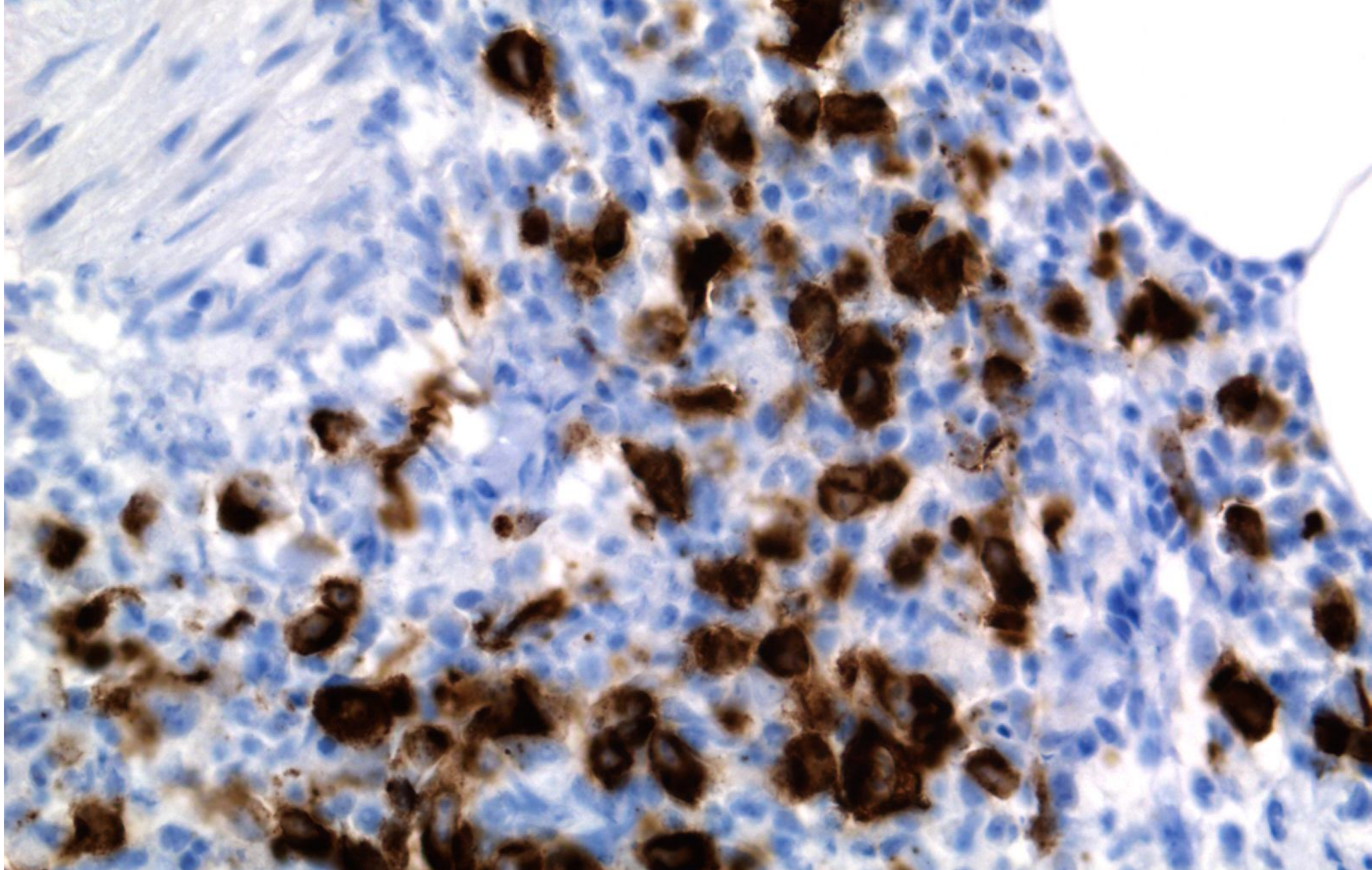
Ki67 Proliferation Marker

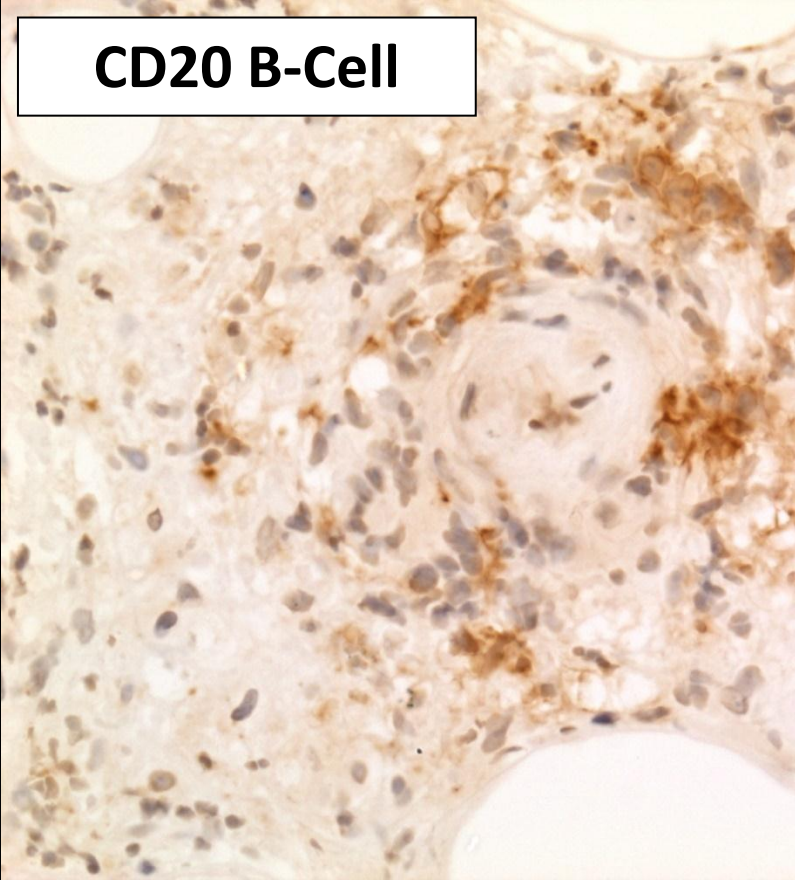
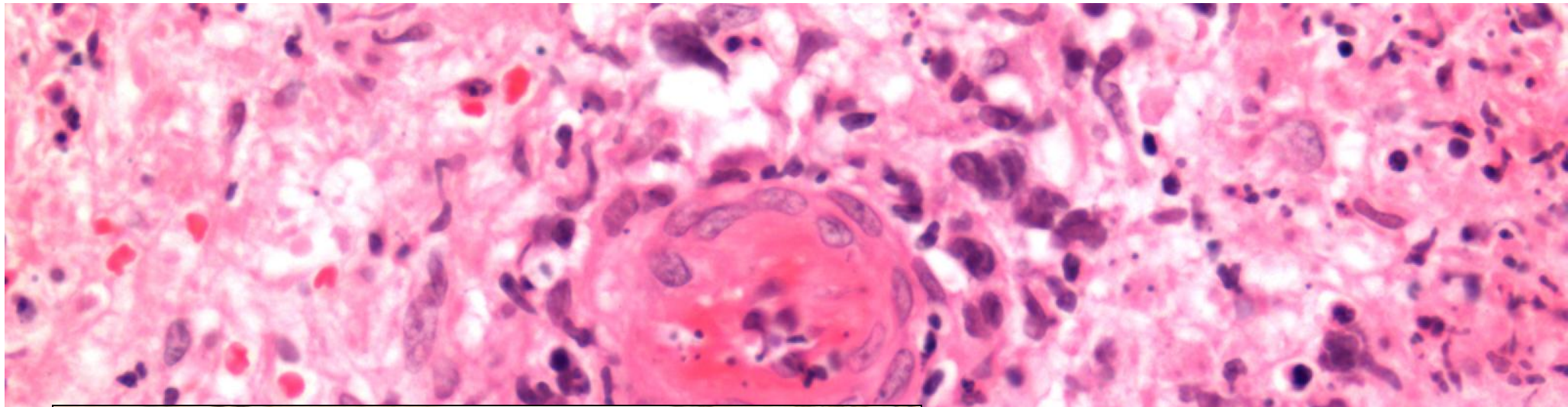




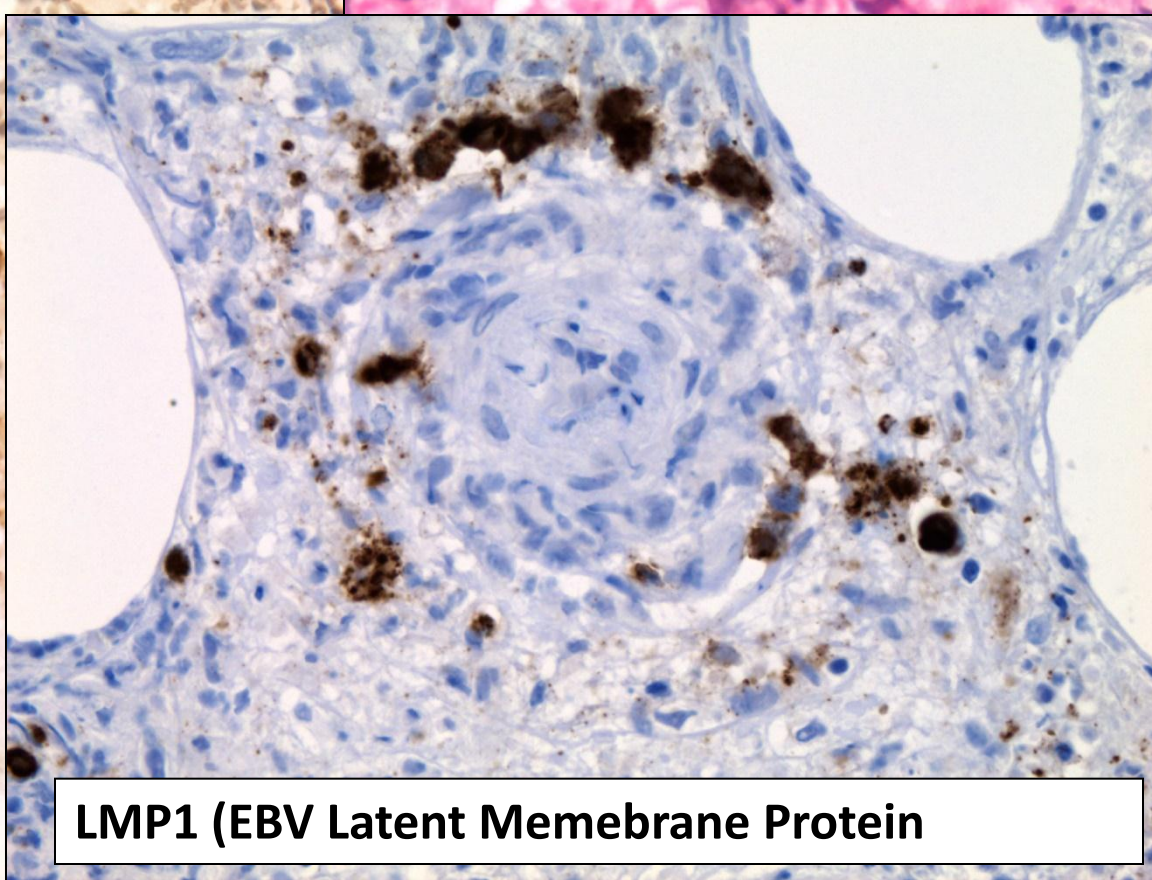
LMP1 (EBV Latent Membrane Protein)

LMP1 (EBV Latent Membrane





CD20 B-Cell



LMP1 (EBV Latent Membrane Protein)

Methotrexate-associated B-cell Lymphoproliferative Disorders Presenting in the Skin: A Clinicopathologic and Immunophenotypical Study of 10 Cases.

[Koens L](#)¹, [Senff NJ](#), [Vermeer MH](#), [Willemze R](#), [Jansen PM](#).

Author information

•¹Departments of *Pathology †Dermatology, Leiden University Medical Center, Leiden ‡Department of Dermatology, Saint Lucas Andreas Hospital, Amsterdam, The Netherlands.

Abstract

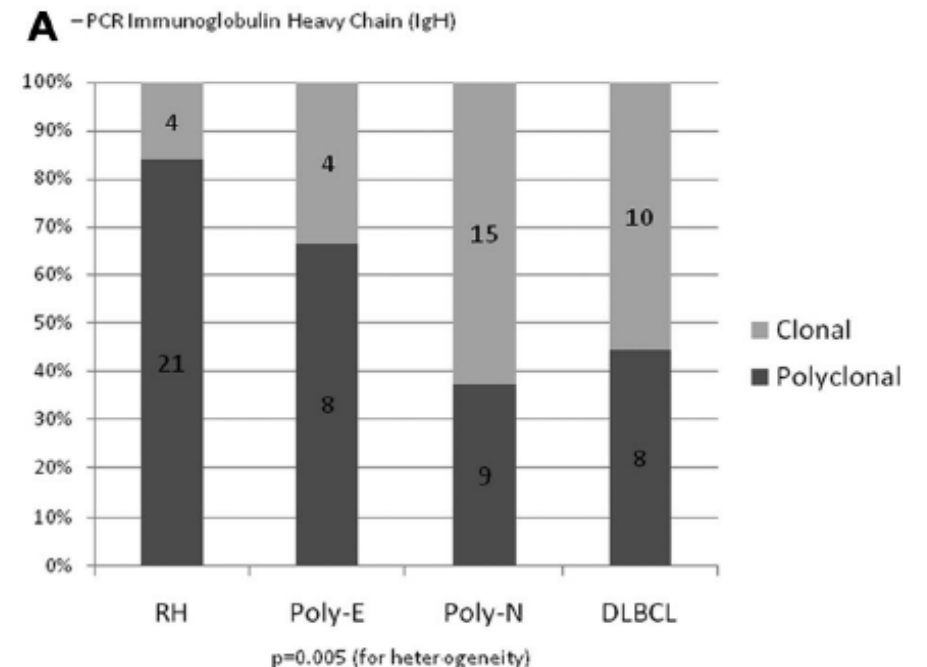
Methotrexate (MTX)-associated B-cell lymphoproliferative disorders (B-LPD) may first present in the skin, but their clinicopathologic features are still ill defined. Differentiation from primary cutaneous follicle center lymphoma and primary cutaneous diffuse large B-cell lymphoma, leg type (PCLBCL-LT) is important, as MTX-associated B-LPD may show spontaneous regression after withdrawal of MTX therapy. In the present study, the clinicopathologic and phenotypical features of 10 patients with MTX-associated B-LPD first presenting in the skin, including 5 EBV and 5 EBV cases, were investigated. Six patients had skin-limited disease. Clinically, abrogation of MTX therapy resulted in a complete response in 4 cases and a partial response in another 2. The 5-year disease-specific survival was 90%. MTX-associated B-LPD differed from primary cutaneous follicle center lymphoma by the presence of ulcerating and/or generalized skin lesions, an infiltrate composed of centroblasts/immunoblasts rather than large centrocytes, reduced staining for CD79a, and expression of BCL2, IRF4, and FOXP1 in most cases. EBV MTX-associated B-LPD differed from PCLBCL-LT by the presence ulcerative skin lesions, marked tumor cell polymorphism, reduced staining for CD79a, and expression of CD30 and EBV. EBV cases showed morphologic and immunophenotypical similarities to PCLBCL-LT but differed by presentation with generalized skin lesions in 4 of 5 cases. The results of this study, showing a relatively good clinical outcome and spontaneous disease regression after only withdrawal of MTX in a considerable proportion of patients, underscores the importance of a careful wait-and-see policy before considering more aggressive therapies in patients with MTX-associated B-LPD of the skin

EBV-positive B cell lymphoproliferative disorder (EBV-LPD)

- EBV-associated reactive lymphoid hyperplasia (RH)
- EBV-positive mucocutaneous ulcer/ EBV-associated extranodal polymorphic lymphoproliferative disease
- EBV-positive diffuse large B-cell lymphoma of the elderly
- **Other iatrogenic immunodeficiency-associated lymphoproliferative disorders**

Classification of EBV-LPDs

- Is not always straightforward
- Distinction between reactive lesions and lymphoma can be very difficult and is often imprecise
- Most cases diagnosed as RH lacked *IG* rearrangements
- The identification of a clonal B-cell population favours a more aggressive process



(Blood. 2011;117(18):4726-4735)

EBV Positive Mucocutaneous Ulcer—A Study of 26 Cases Associated With Various Sources of Immunosuppression

Stefan D. Dojcinov, MD, FRCPath, Girish Venkataraman, MD,†
Mark Raffeld, MD,† Stefania Pittaluga, MD, PhD,† and Elaine S. Jaffe, MD†*

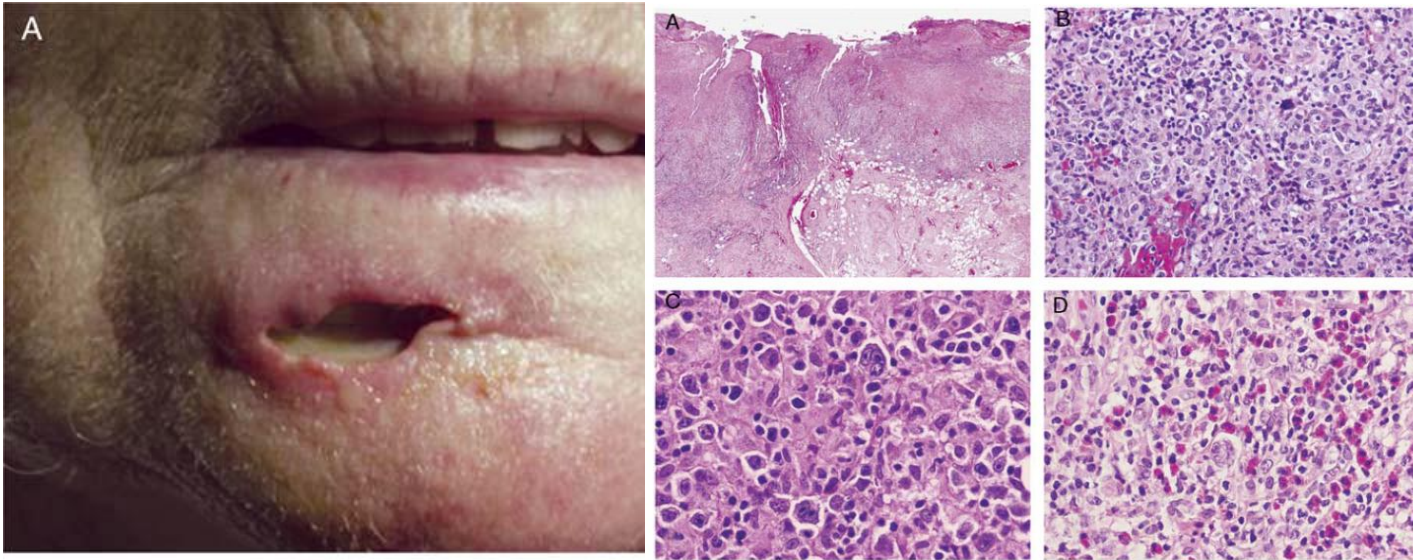


TABLE 3. Summary of Histological Features

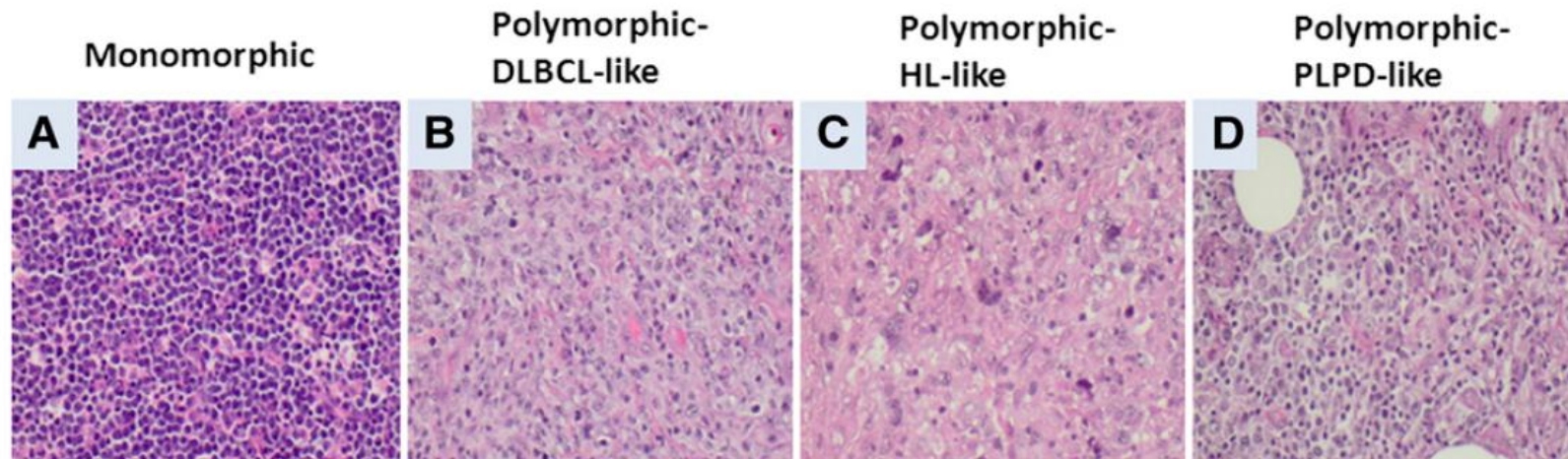
Dominant histological features*	
Well-circumscribed ulcer	
Polymorphous background infiltrate	
Reed-Sternberg and Hodgkin-like cells	
Numerous medium size T-cells	
Plasmacytoid apoptotic bodies	
Additional prominent histological features	CD20+/-, EBER +
Plasma cells	% of cases 31
Histiocytes	19
Eosinophils	8
Angioinvasion	23
Necrosis	23

*Features present in all cases.

(Am J Surg Pathol 2010;34:405–417)

EBV positive diffuse large B-cell lymphoma of the elderly

- Histologically malignant polymorphic or monomorphic EBV-positive B-cell lymphoproliferation
- Patients generally over the age of 50 without any known immunodeficiency, transplantation or prior lymphoma
- Frequent extranodal presentation (e.g stomach, lung, tonsils and skin)
- Overall poor prognosis



Other iatrogenic immunodeficiency-associated LPD

- WHO classification: MTX-LPD is categorized as other iatrogenic immunodeficiency-associated LPD, which is similar to immunodeficiency-associated LPD such as post-transplant LPD and human immunodeficiency virus (HIV)-associated LPD
- The lymphoproliferative disorders in patients with history of MTX therapy are best characterized in cohorts of patients with rheumatoid arthritis
- B-cell proliferations predominate and consist of DLBCL in the majority of the cases (up to 60%)

METHOTREXATE-INDUCED LYMPHOPROLIFERATIVE DISEASE

- Usually but not always EBV-positive
- EBV-positive cases can be confused with a primary cutaneous diffuse large B cell lymphoma leg-type. The latter however, is EBV and CD30 negative, shows decrease CD79a expression and displays less pleomorphism
- EBV-negative cases can be confused with primary cutaneous follicle centre B cell lymphoma. The former presents with more generalized and ulcerated lesions and it is composed mainly of centroblasts and immunoblasts with decrease expression of CD79a and positivity for BCL2, IRF4 and FOXP1
- Good prognosis and regression possible after stopping methotrexate

In RA patients treated with MTX, EBV is expected to be activated by three mechanisms

- (i) The first mechanism of activation involves RA itself. Recently, it was revealed that patients with RA have a genetic deficiency of CD8+ cytotoxic T cells and consequently an elevated EBV load because of immunodeficiency
- (ii) The second mechanism is suppression of T-cell activation and T-cell adhesion molecule expression by MTX
- (iii) The third mechanism is direct reactivation of latent EBV by MTX. MTX activates the release of infectious EBV from latently infected cells

CONCLUSIONS

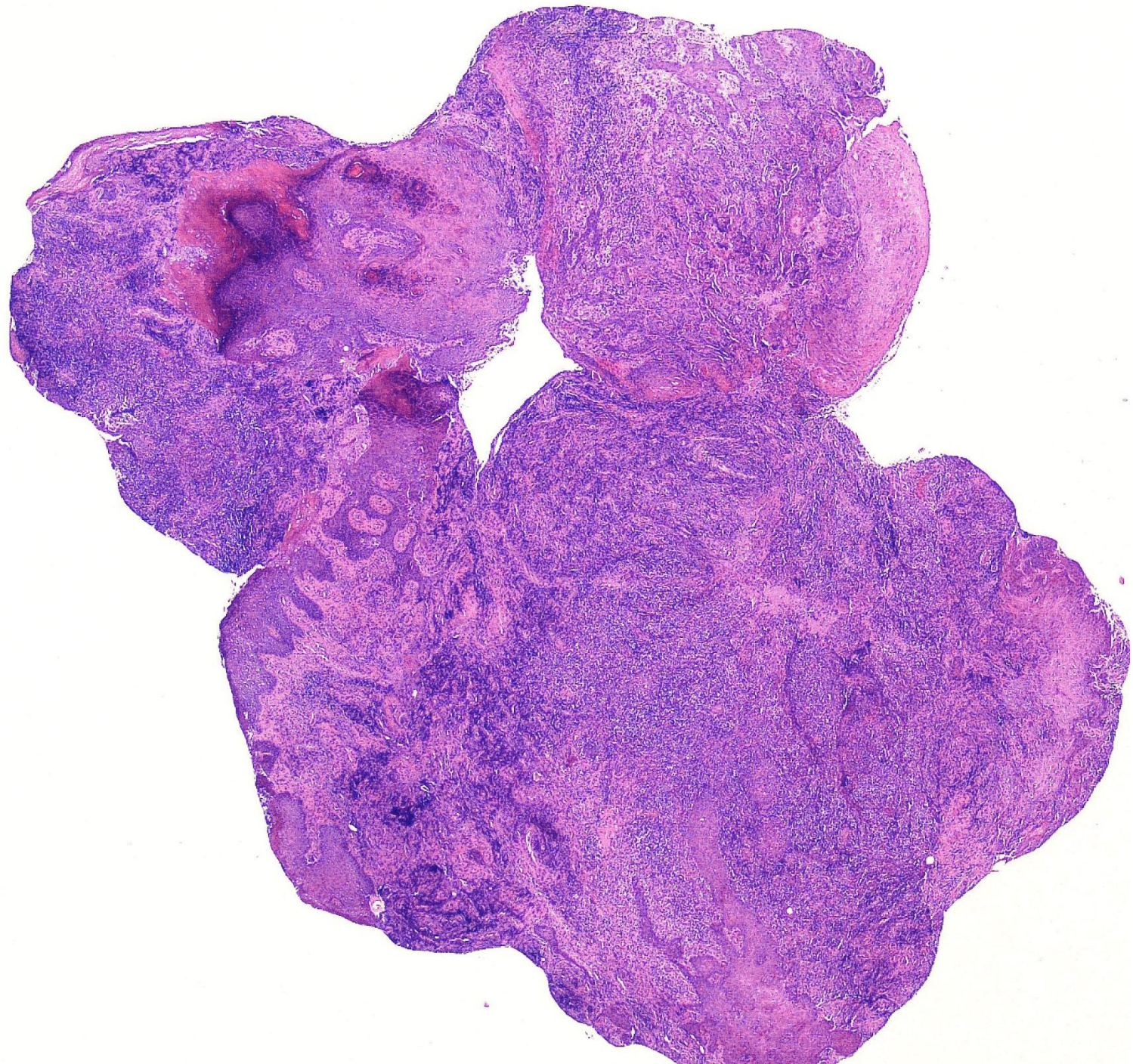
- **EBV-LPDs** represents a wide pathologic spectrum that includes reactive hyperplasia, EBV-positive mucocutaneous ulcer, (iatrogenic) immunodeficiency-associated lymphoproliferative disorder and DLBCL, with varied morphologic appearances.
- The range of clinical behaviour is wide
- DLBCL cases have poor survival

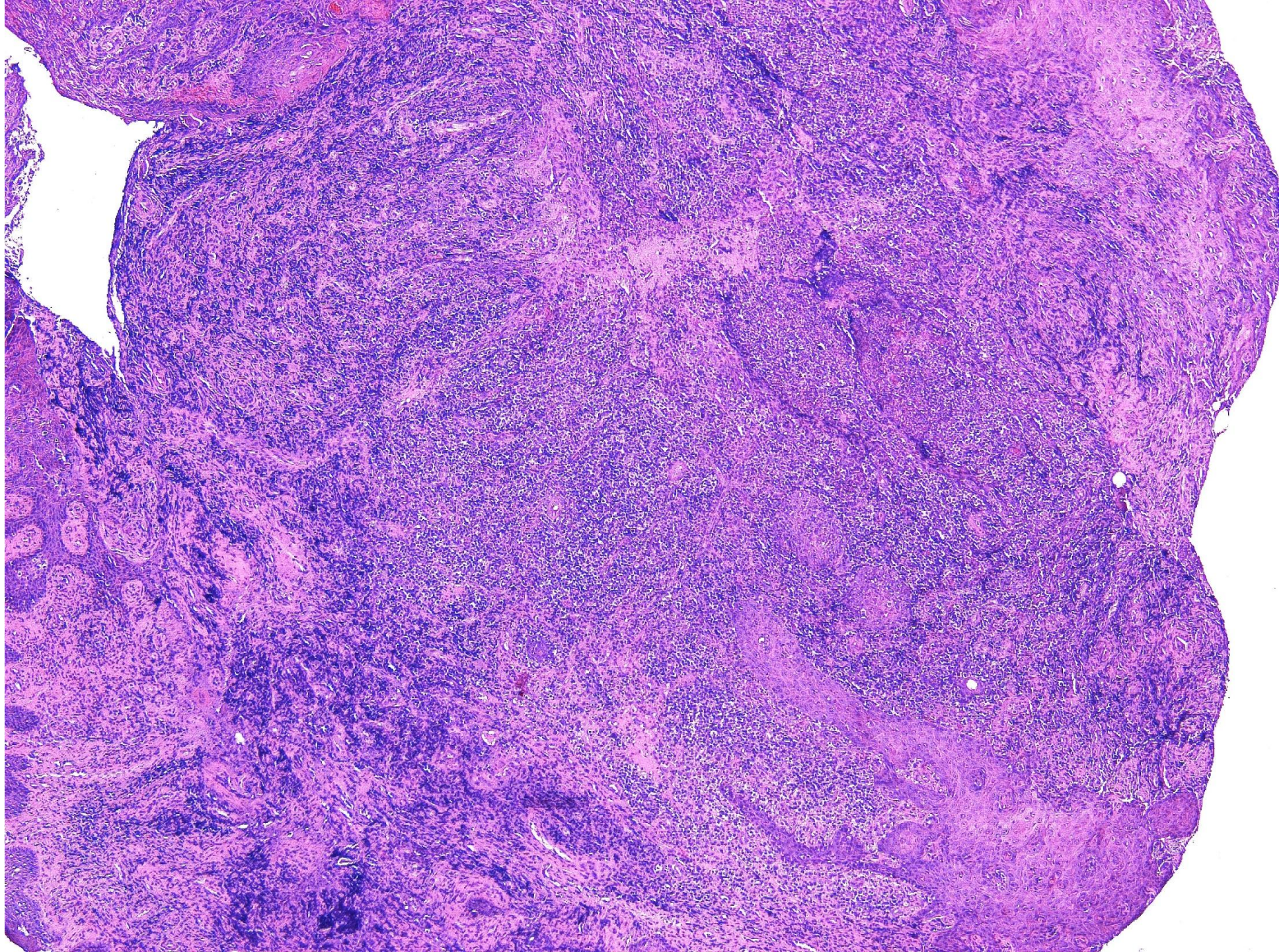
CASE 2

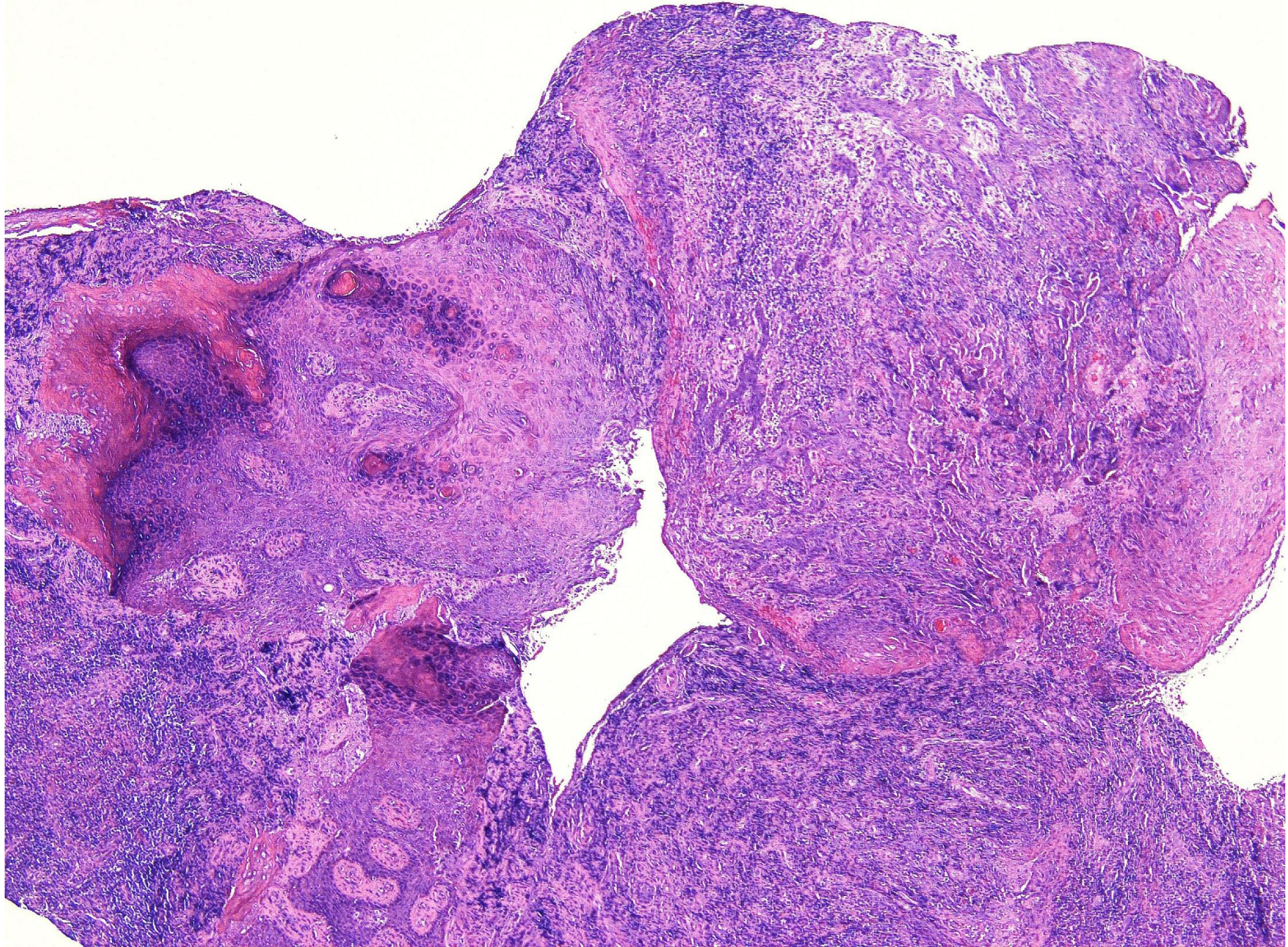
CLINICAL HISTORY

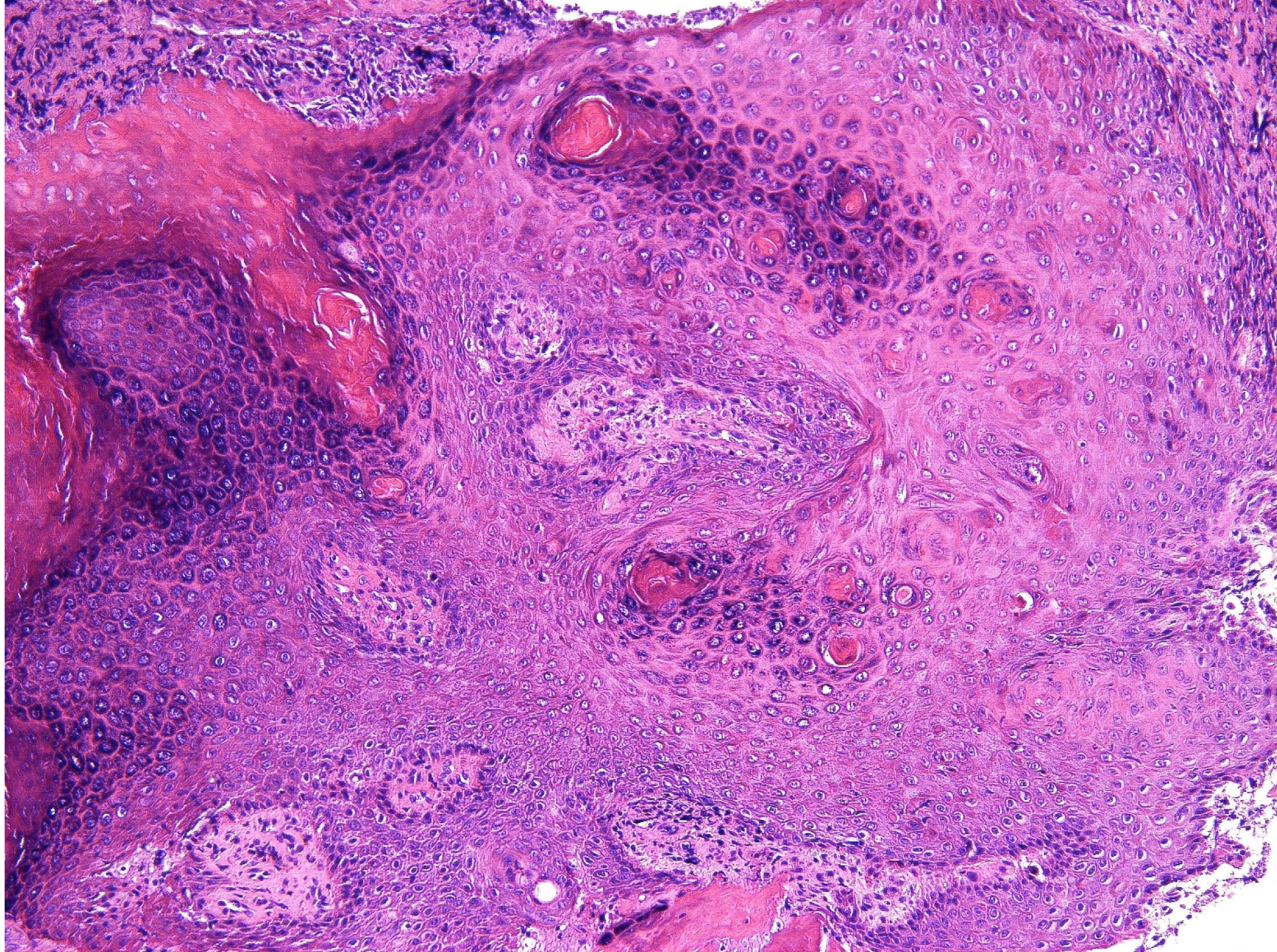
- **Female, 31**
- **HIV positive**
- **Vegetative lesion left hand**

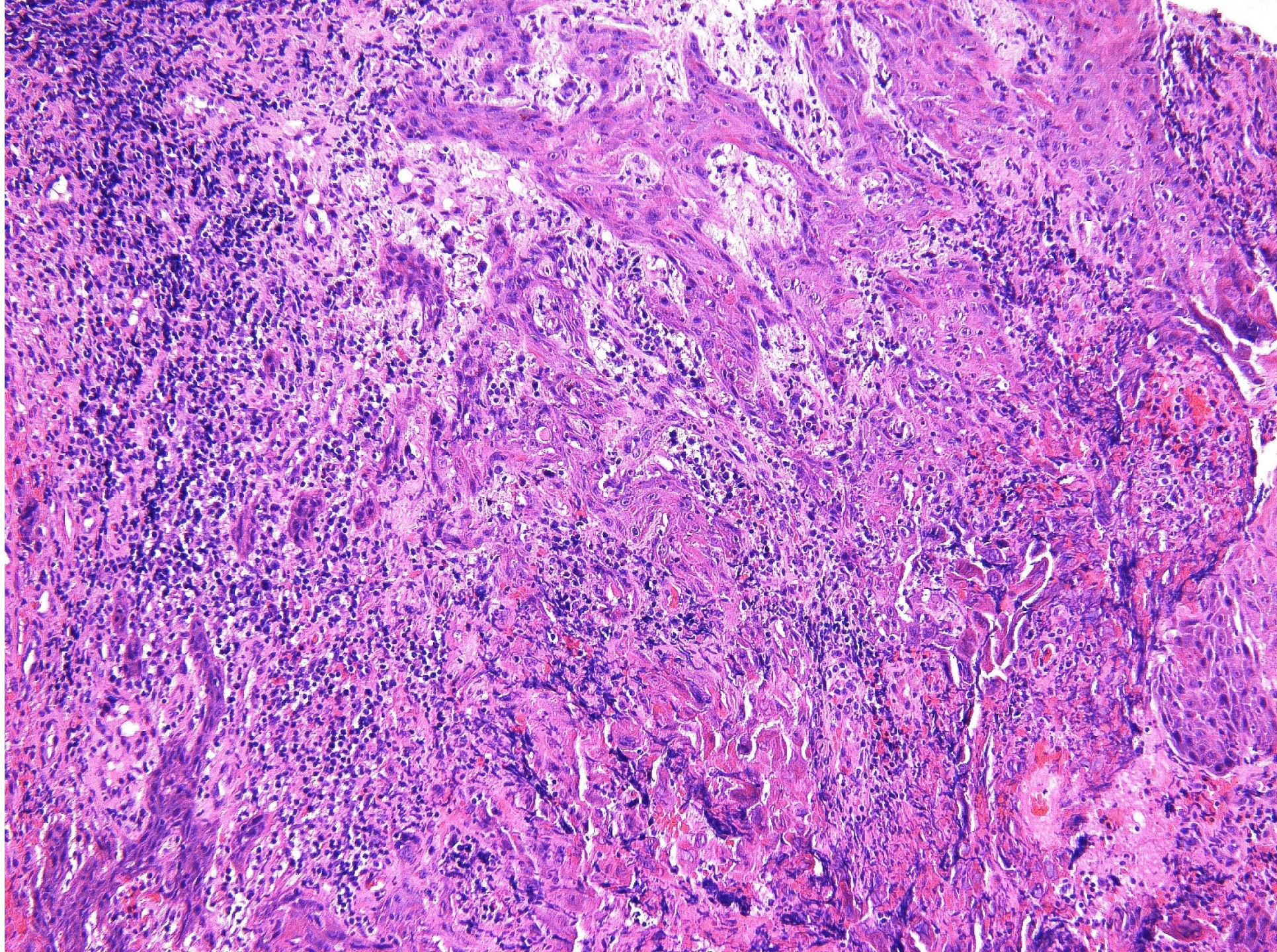
Histopathology

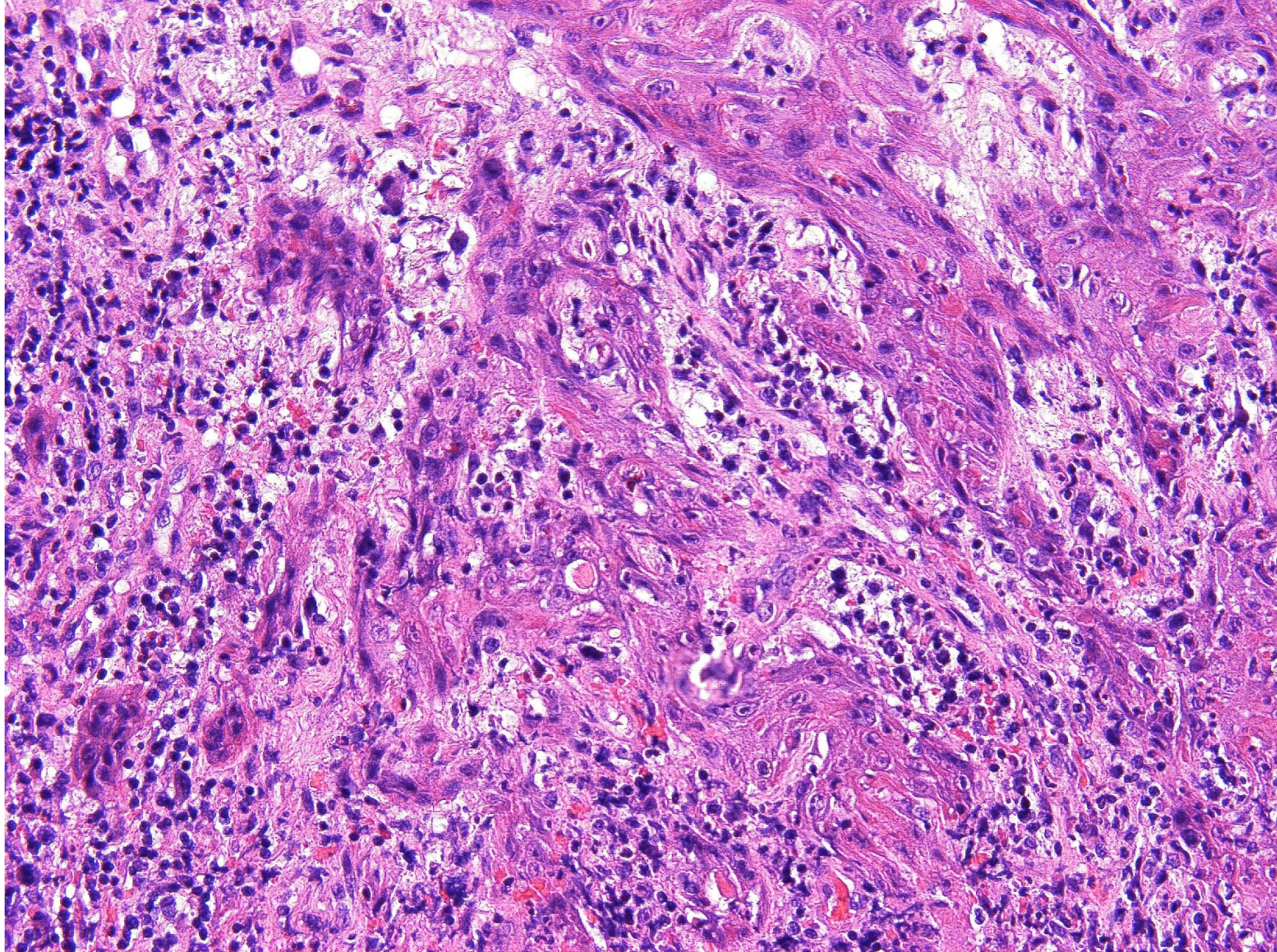


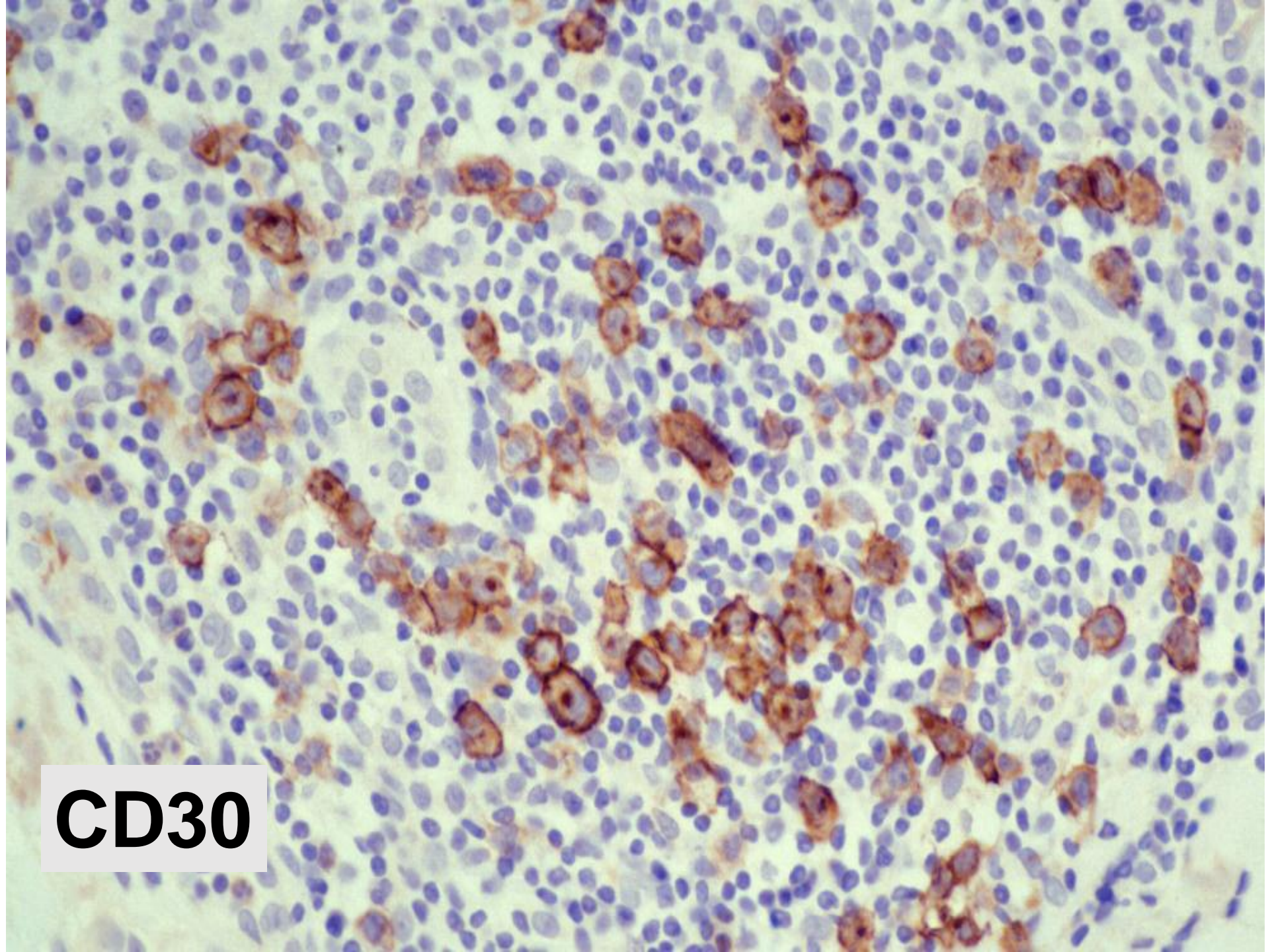




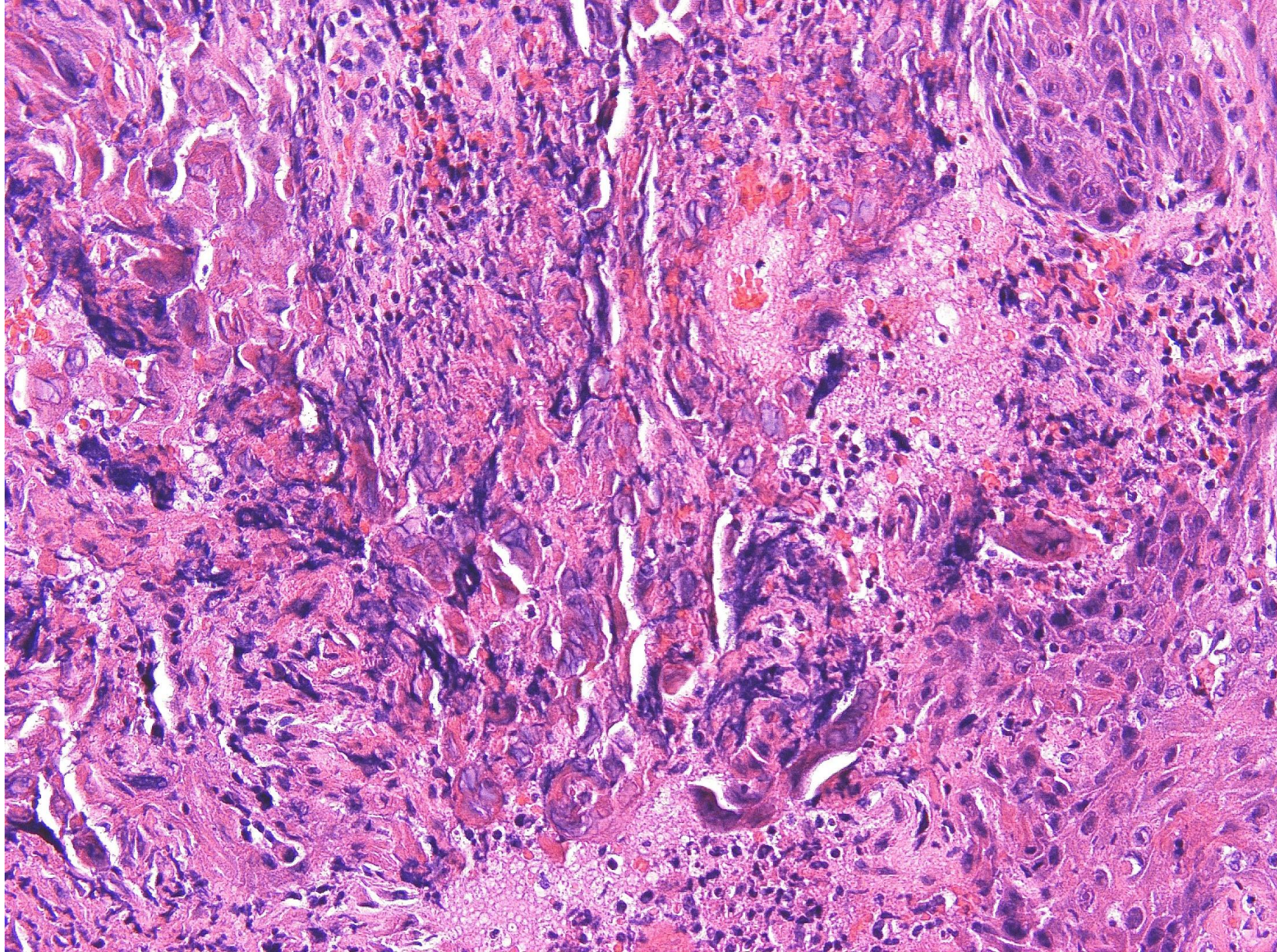


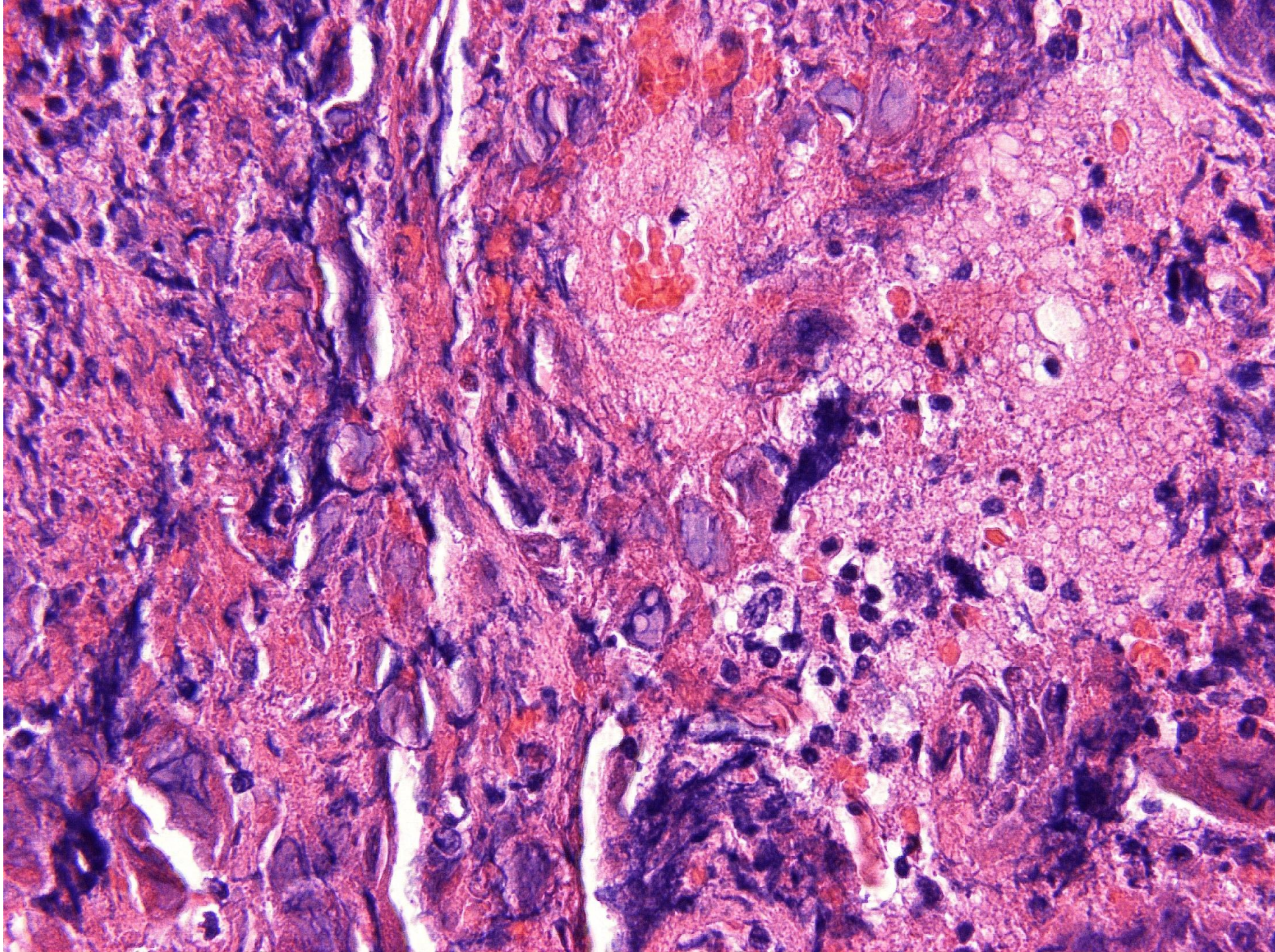


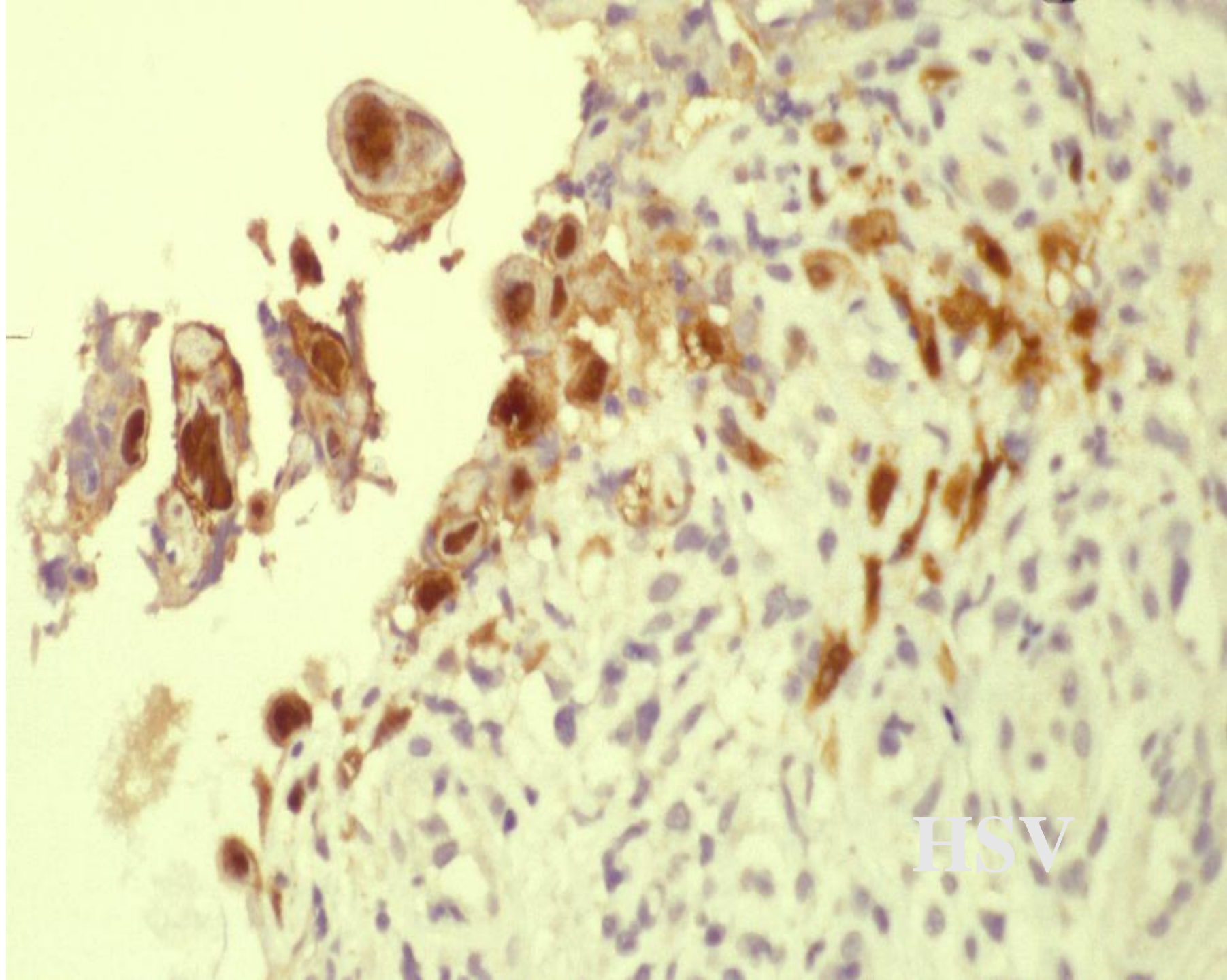




CD30







HSV

CASE 2

The main diagnosis to consider is:

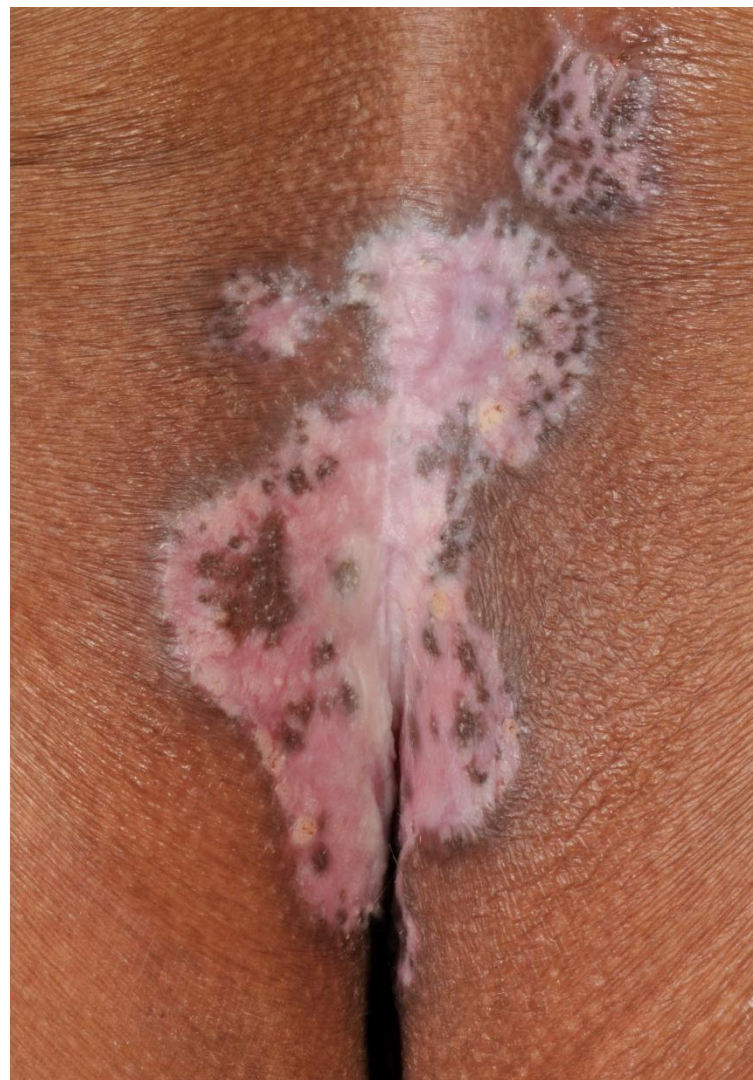- A. Squamous cell carcinoma
- B. Keratoacanthoma
- C. Lymphomatoid papulosis type A and pseudoepitheliomatous hyperplasia
- D. Verrucous herpes associated with pseudolymphoma and pseudoepitheliomatous hyperplasia
- E. Cutaneous T-cell lymphoma and pseudoepitheliomatous hyperplasia

CASE 2

The main diagnosis to consider is:

- A. Squamous cell carcinoma
- B. Keratoacanthoma
- C. Lymphomatoid papulosis type A and pseudoepitheliomatous hyperplasia
- D. Verrucous herpes associated with pseudolymphoma and pseudoepitheliomatous hyperplasia**
- E. Cutaneous T-cell lymphoma and pseudoepitheliomatous hyperplasia

Hypertrophic HSV



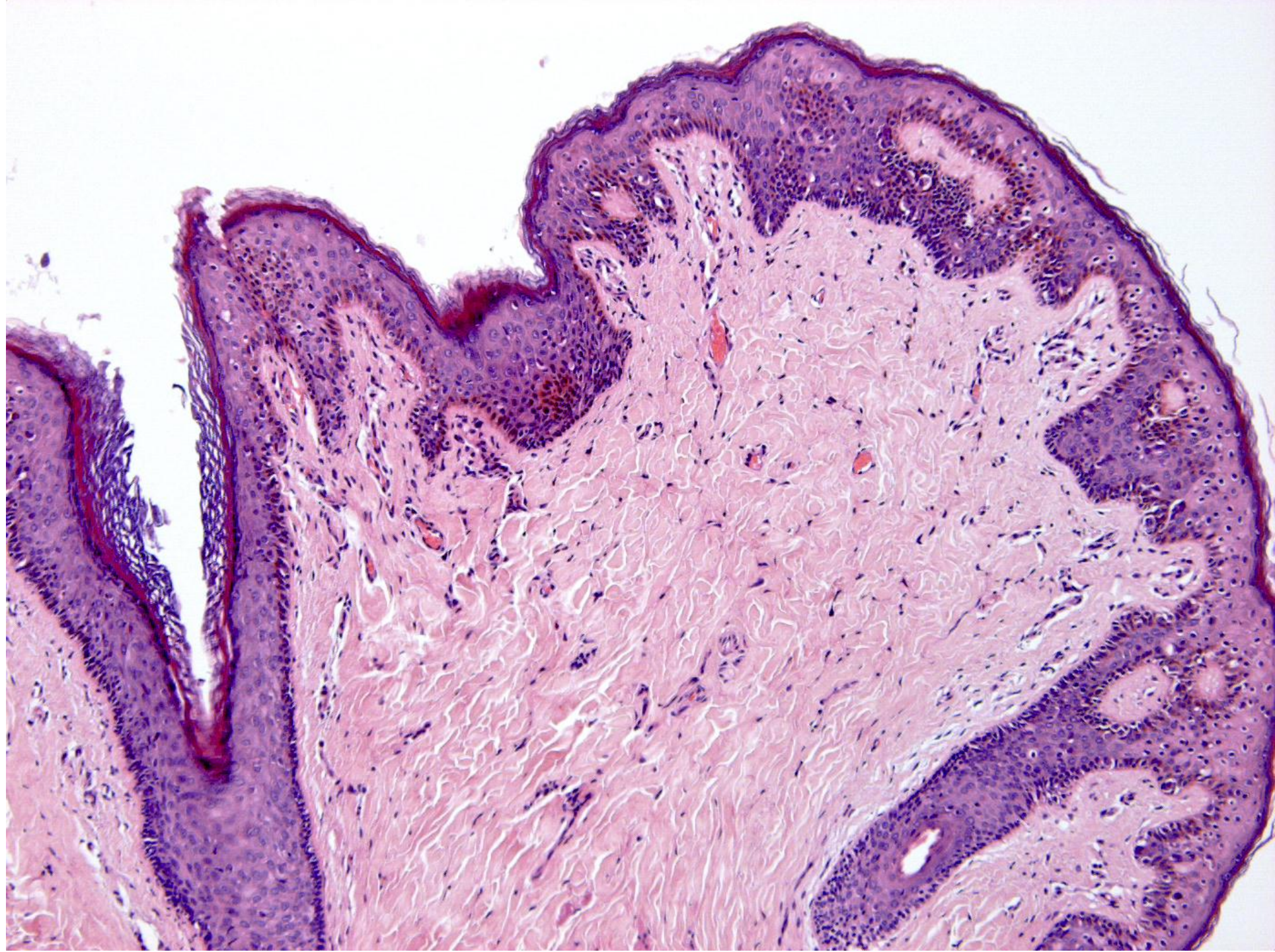
VERRUCOUS HERPES/HERPES VEGETANS

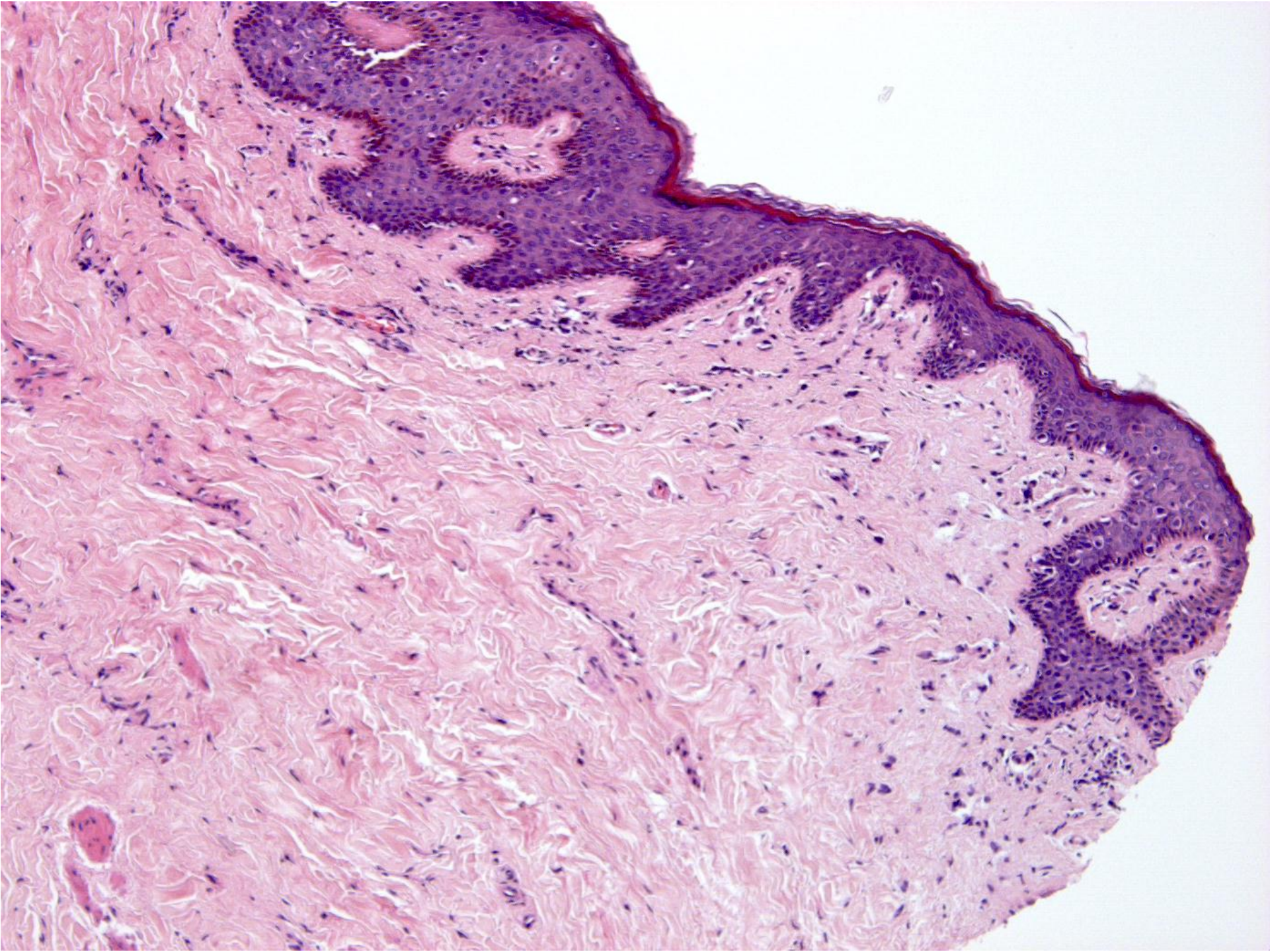
- Usually seen in cases of advanced HIV
- Can be seen in congenital immunodeficiencies and exceptionally in immunocompetent patients (?)
- Mainly associated with herpes zoster
- Presents as warty nodules or plaques
- Up to 20 cm
- May be associated with resistance to acyclovir, famcyclovir and valacyclovir
- Clinically and histologically mimics a squamous cell carcinoma
- May be associated with a pseudolymphomatous reaction (CD30)

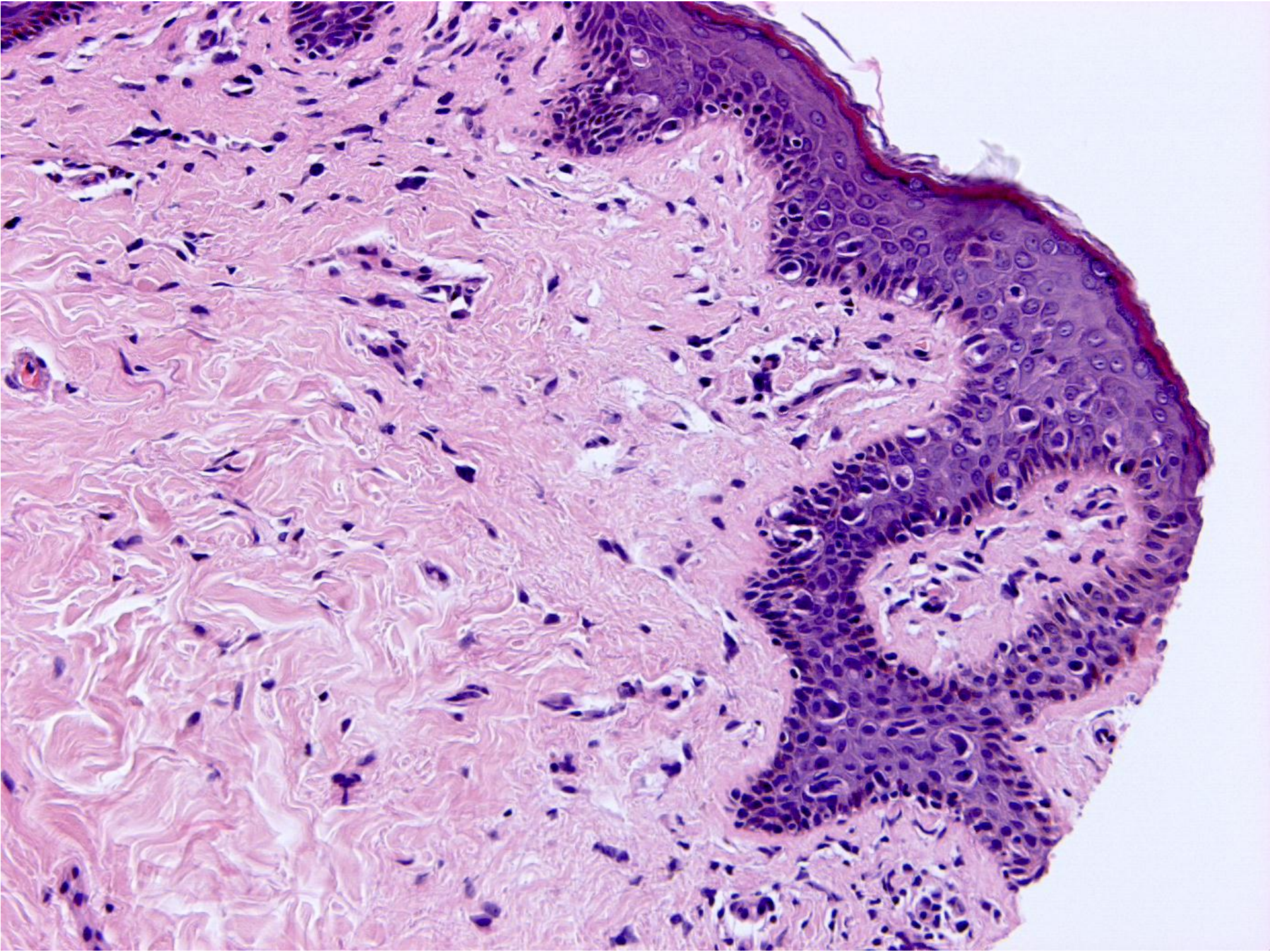
CASE 3

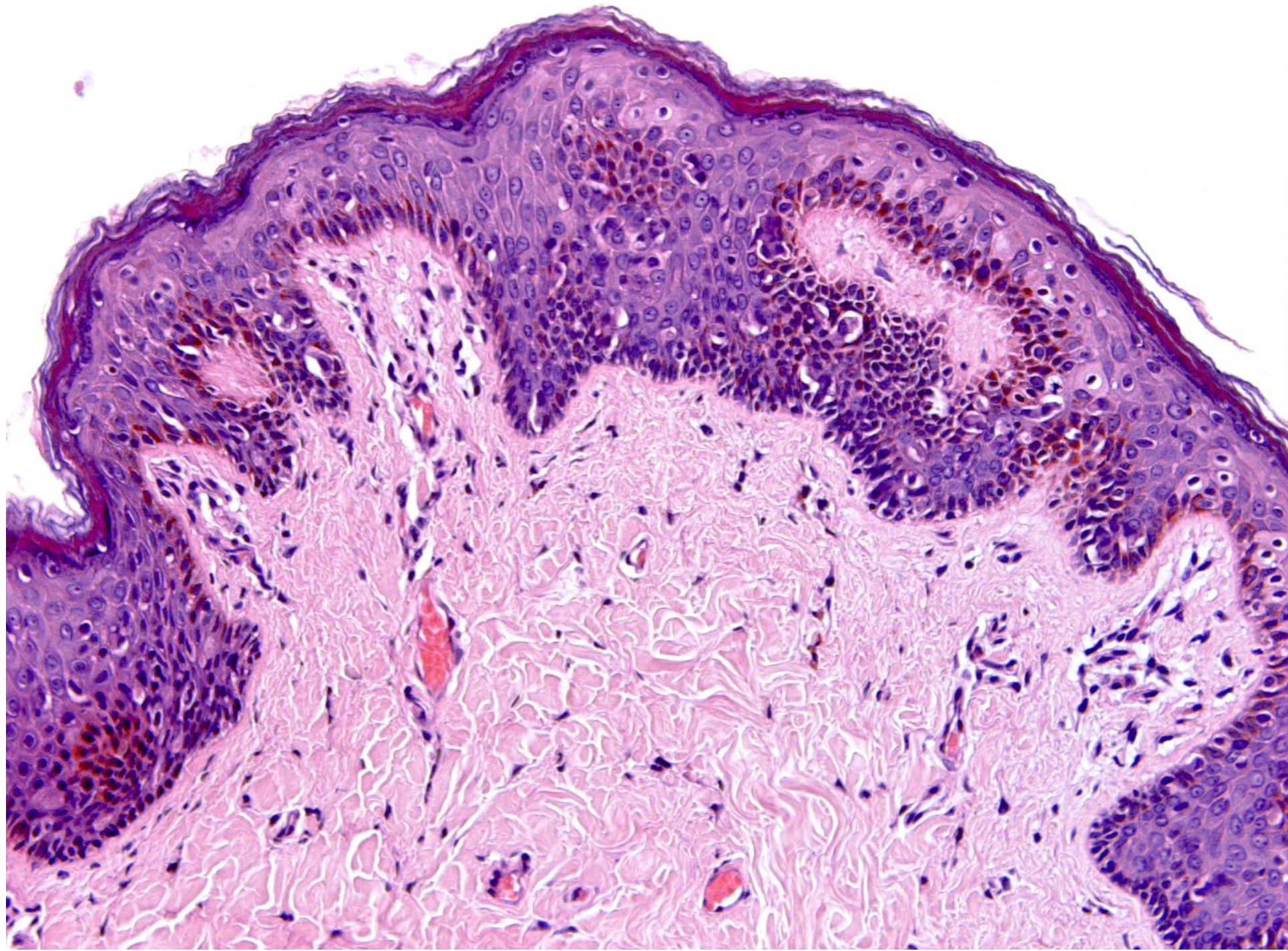
- 62 year-old female
- Pigmented lesion on the vulva
- ?Naevus. ?Melanoma

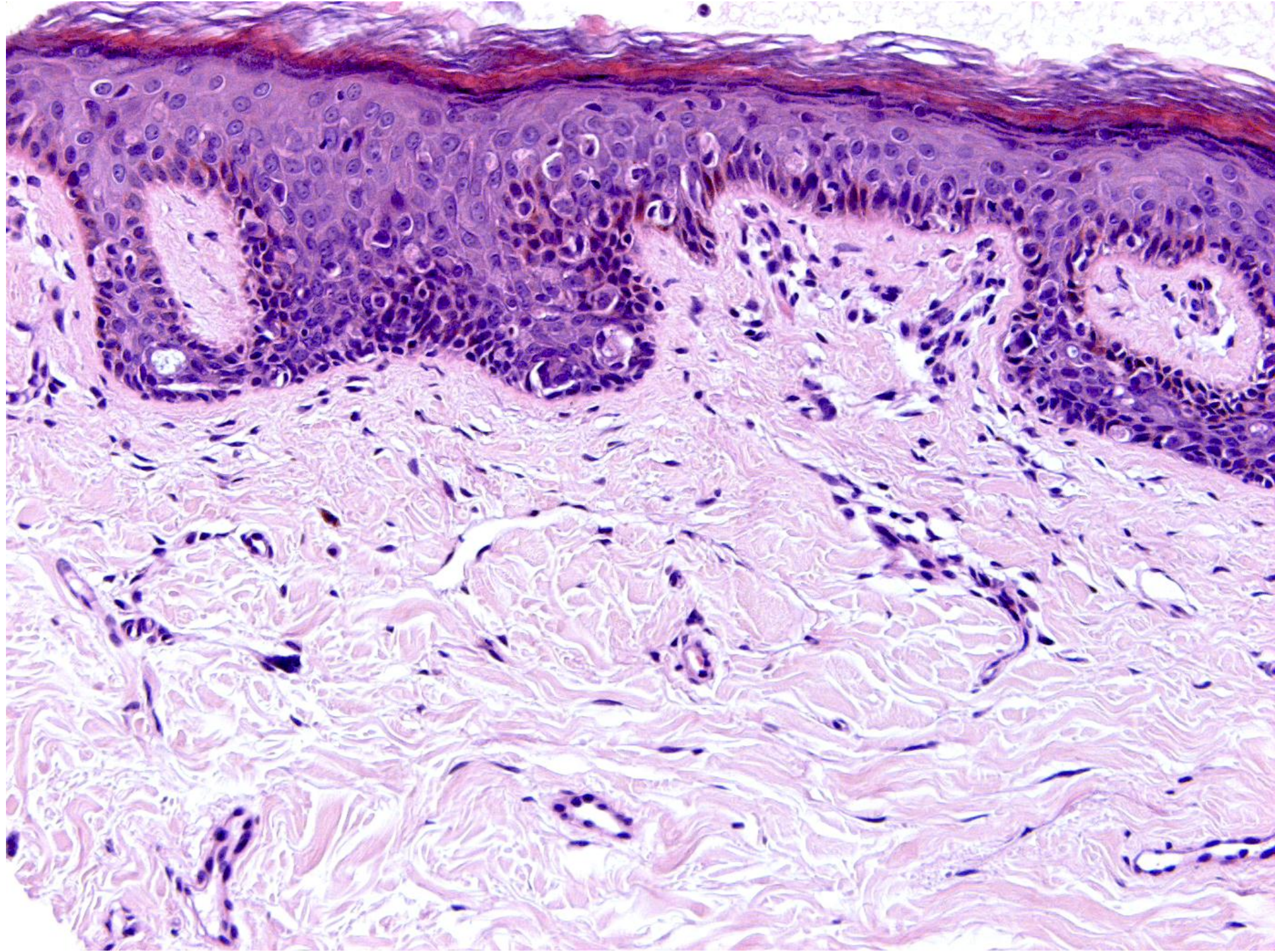
Histopathology

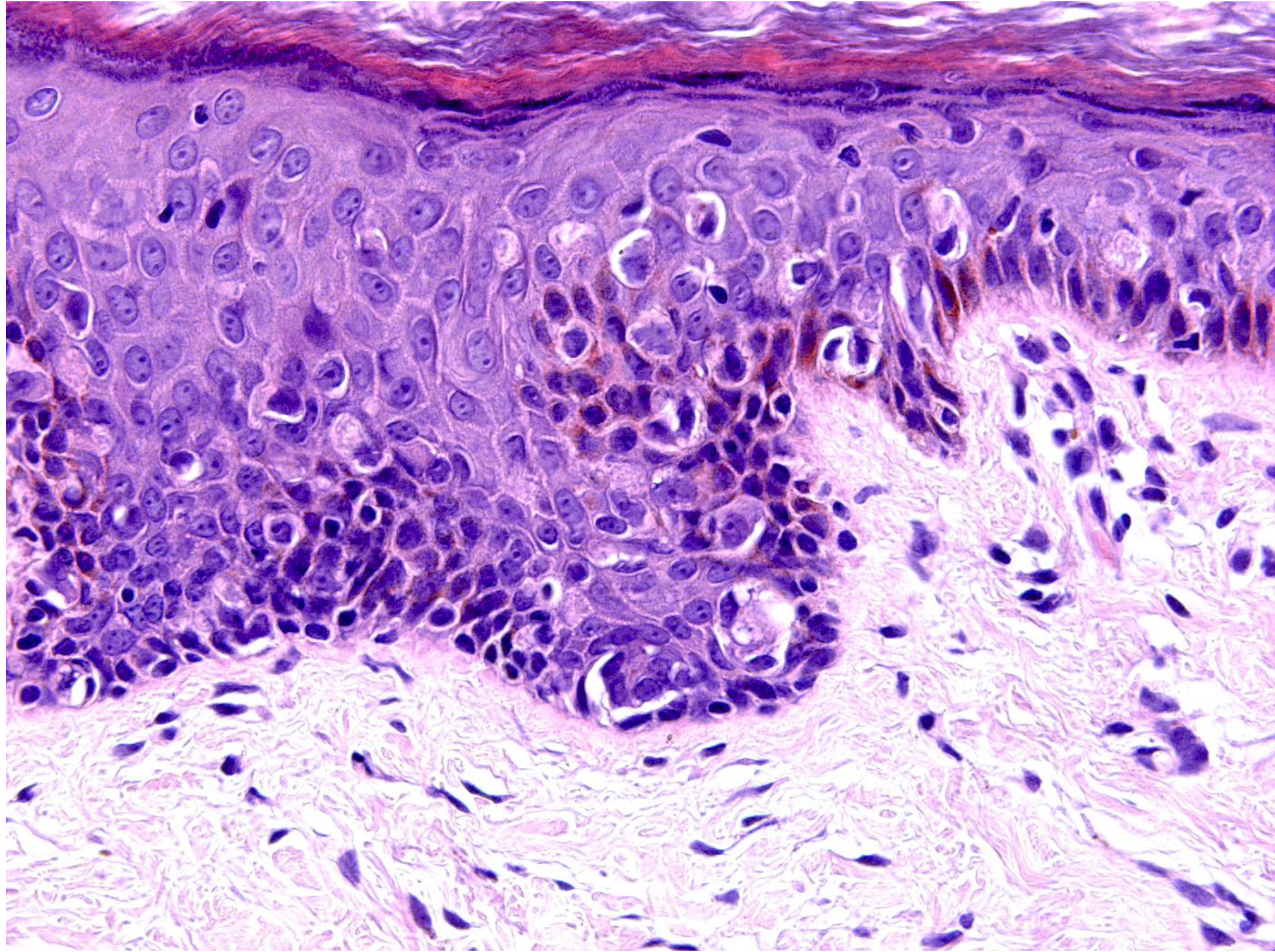


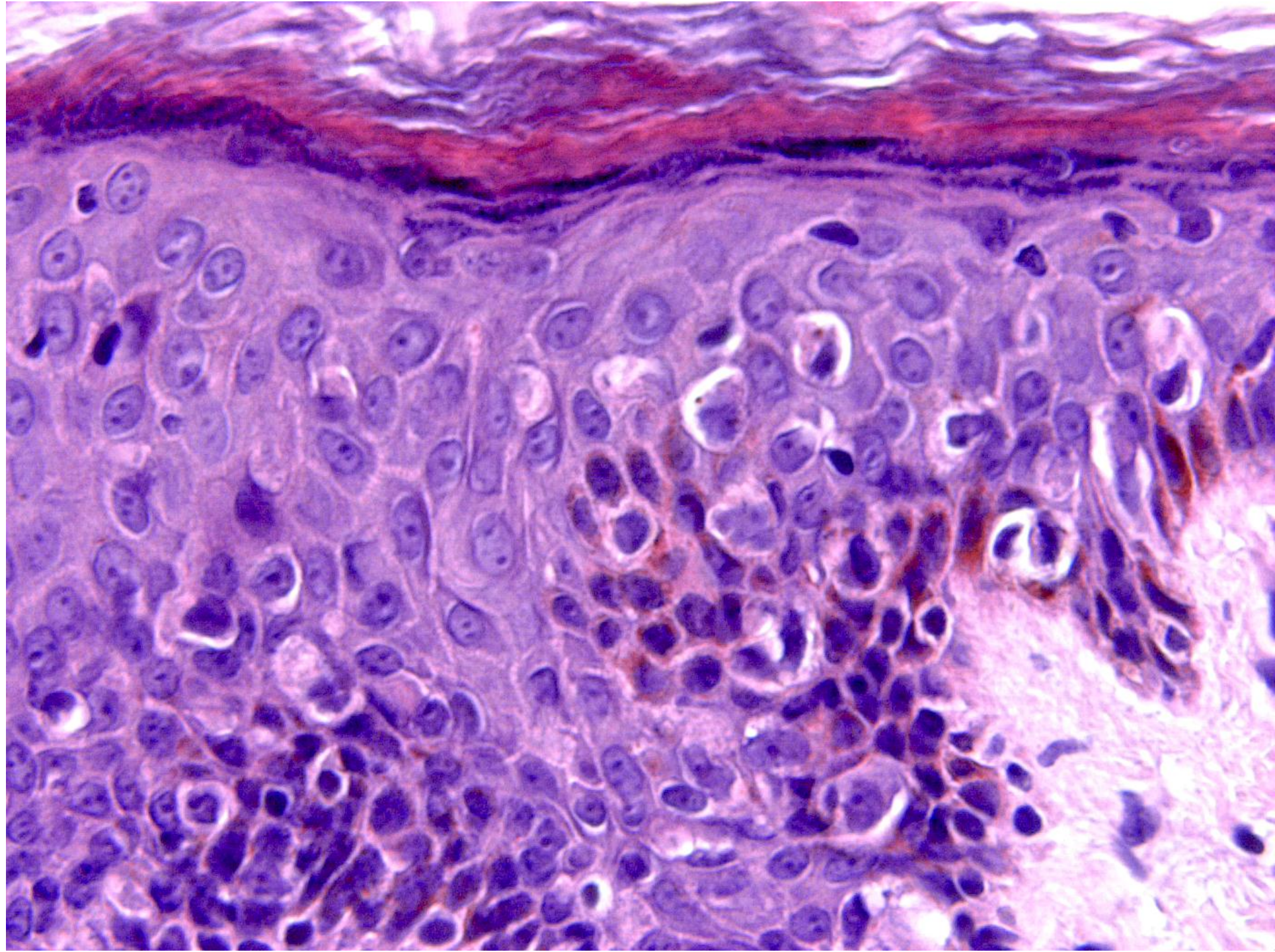


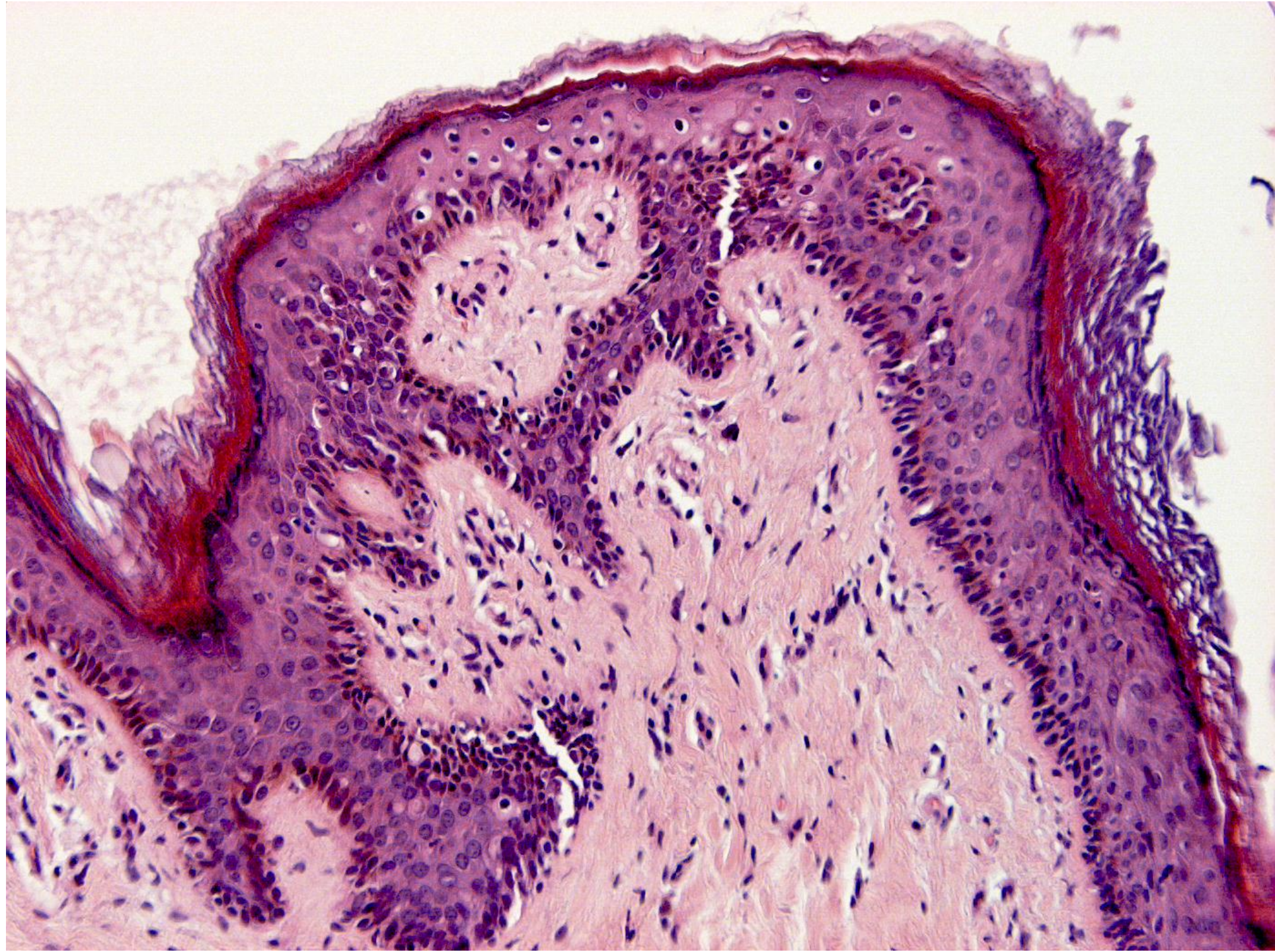


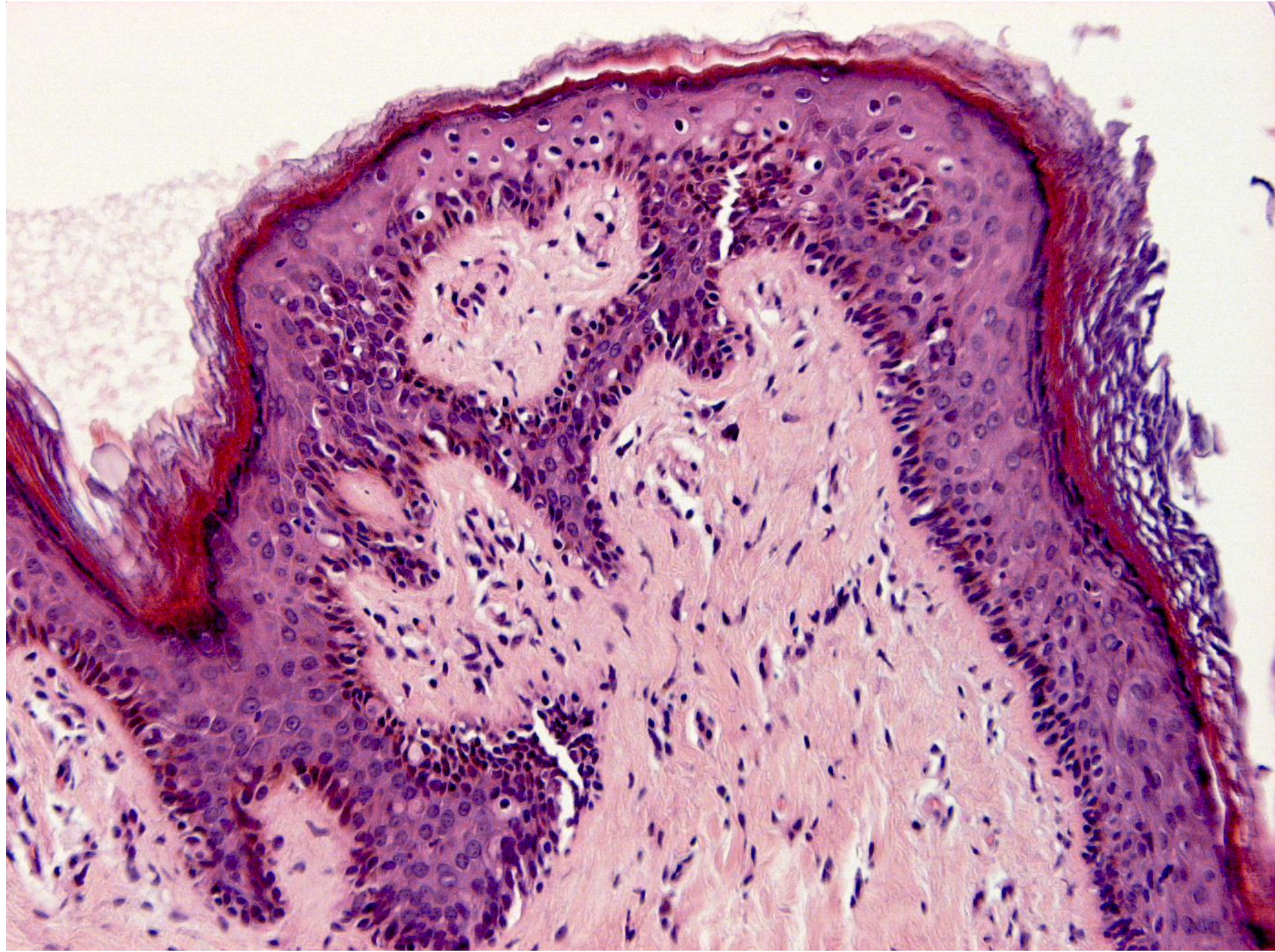


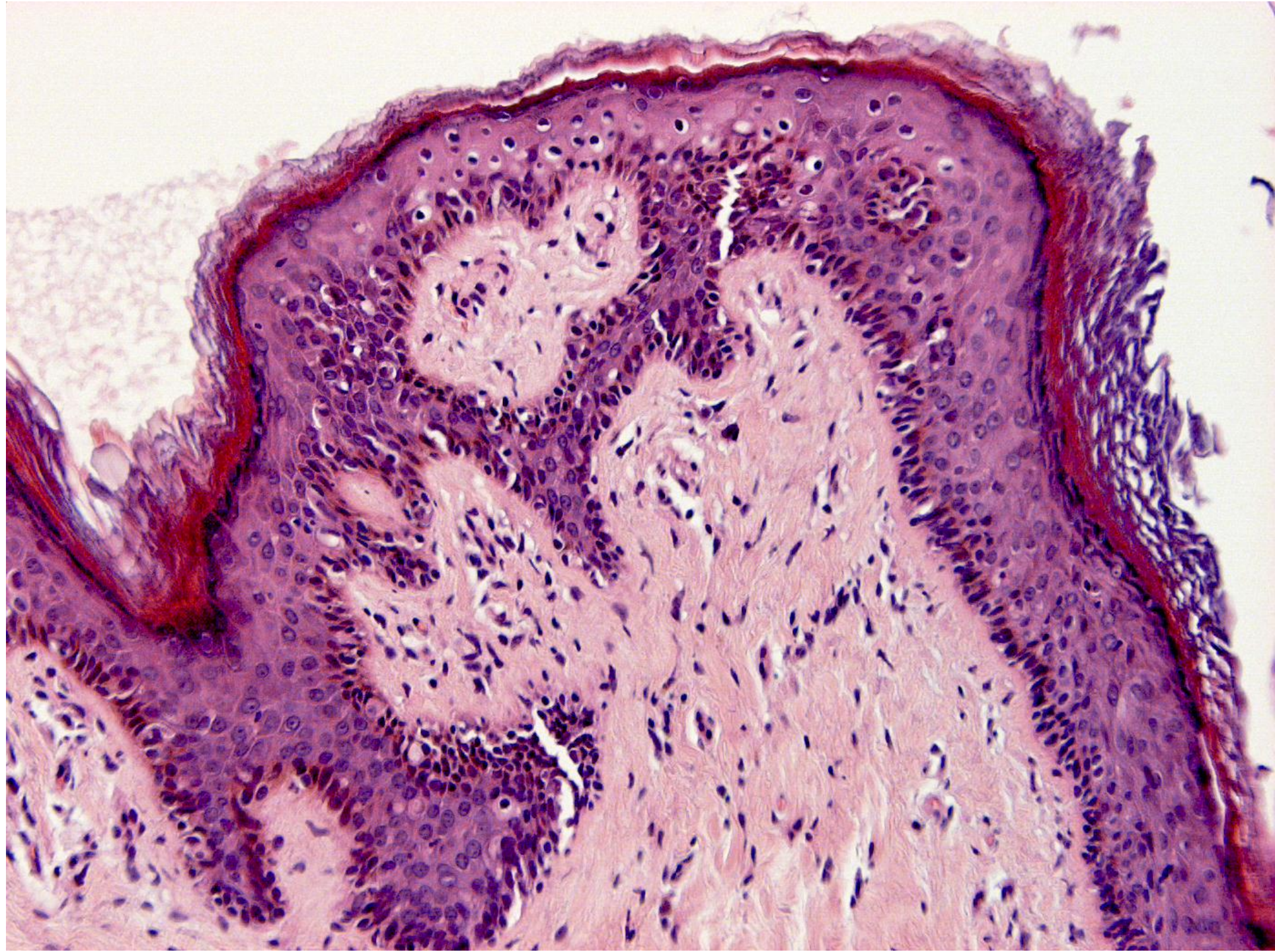


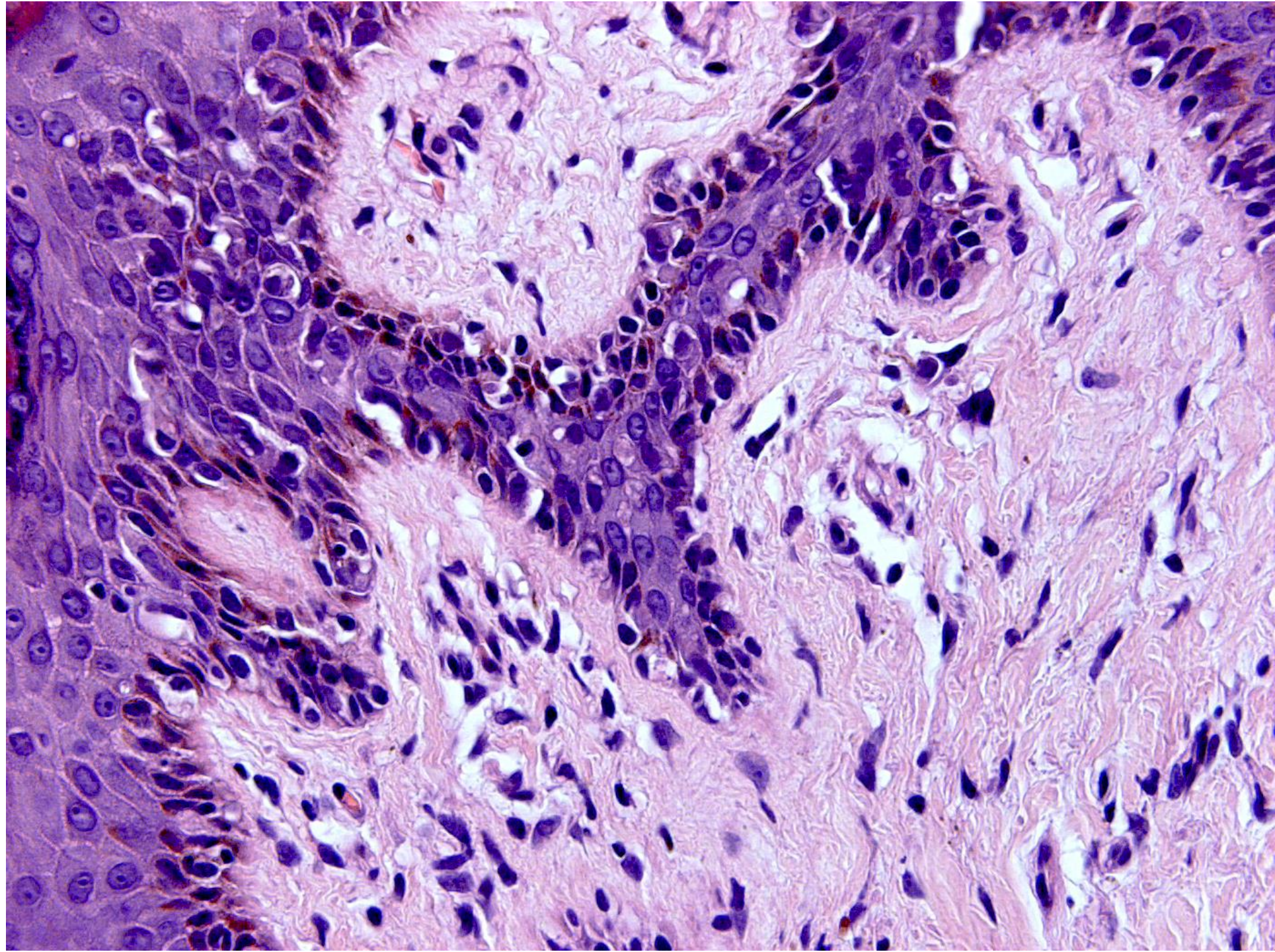


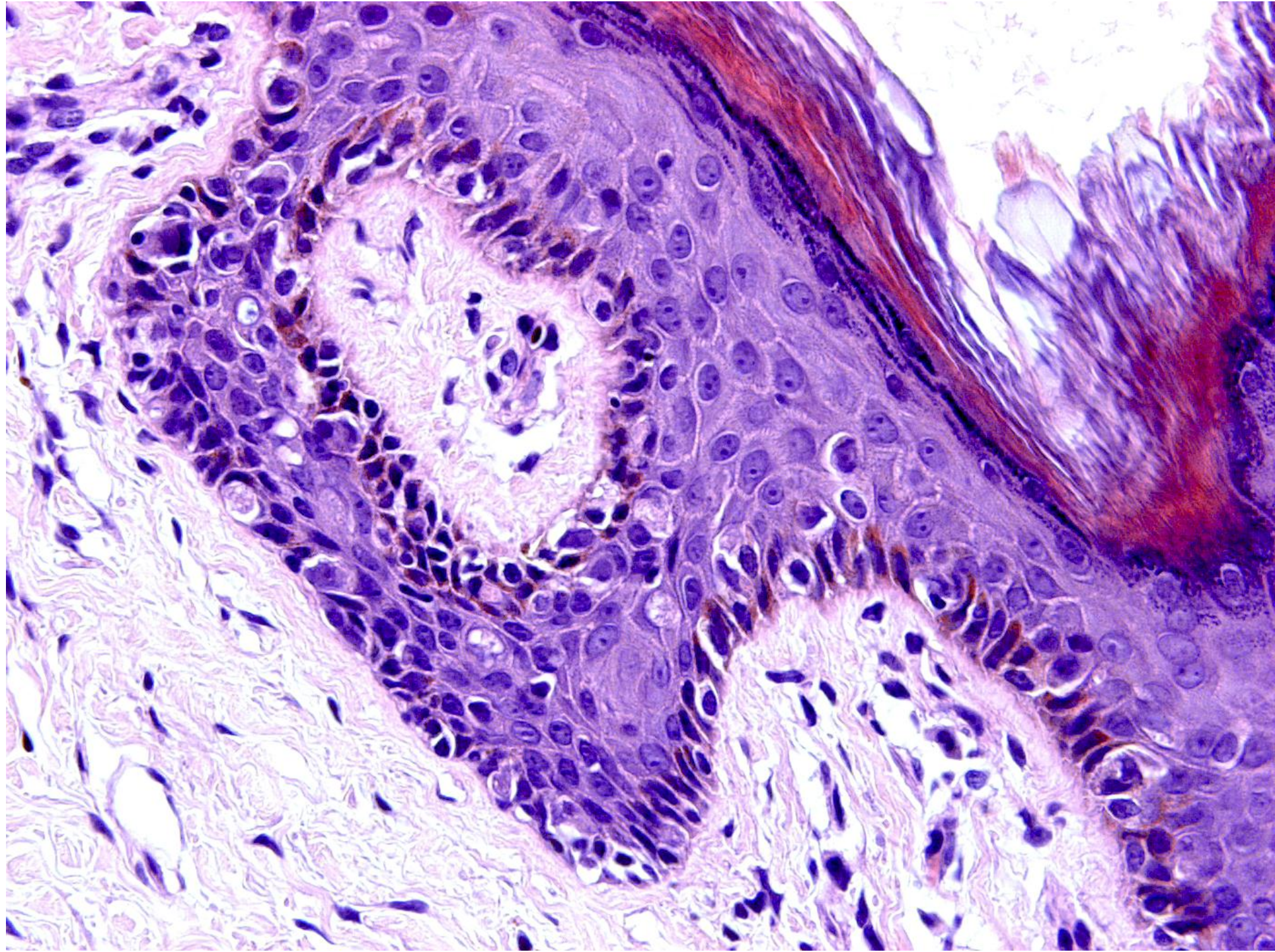


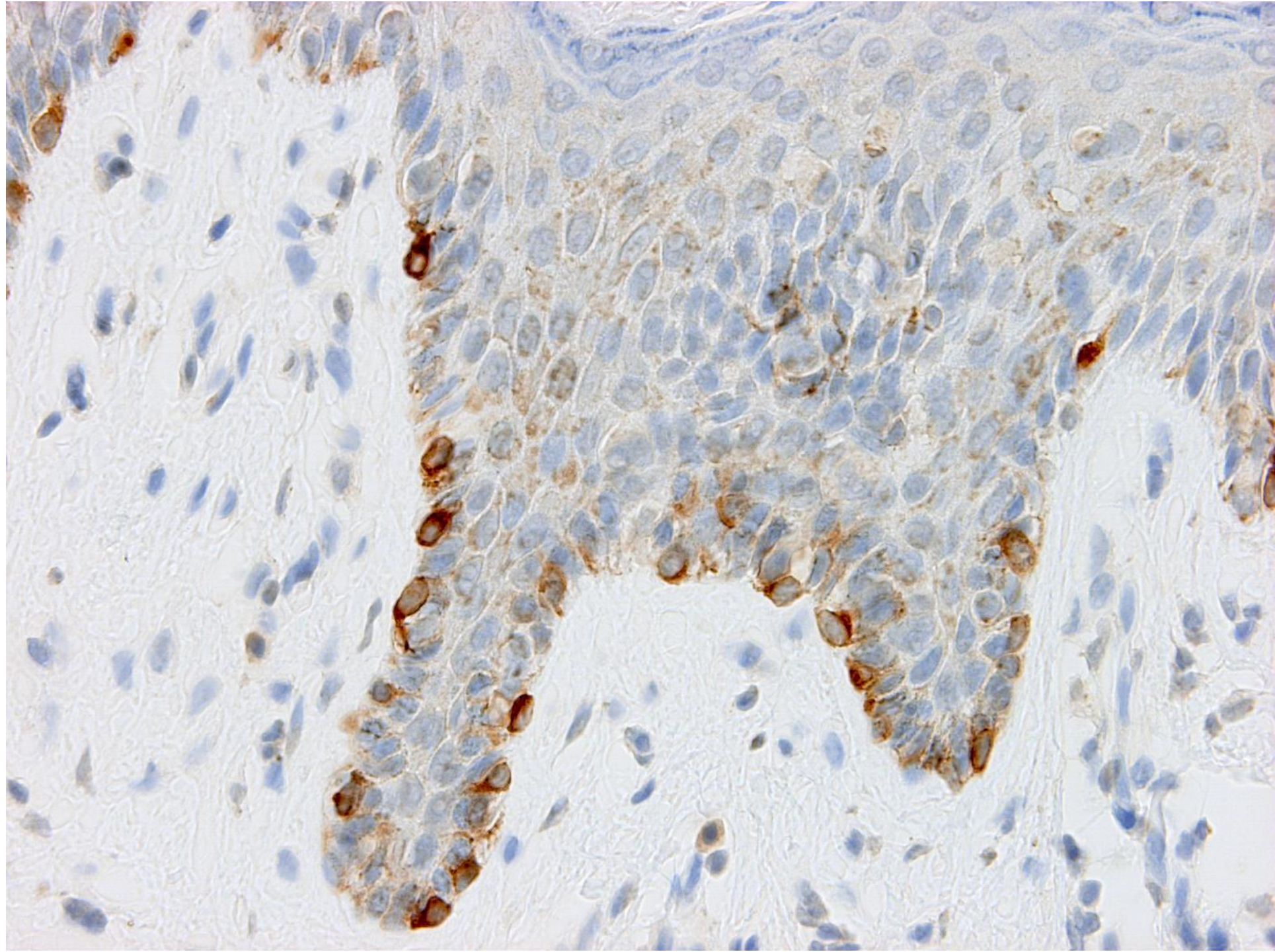


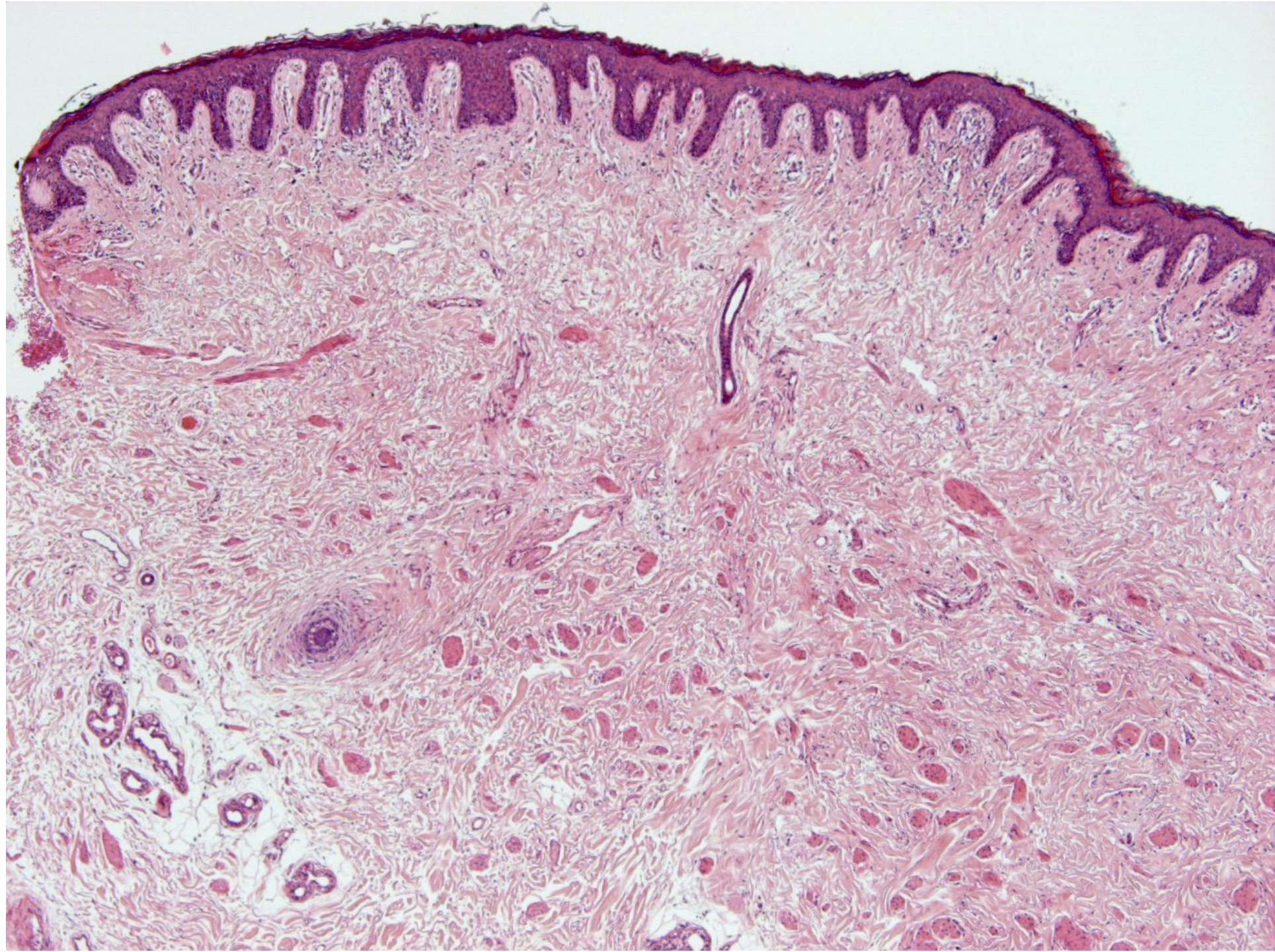


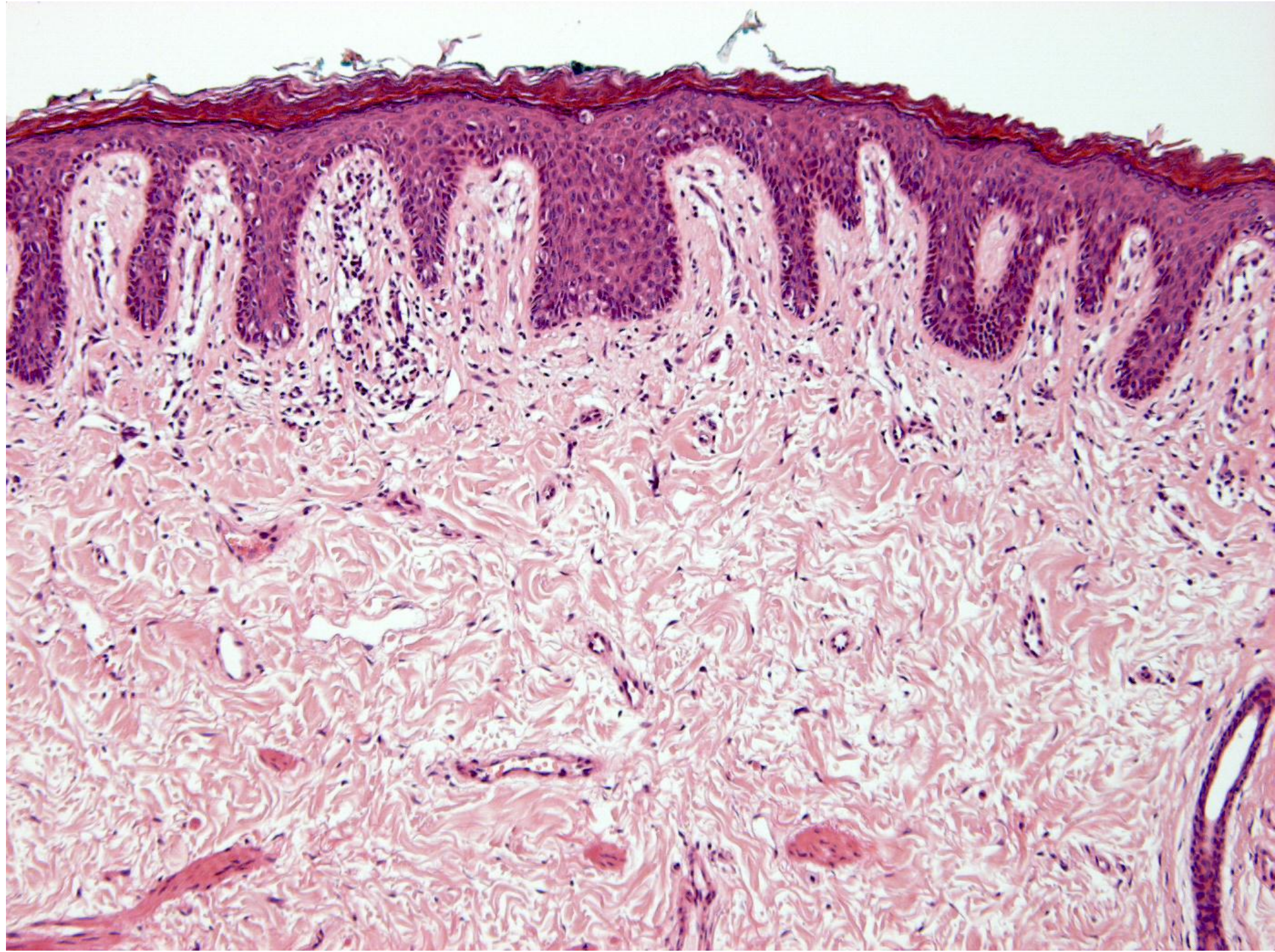


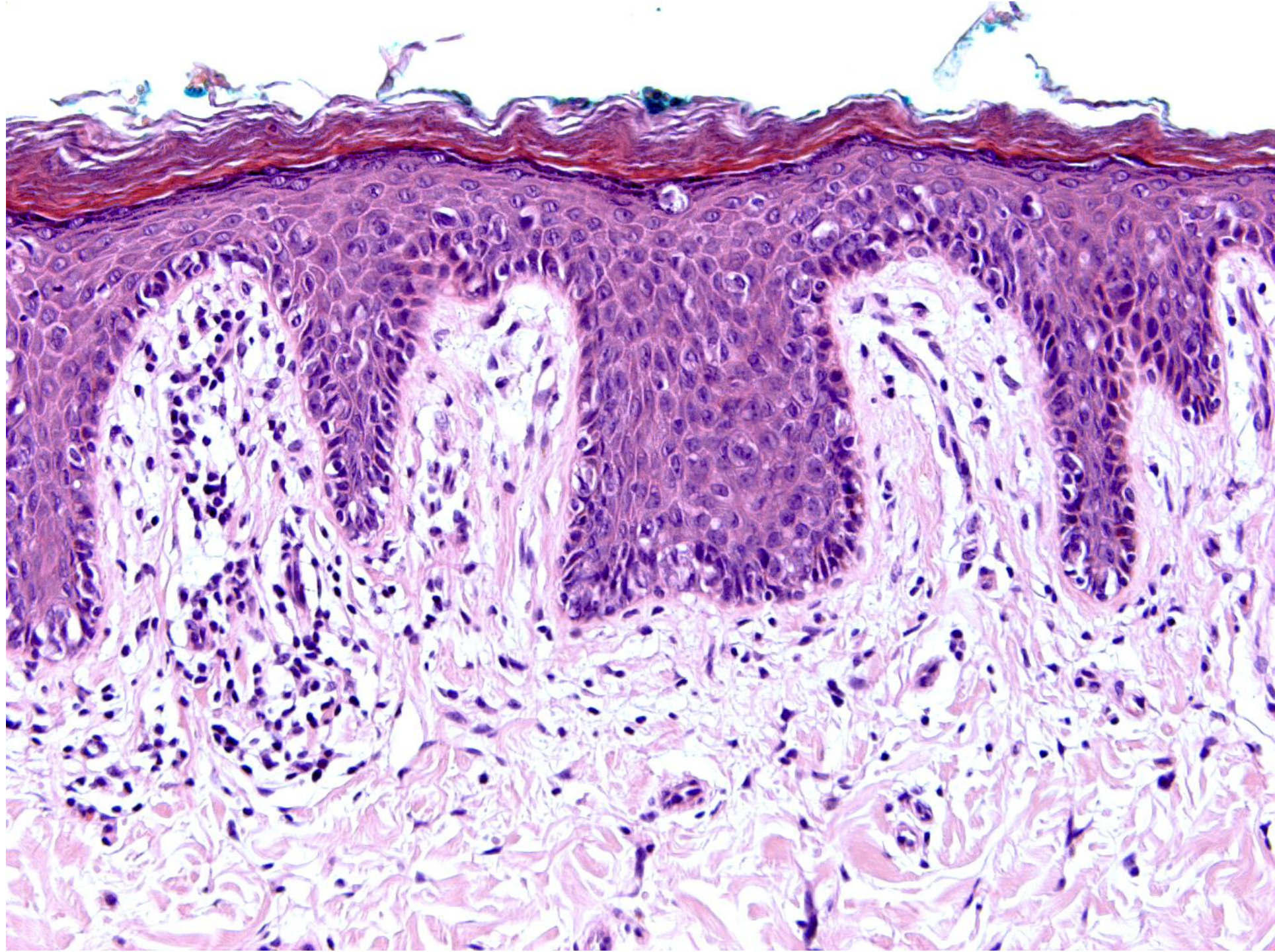


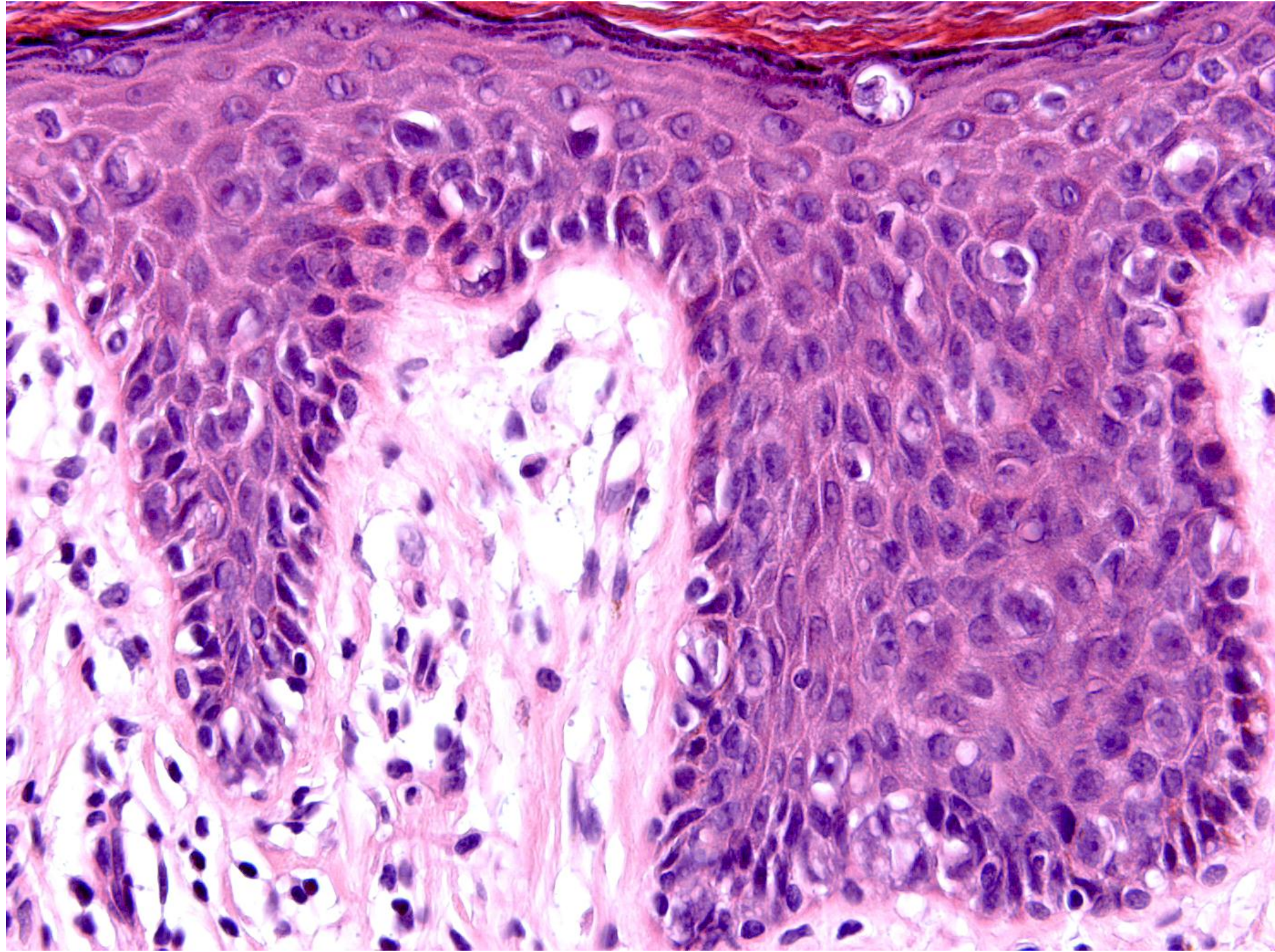


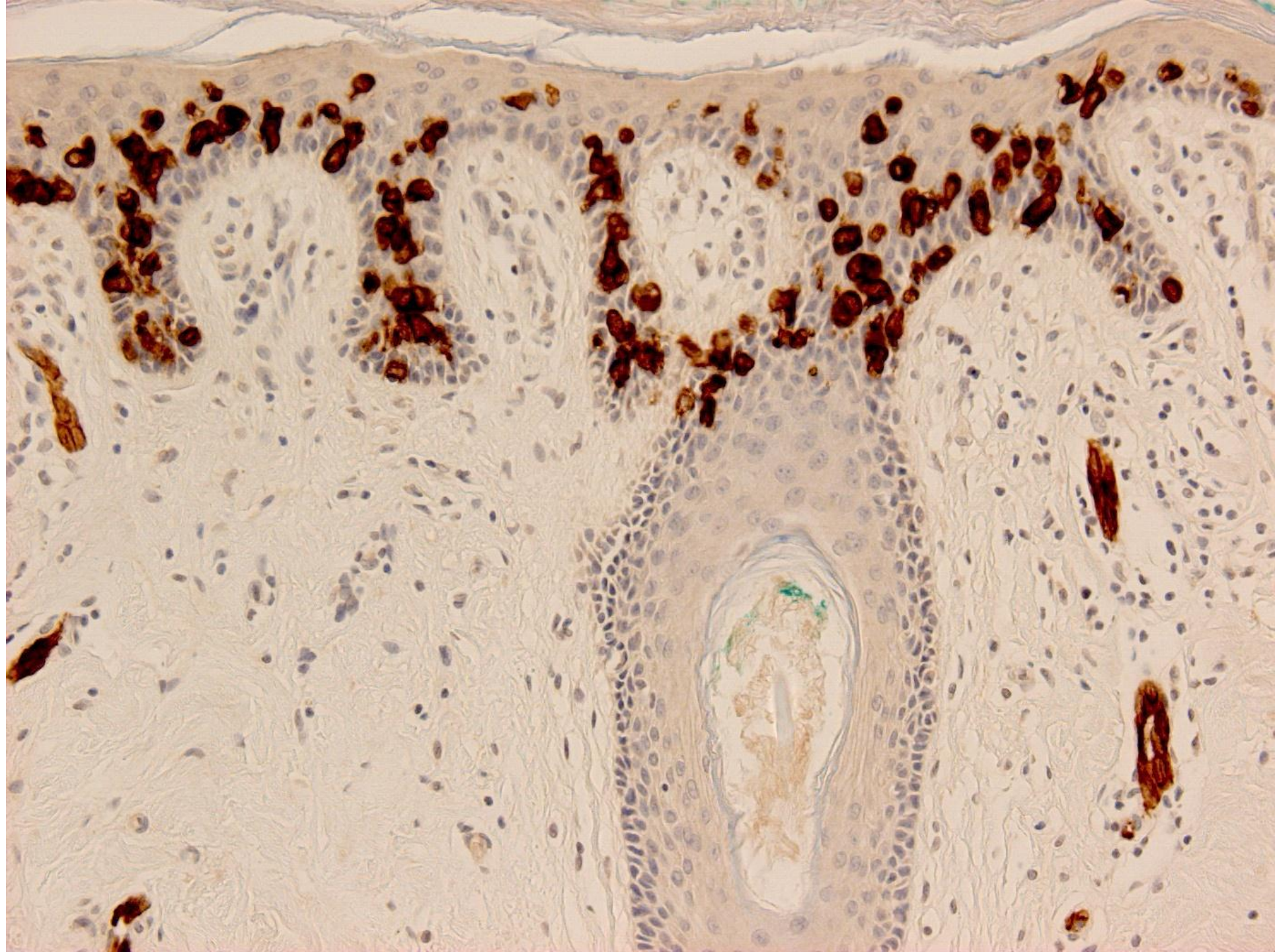










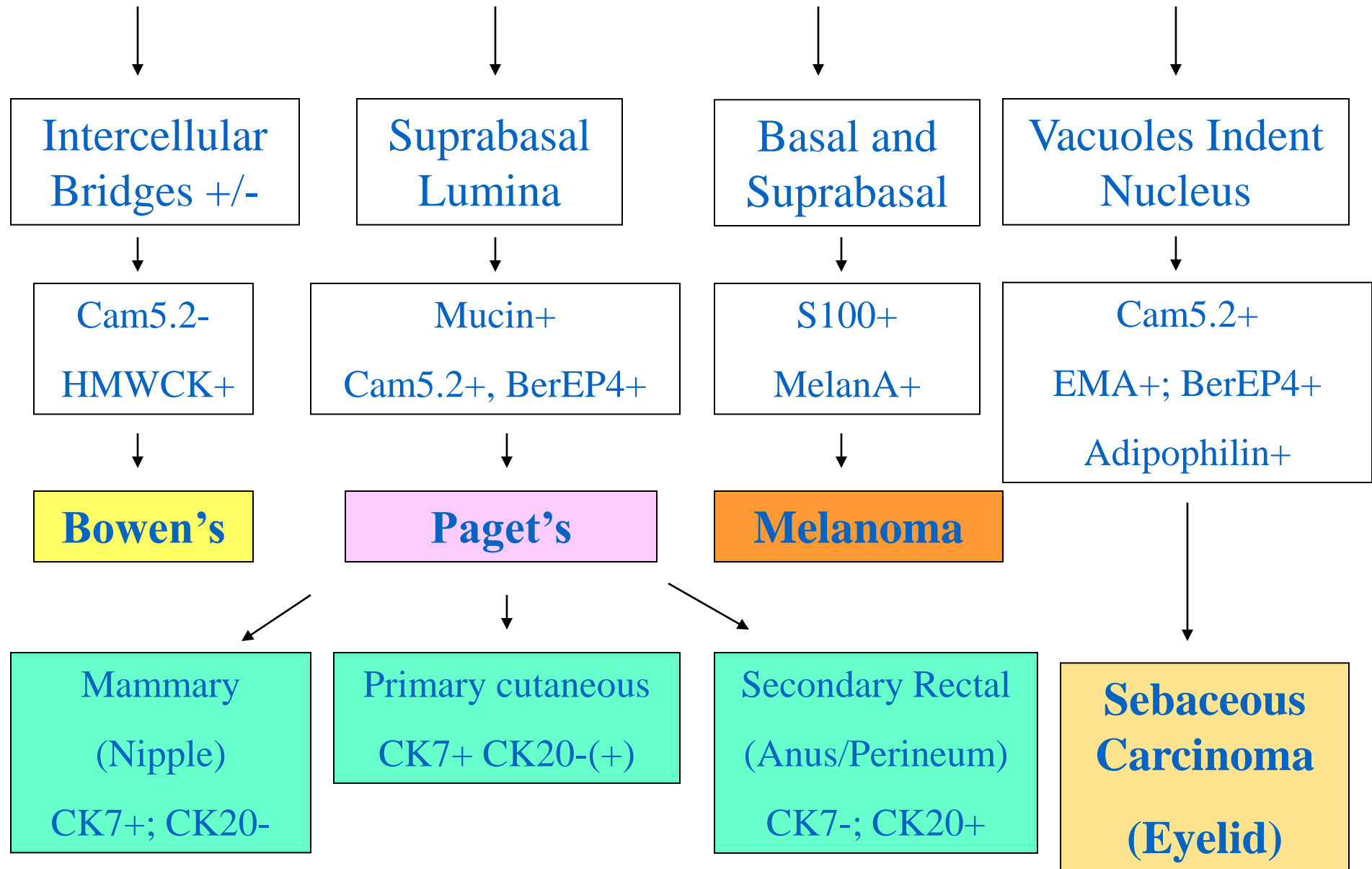


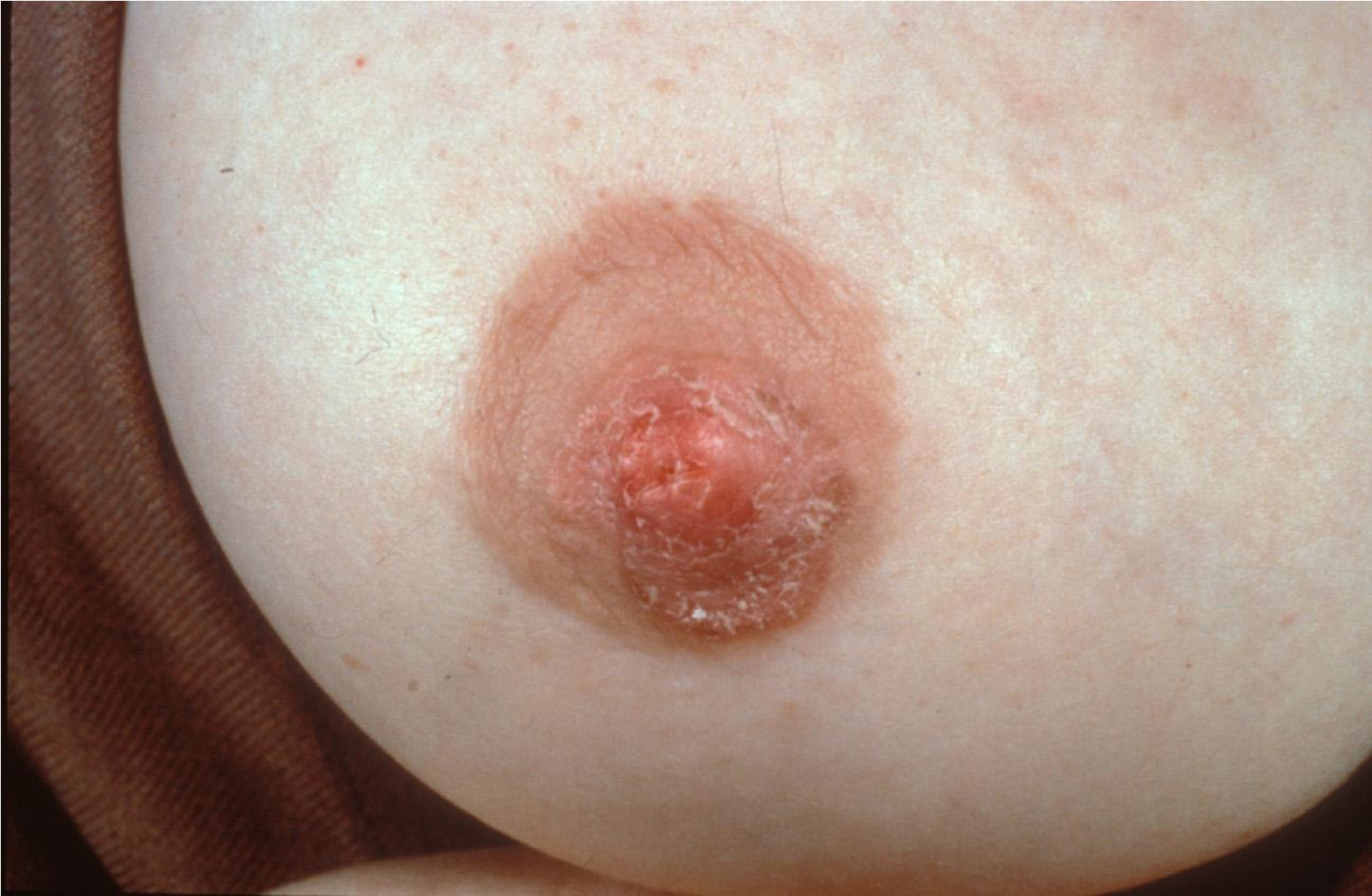- The best diagnosis is:
 - A. Atypical melanocytic hyperplasia
 - B. Vulval melanosis
 - C. Melanoma in-situ
 - D. Pigmented extramammary Paget's disease
 - E. Junctional melanocytic naevus

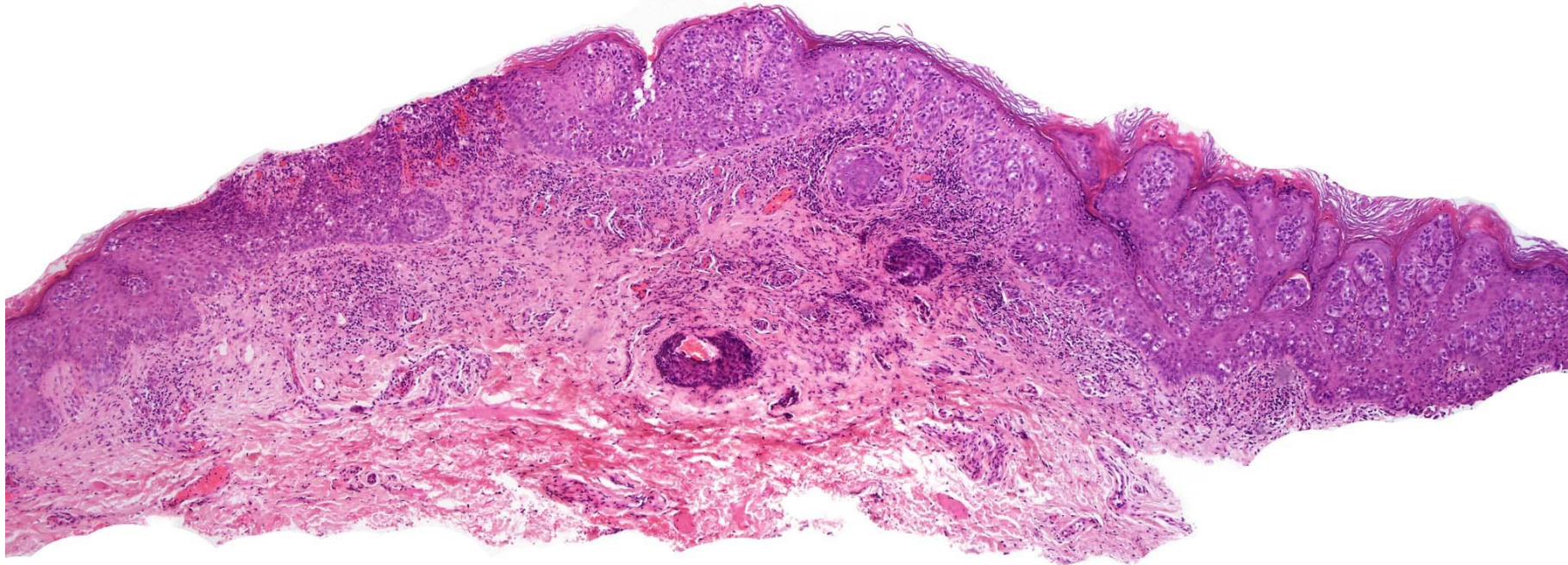
- The best diagnosis is:

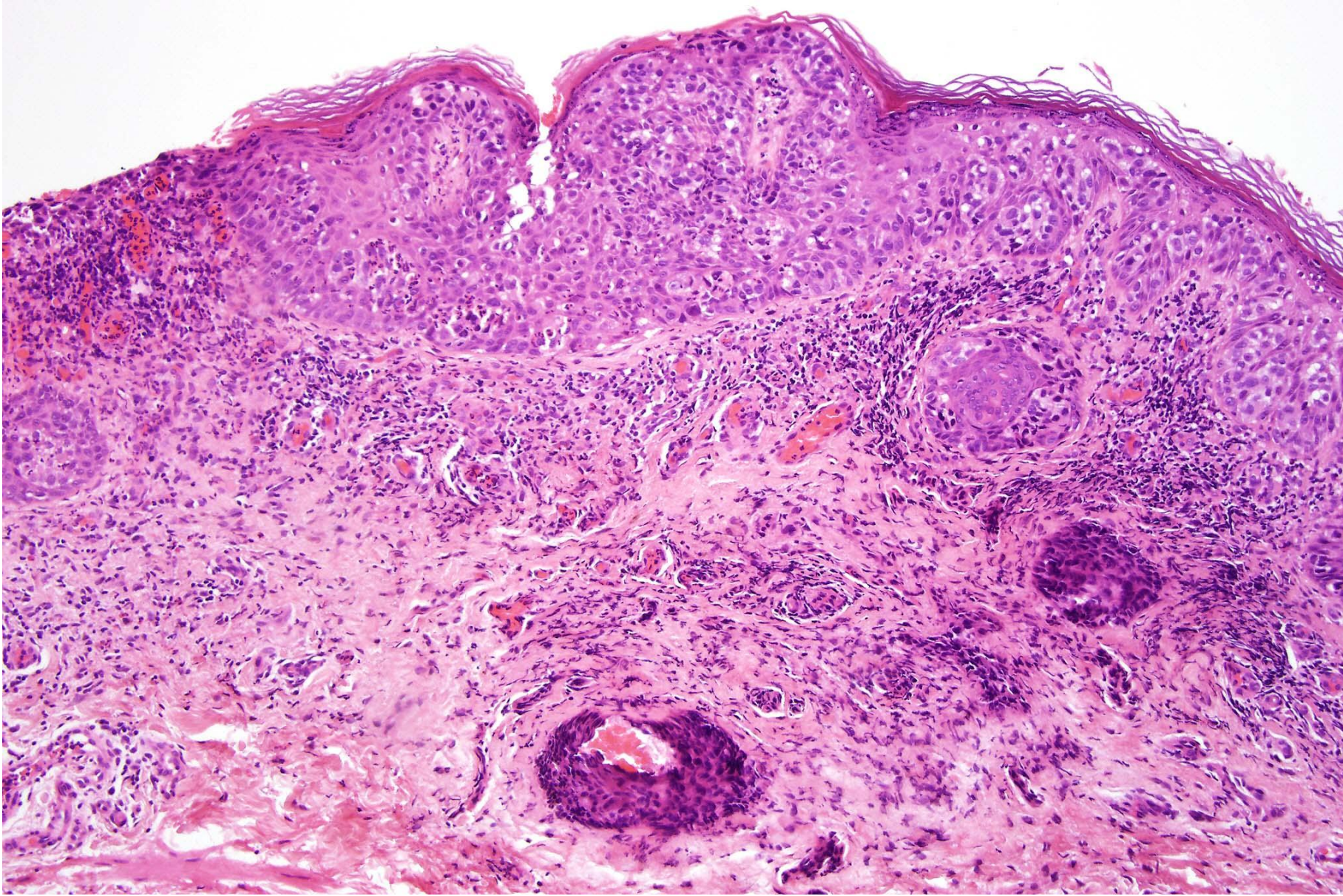
D. Pigmented extramammary Paget's disease

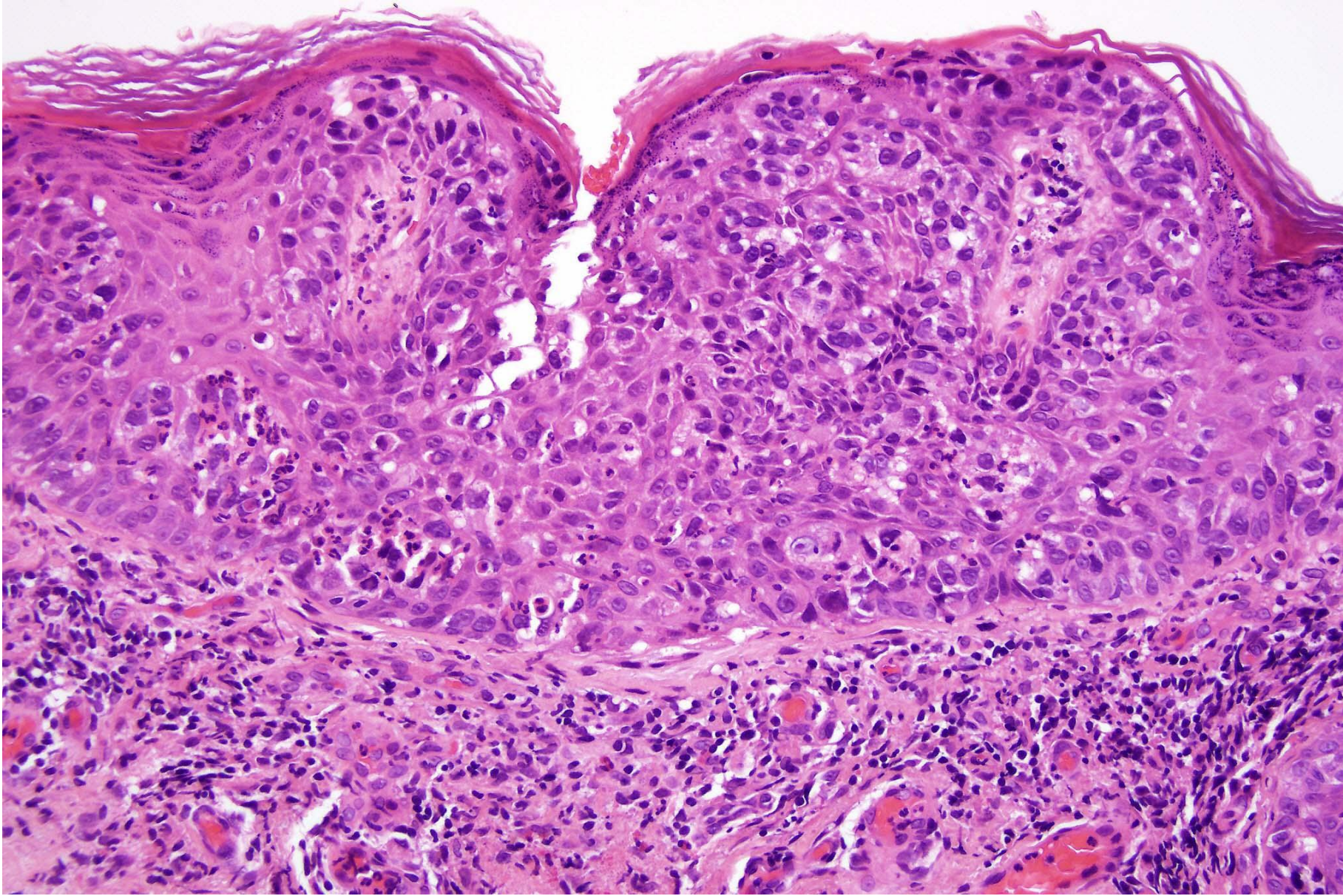
Pagetoid Lesions Cytologically Malignant

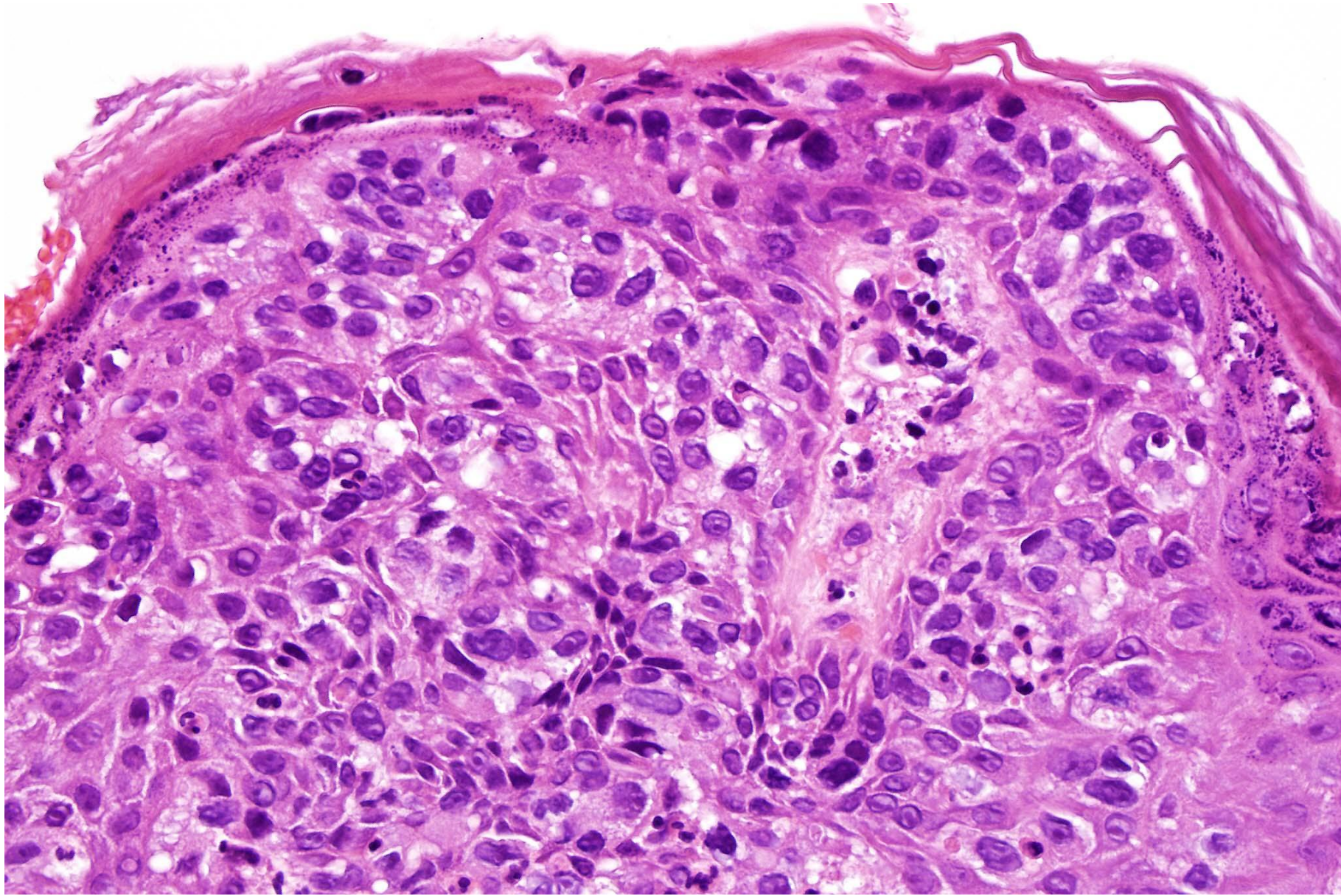


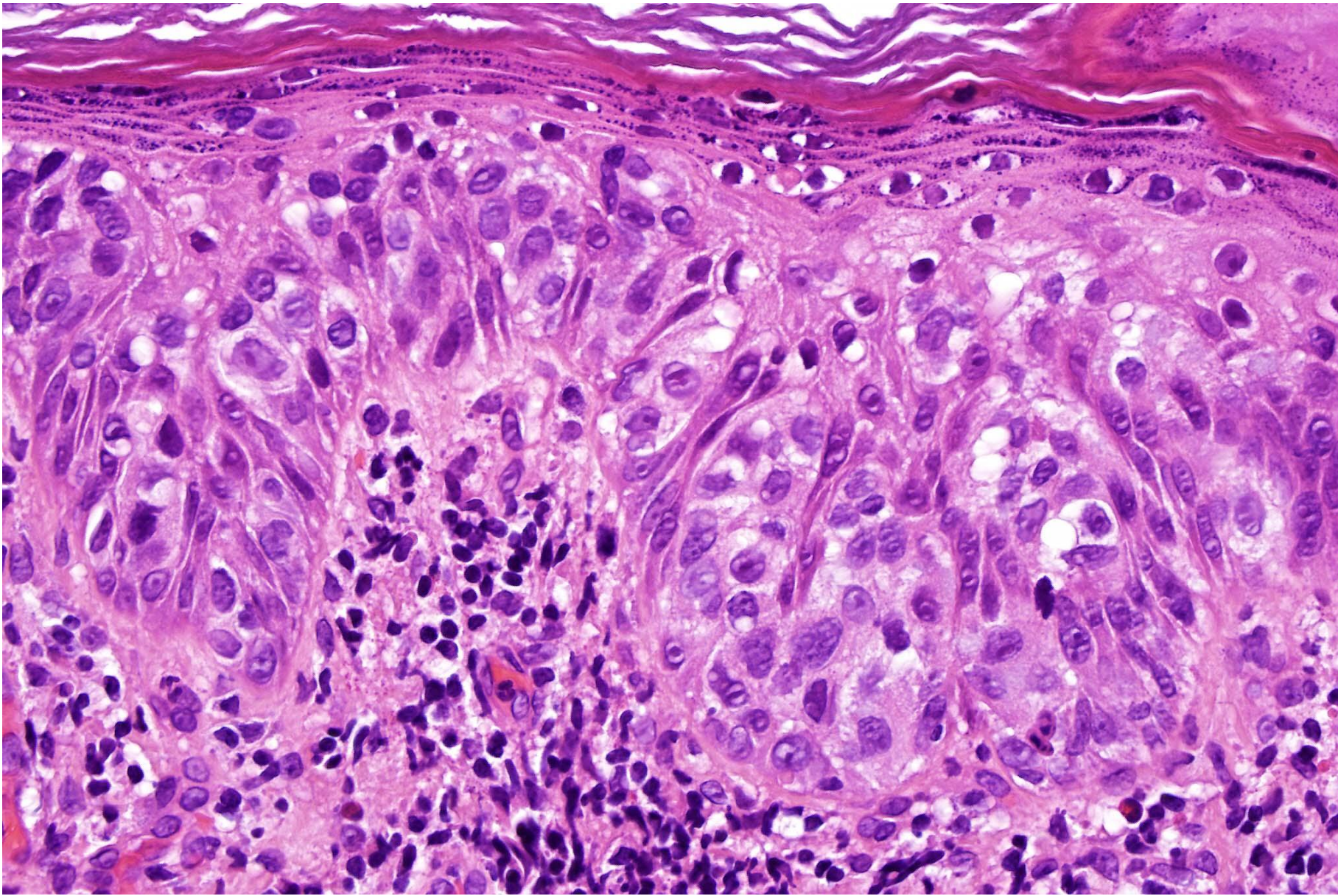


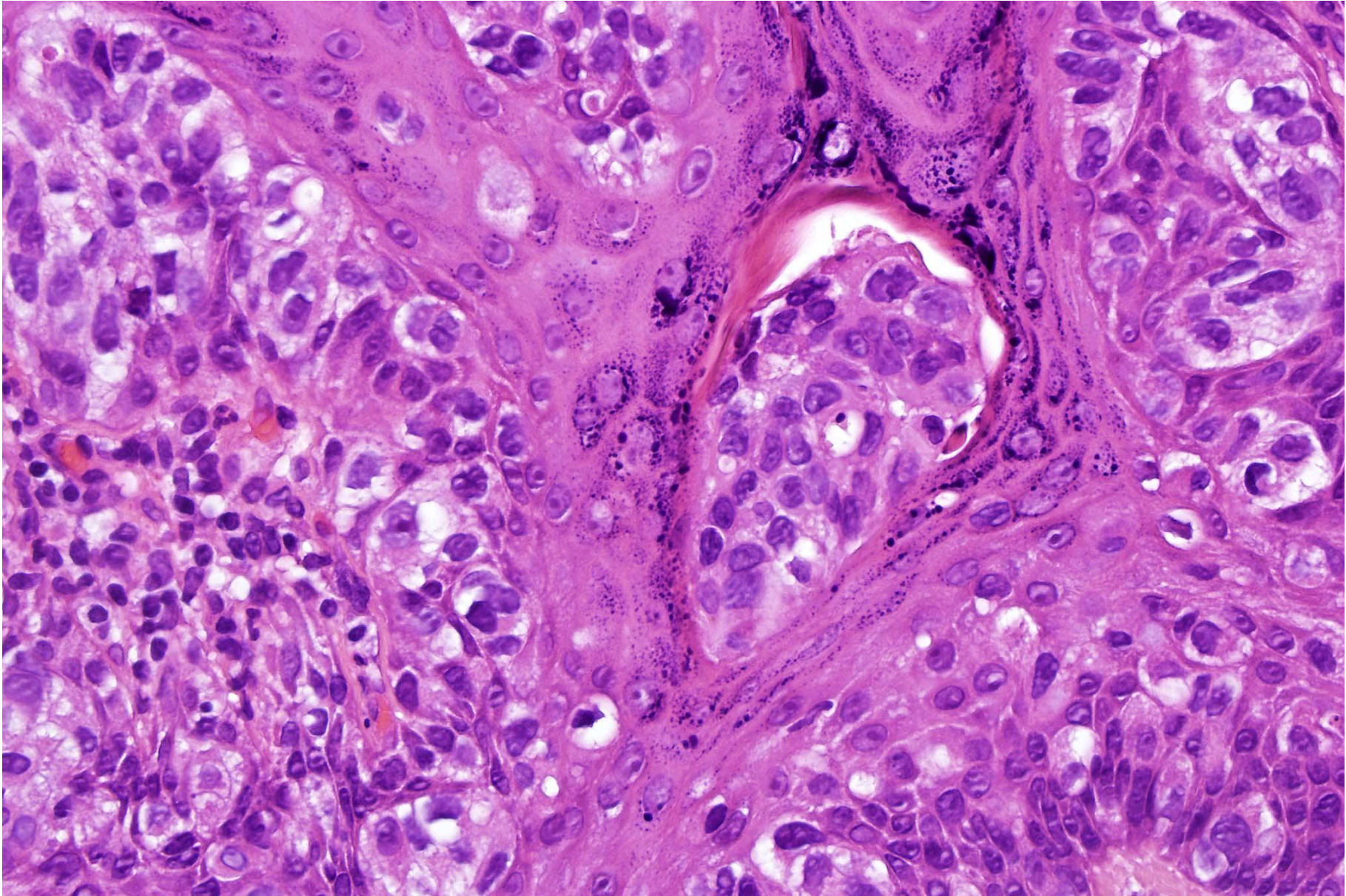


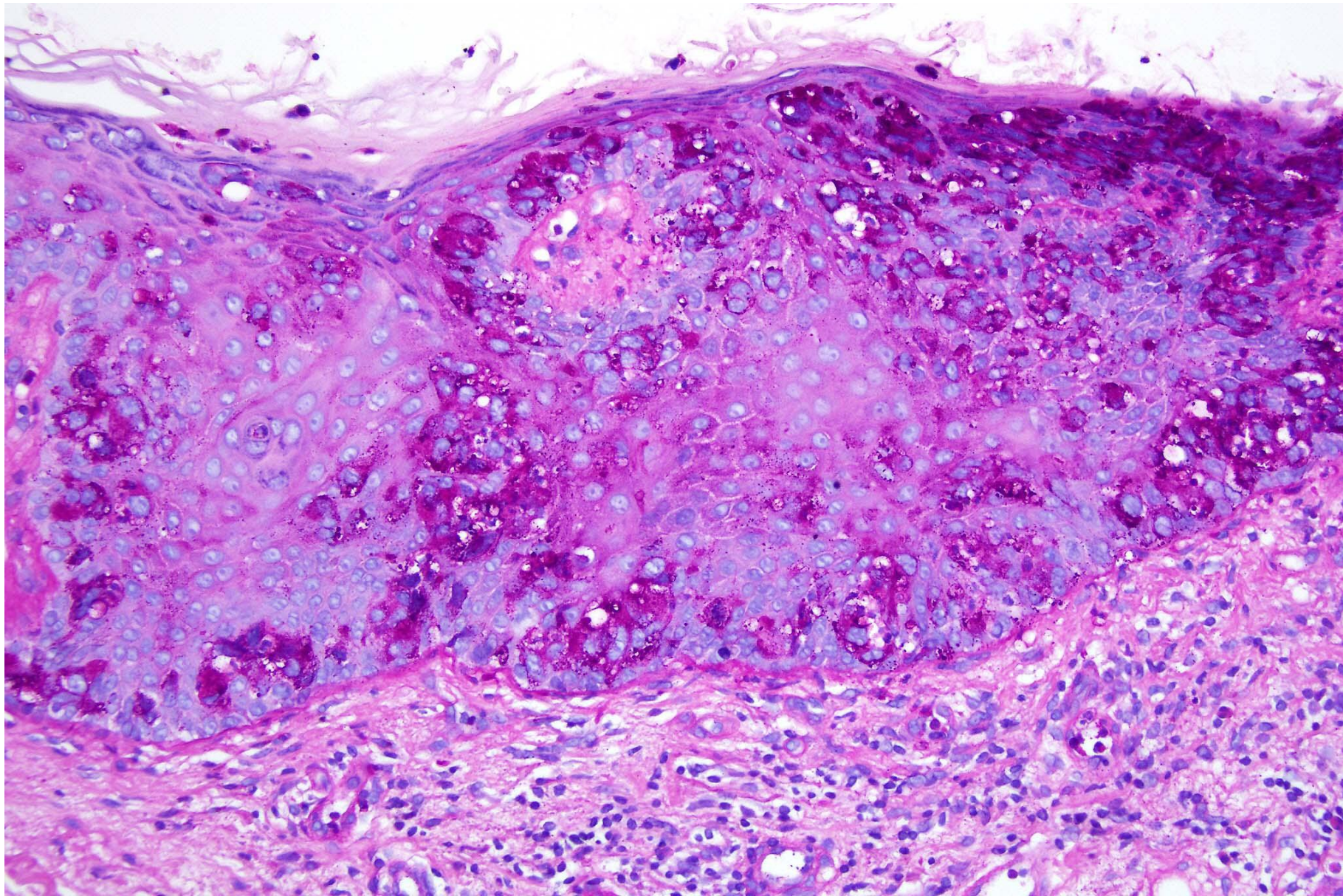


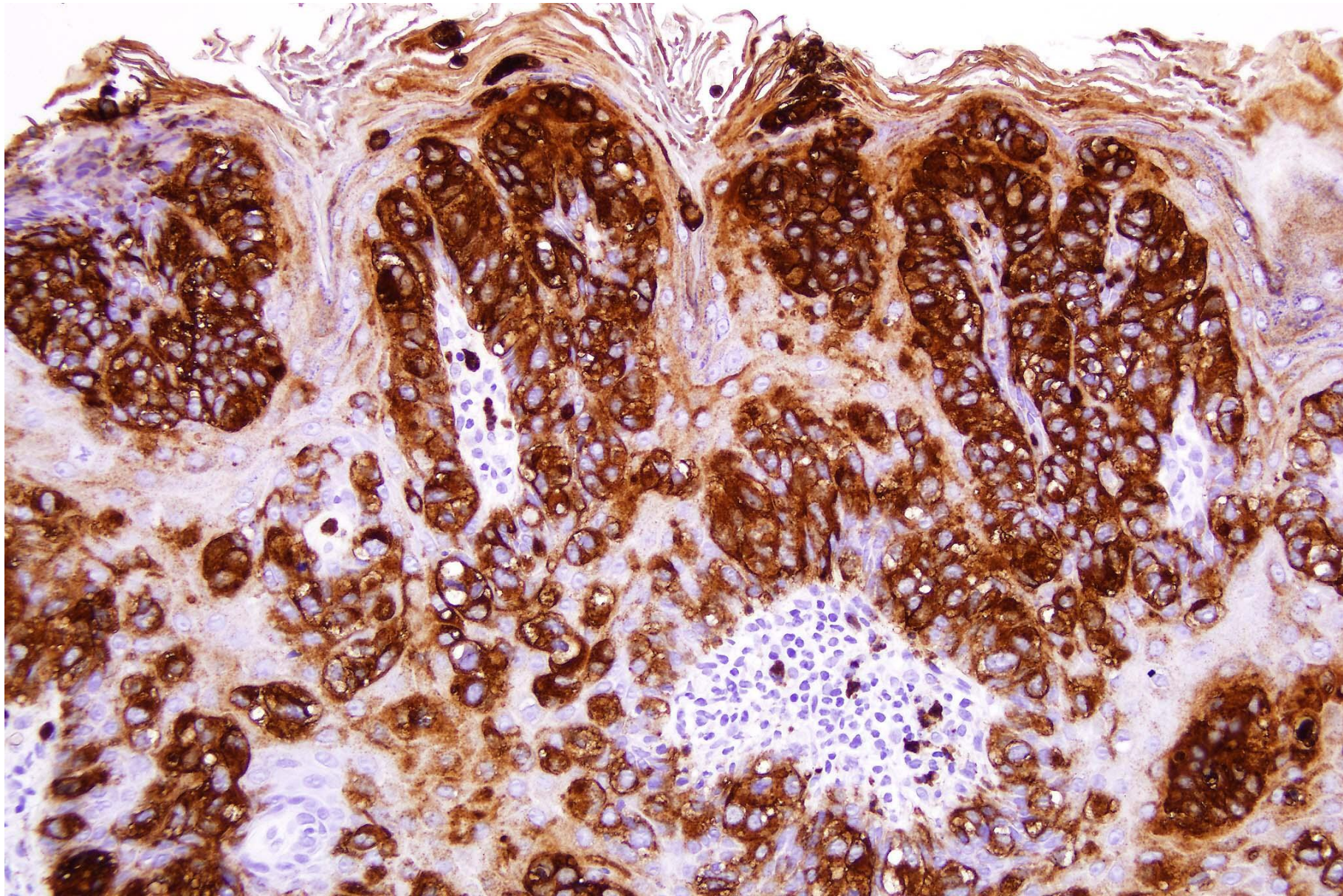


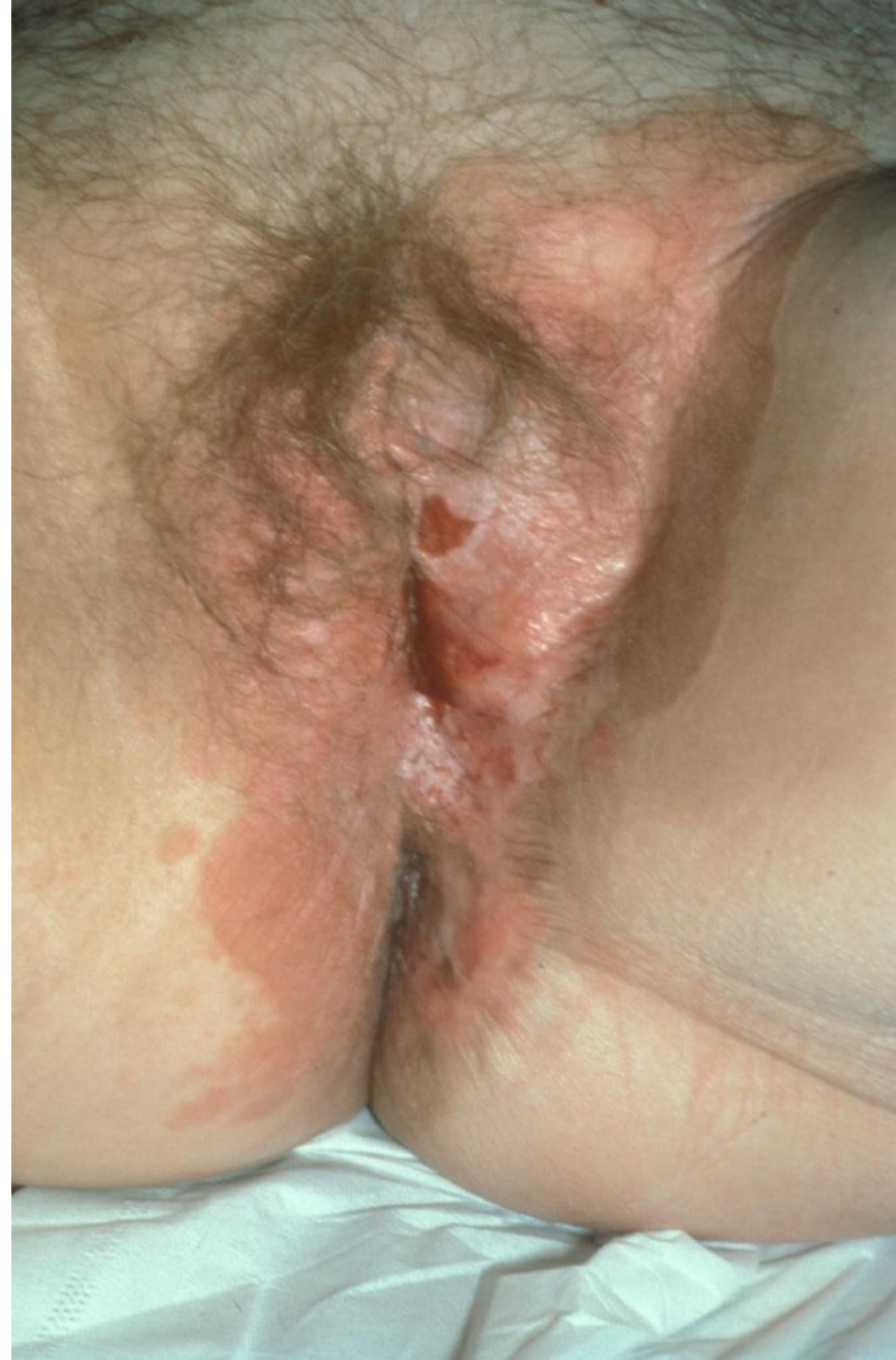


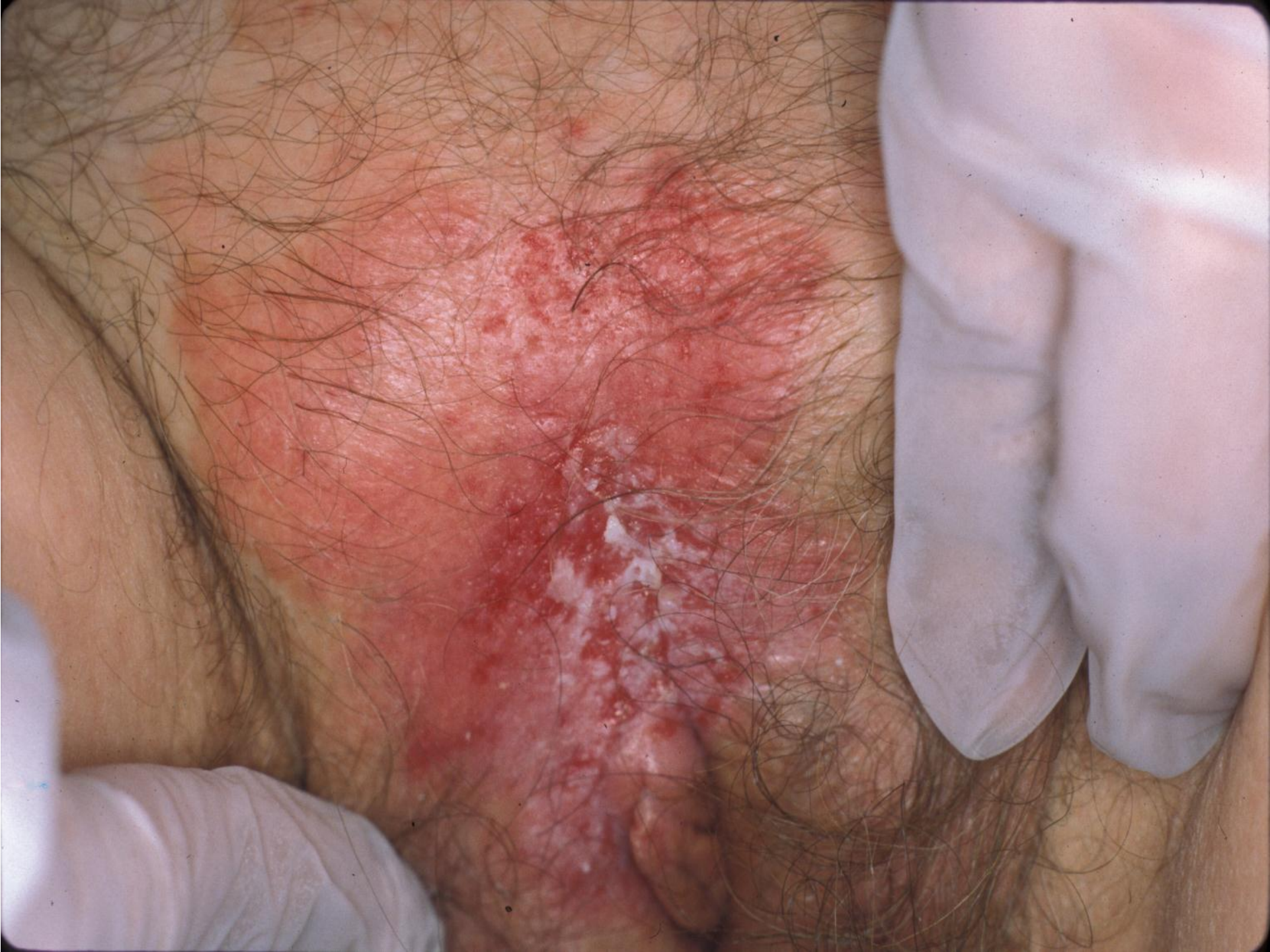


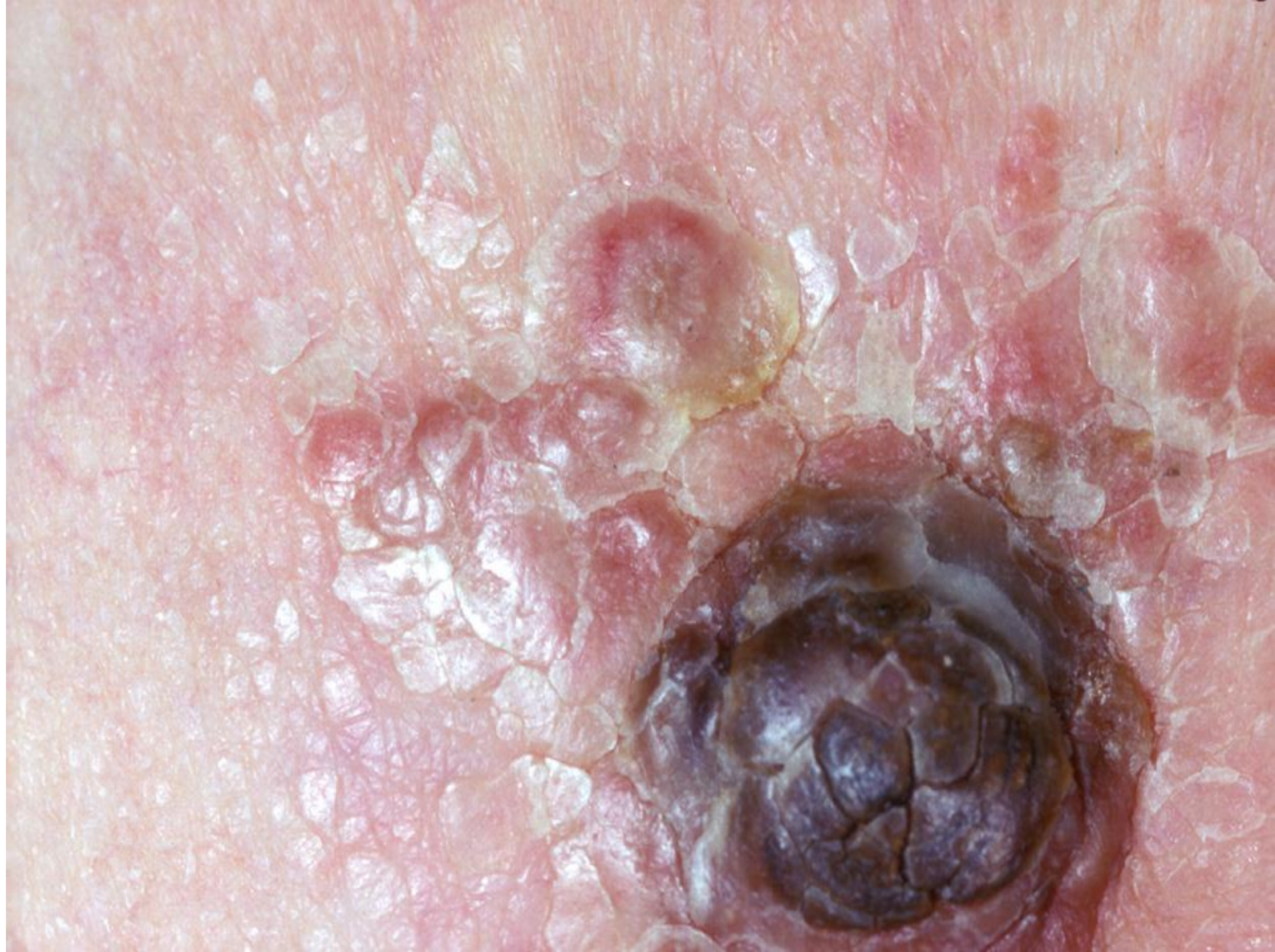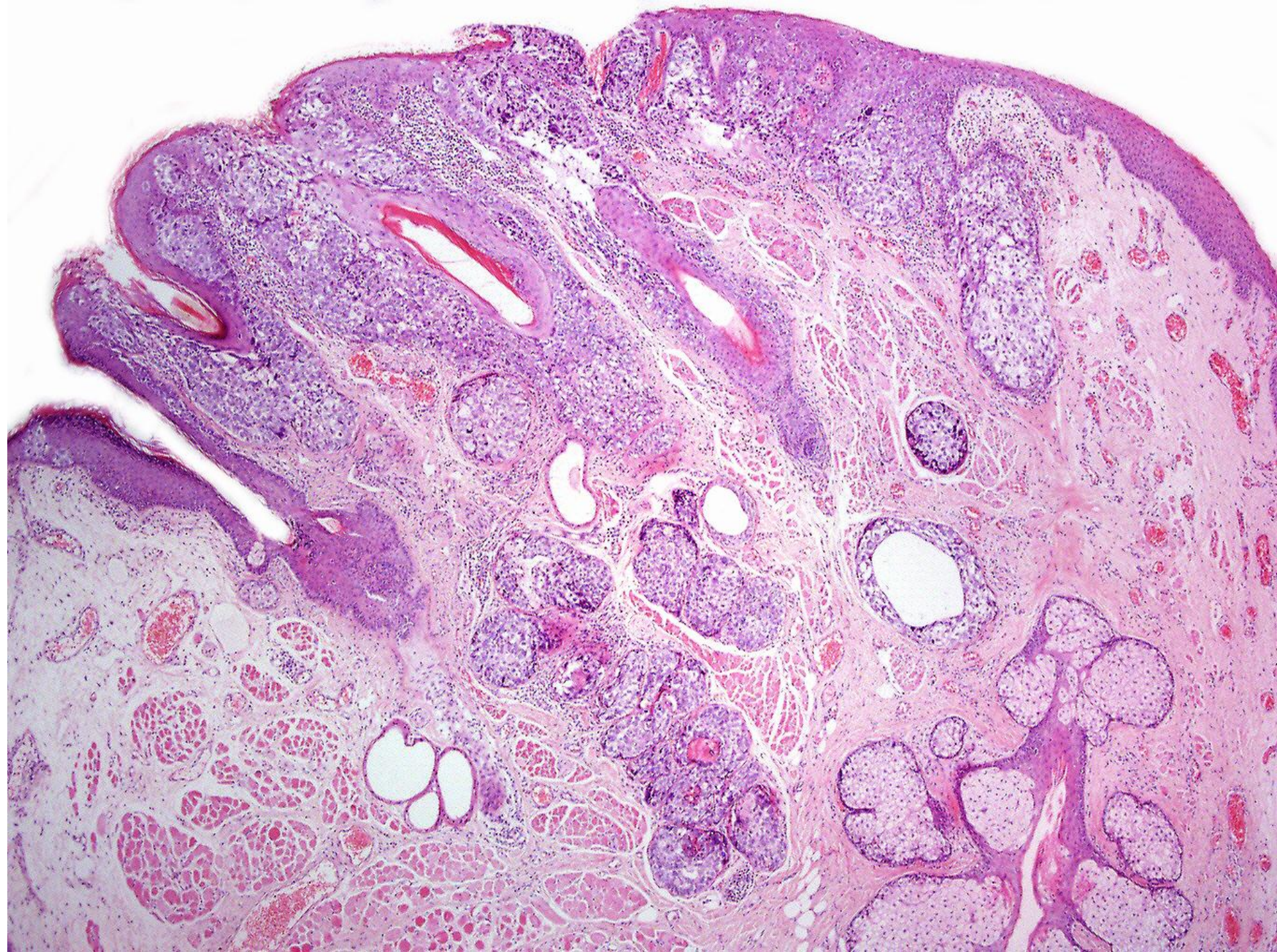


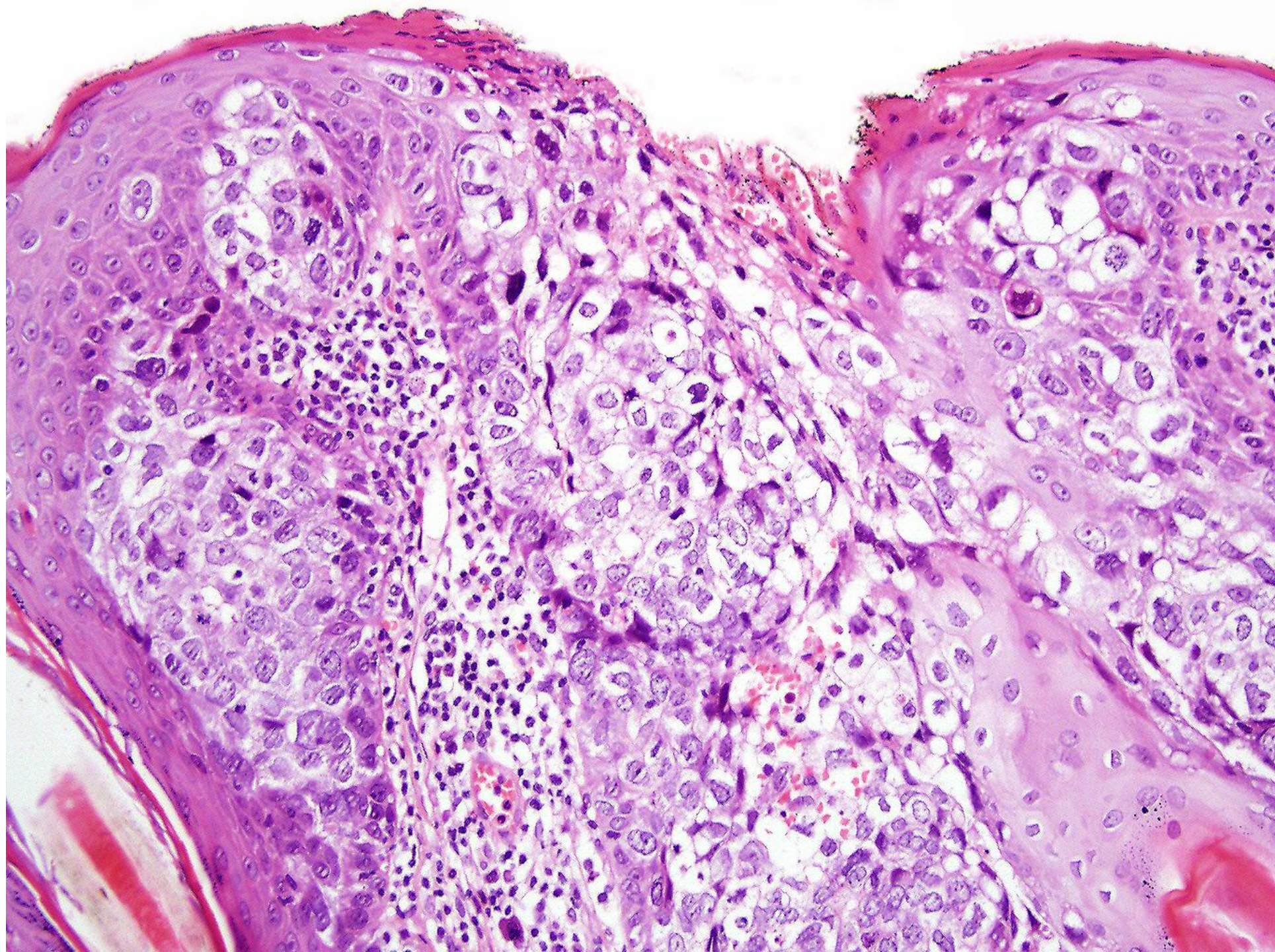


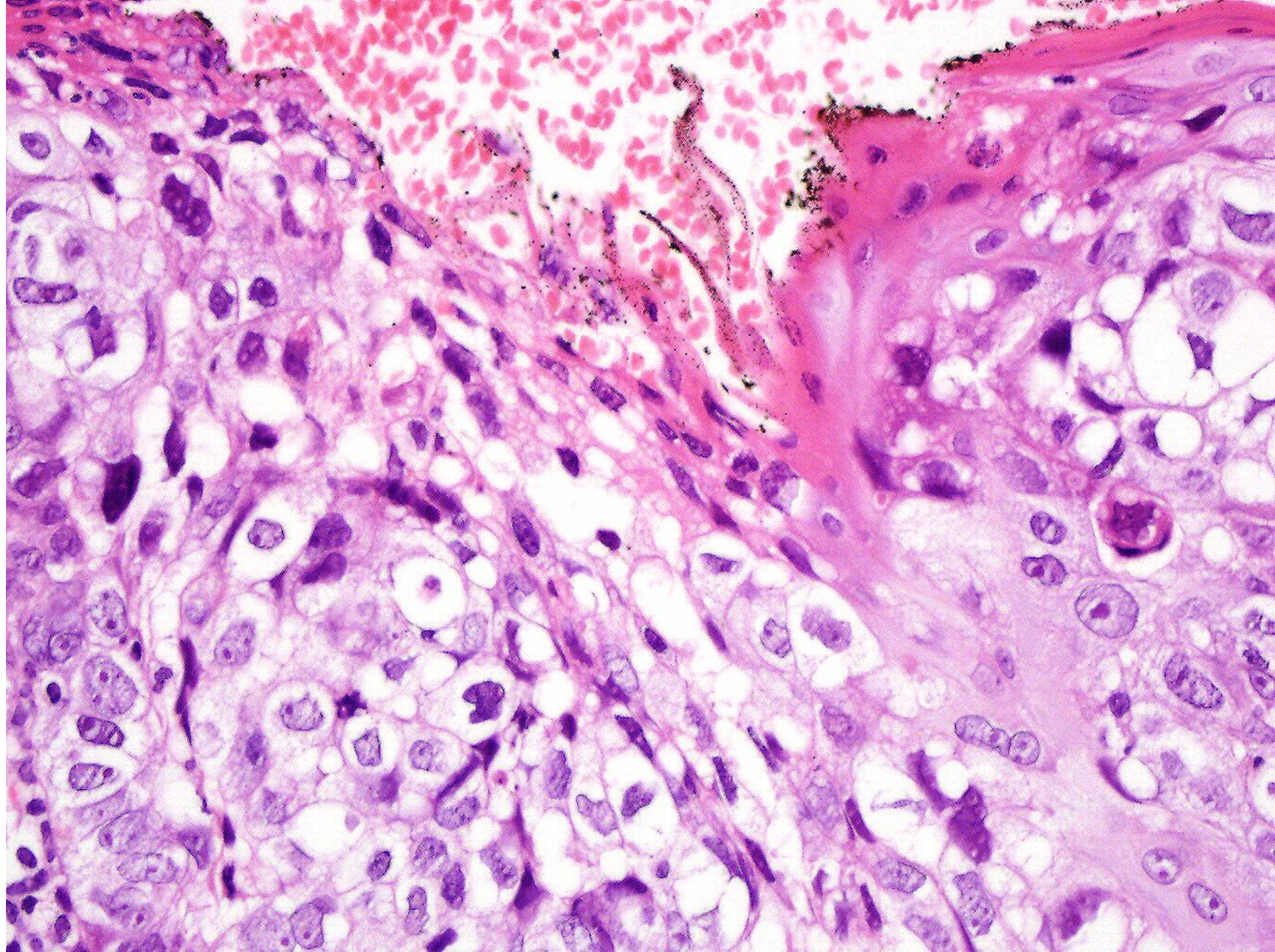


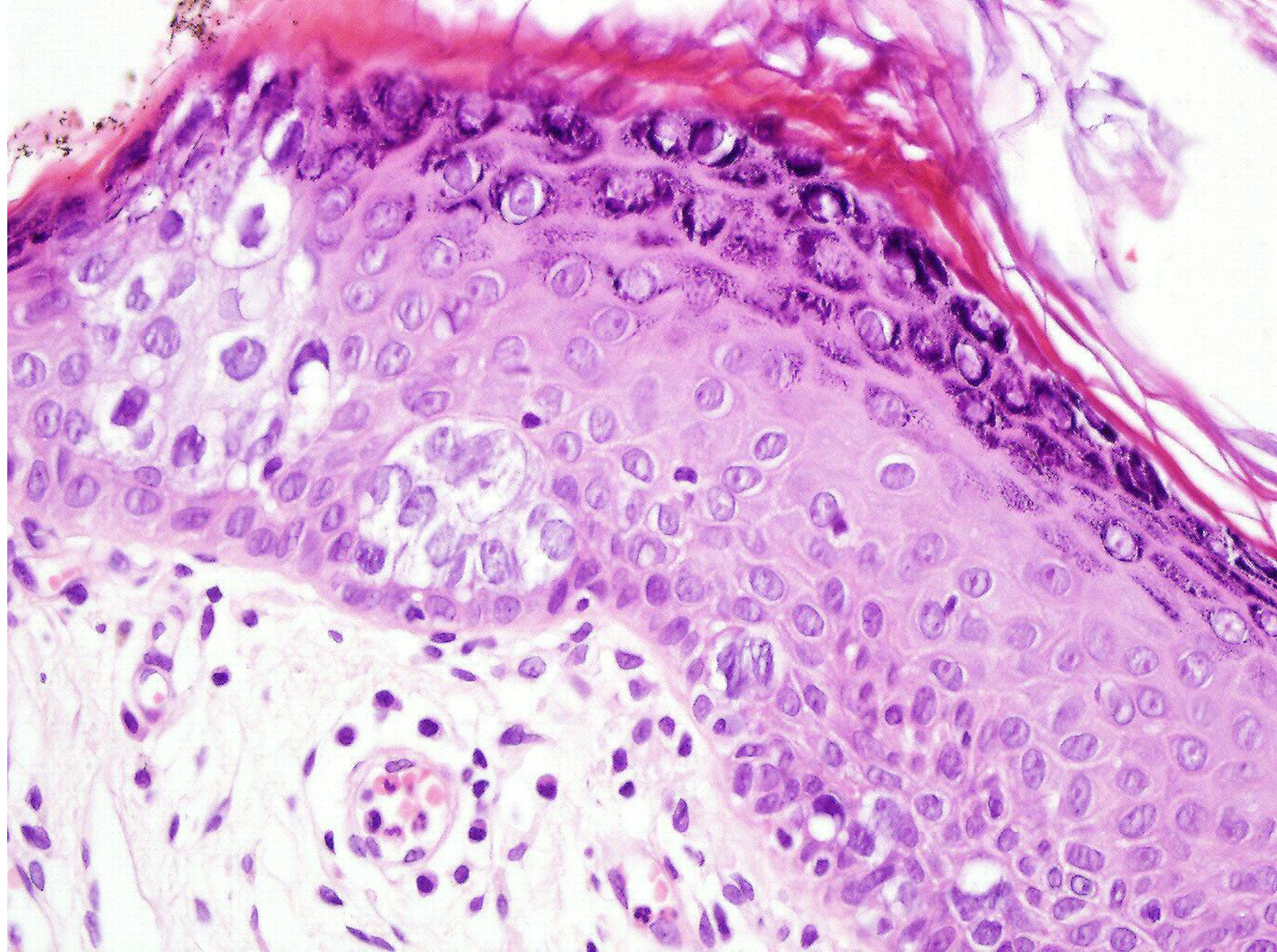


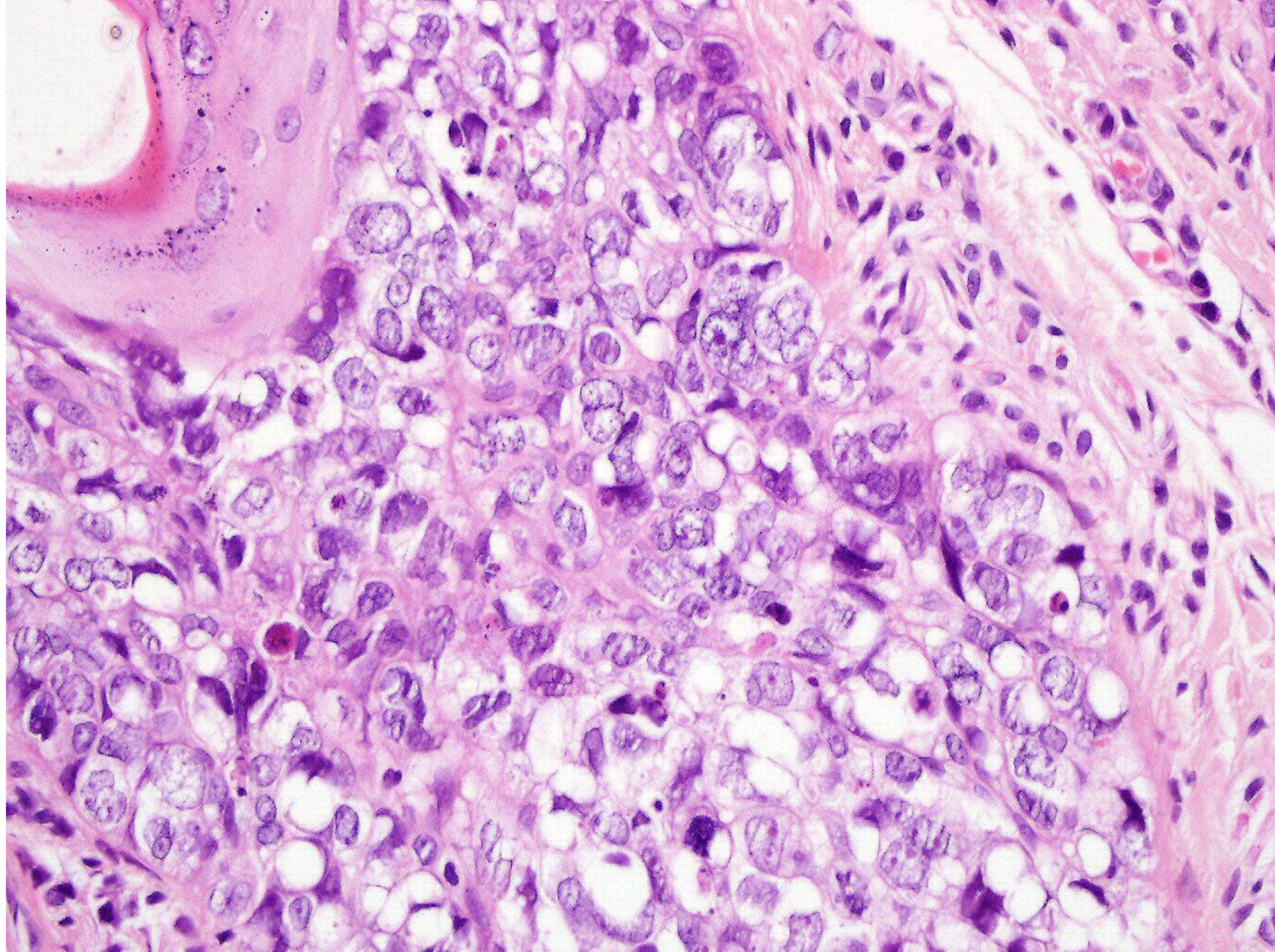


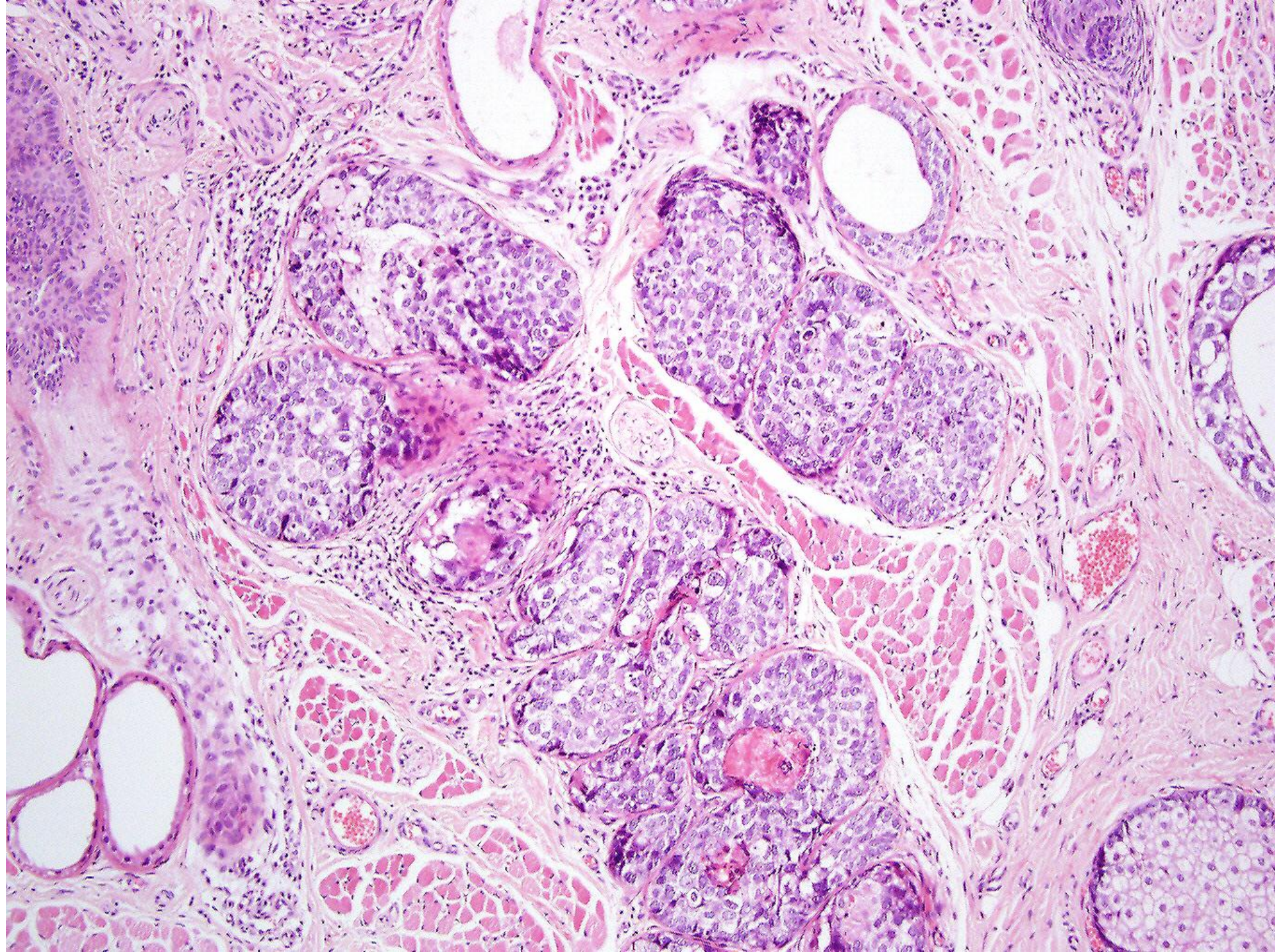






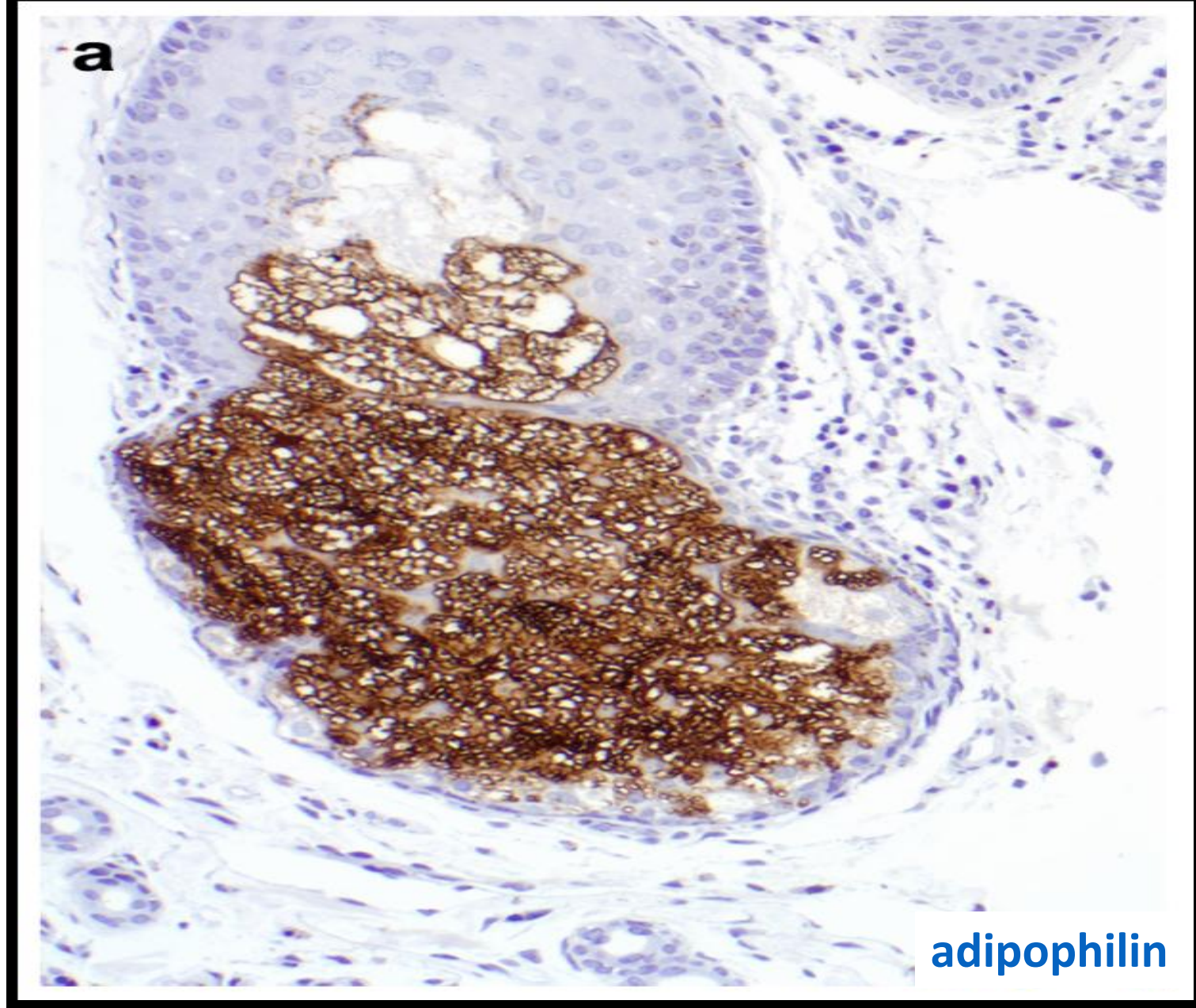






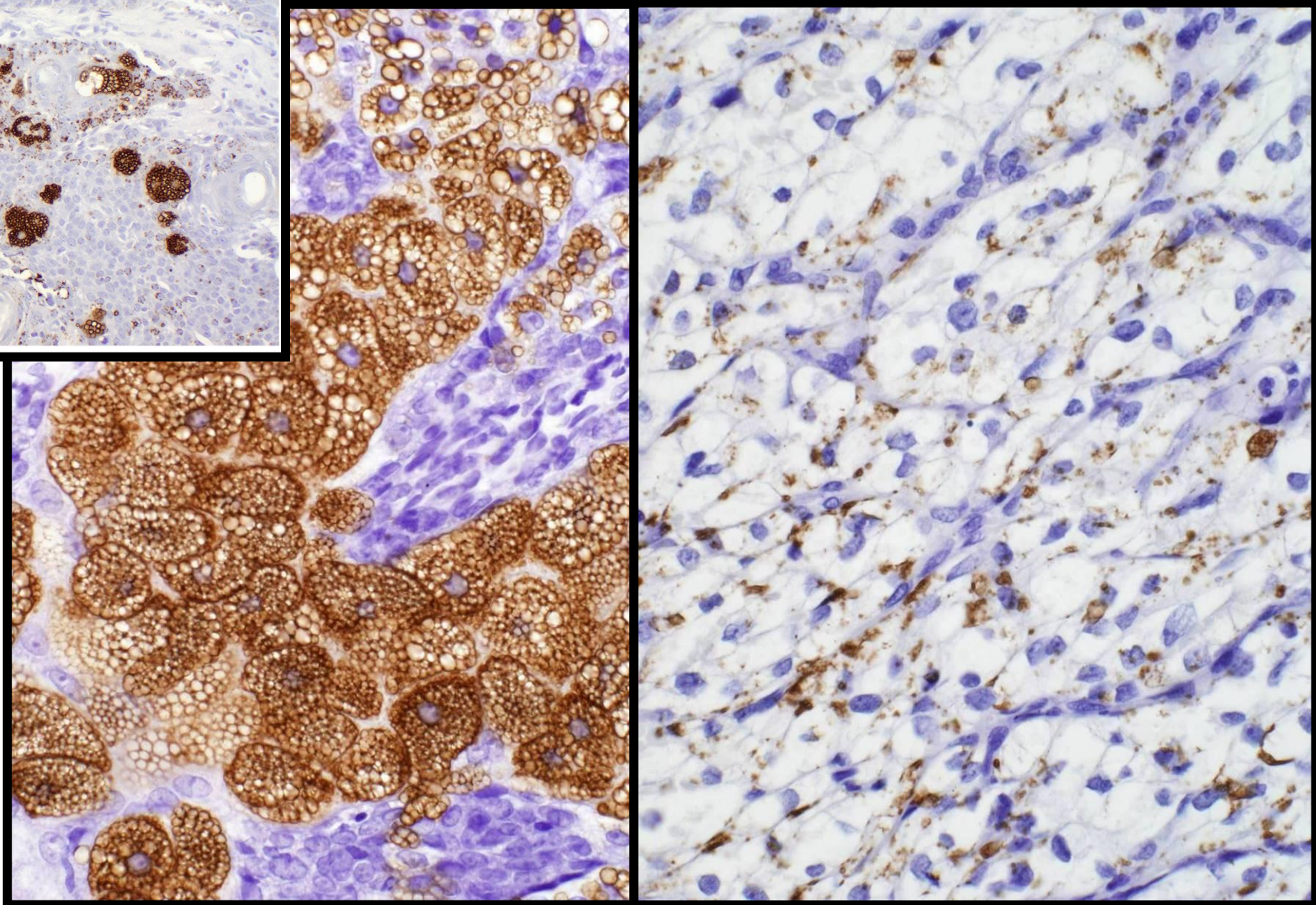
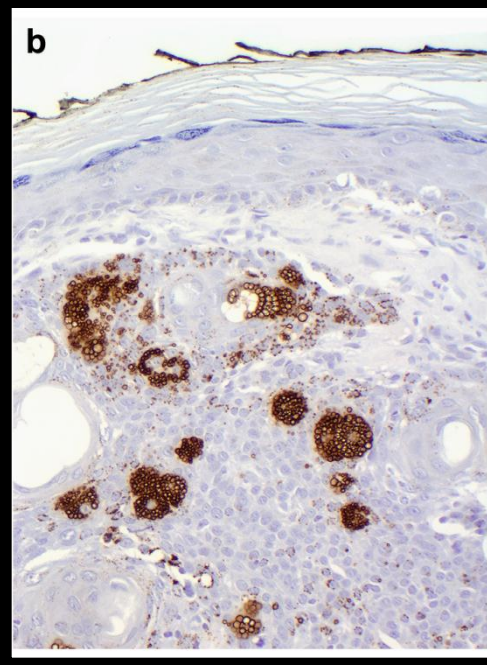
Sebaceous Immunohistochemistry

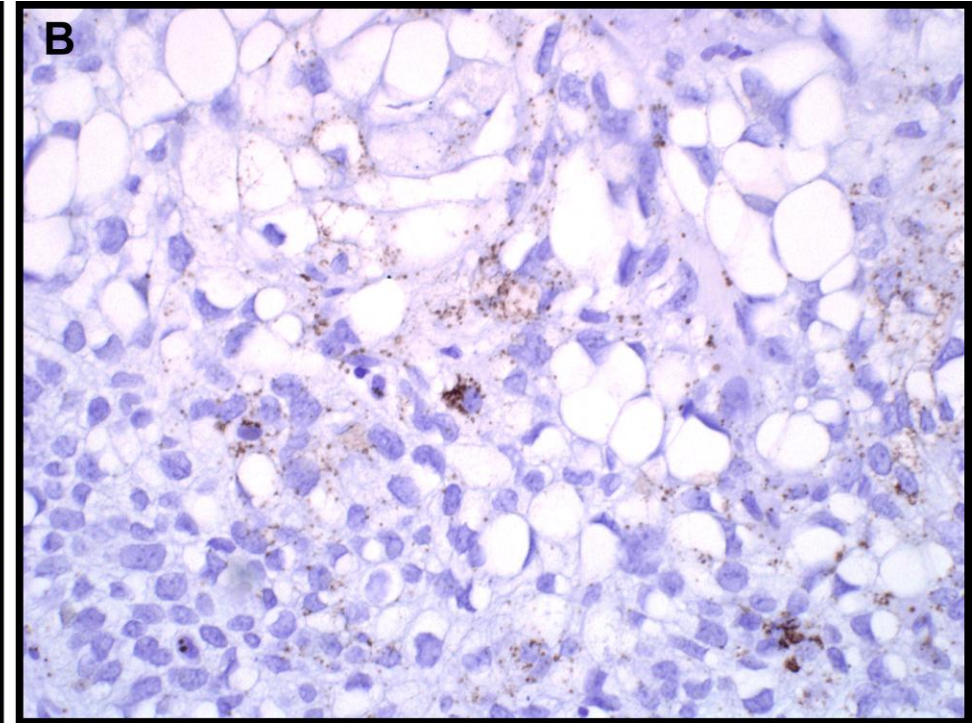
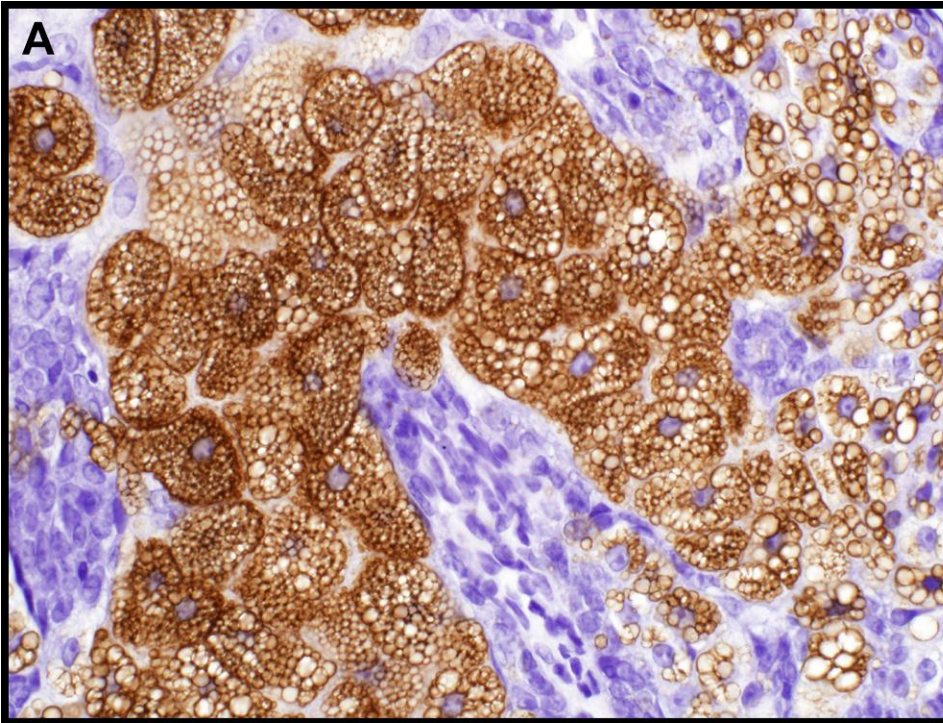
- Eosinophilic, bubbly cytoplasm
- Crenylated, indented nuclei
- Fresh tissue: Oil Red O
- EMA(+), CEA(-)
- CK7(+), BerEP4(-)
- New: adipophilin, perilipin, and TIP-47



**COURTESY OF DR ALEX LAZAR, MD ANDERSON CANCER
CENTER, HOUSTON**

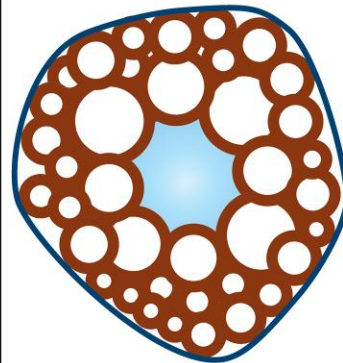
Adipophilin



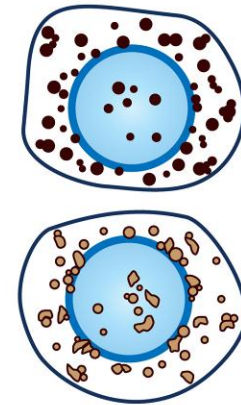


C

**Vesicular membranous staining:
intracytoplasmic
lipid vesicles**



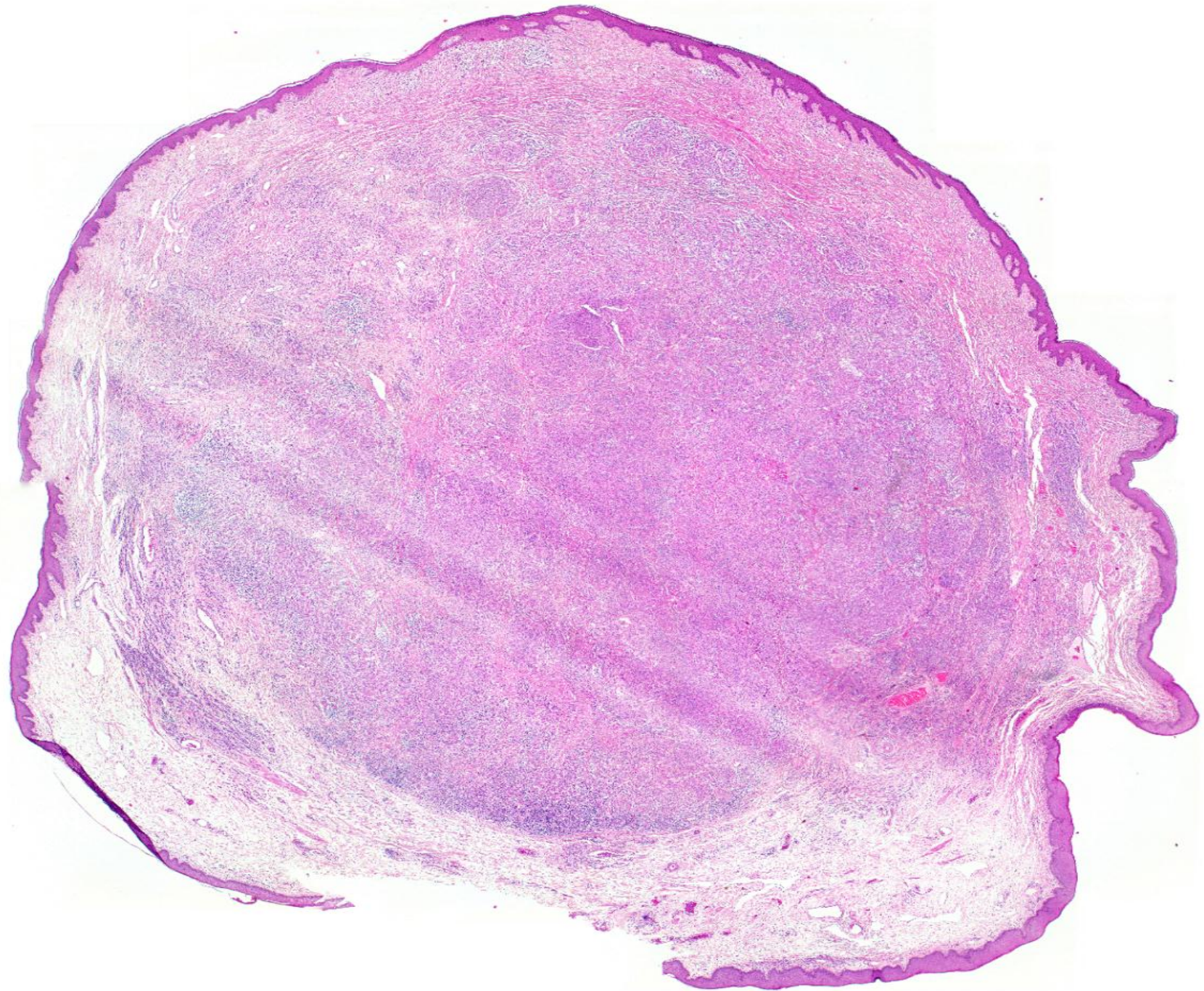
**Other staining patterns:
tumor cells, keratohyaline
granules, macrophages**

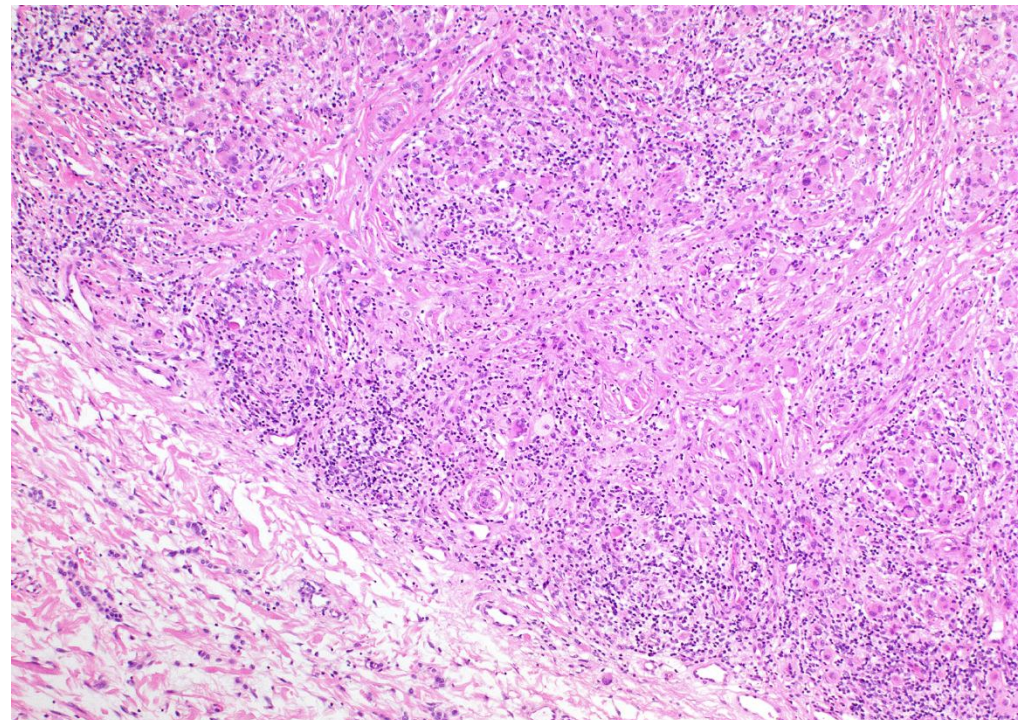
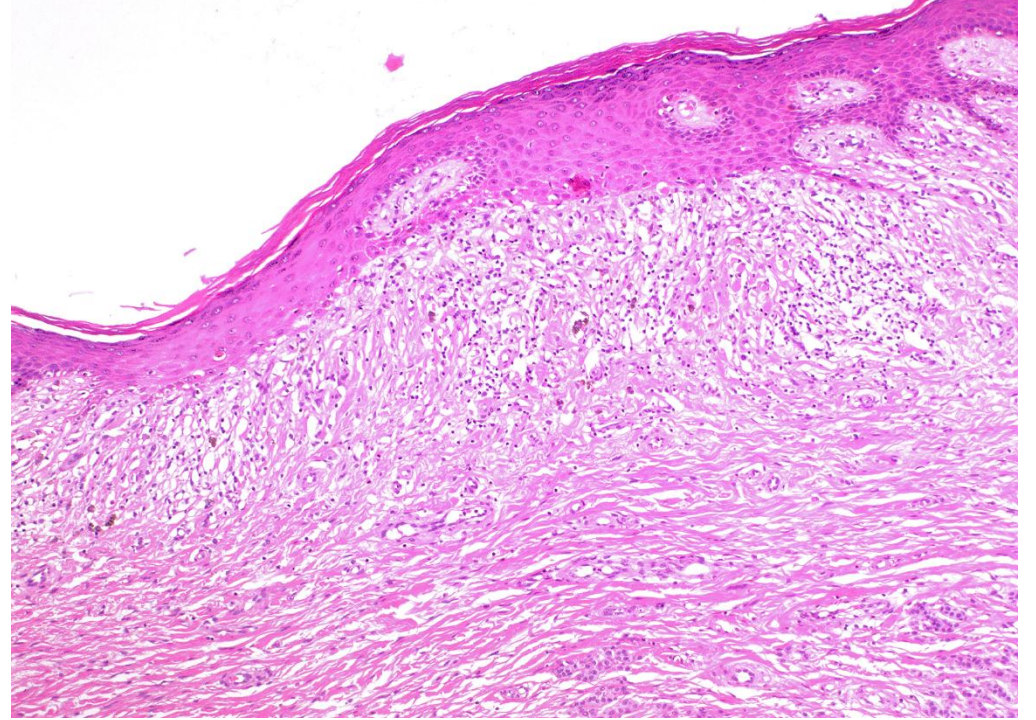
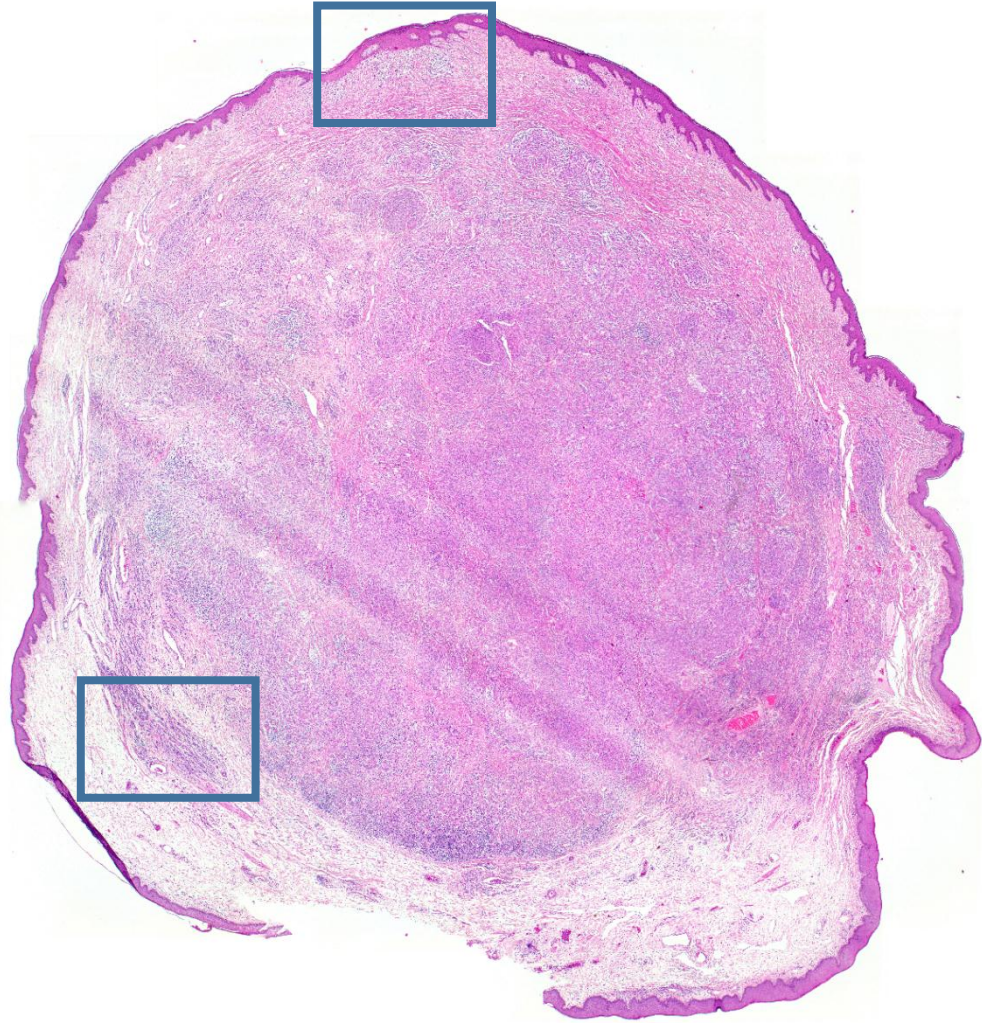


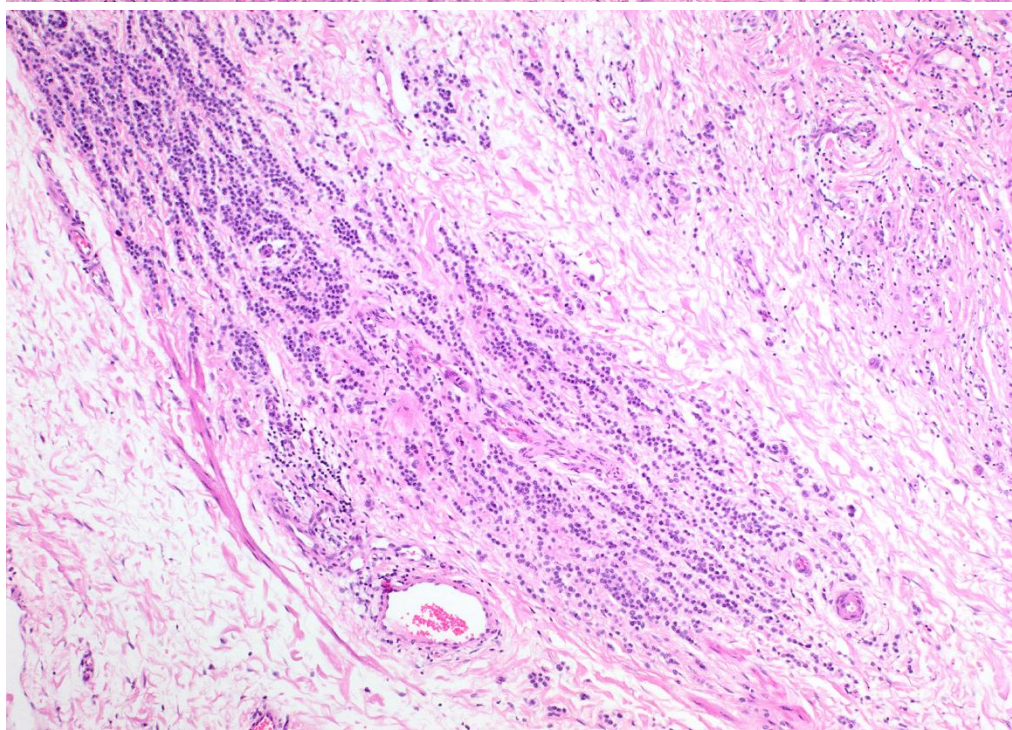
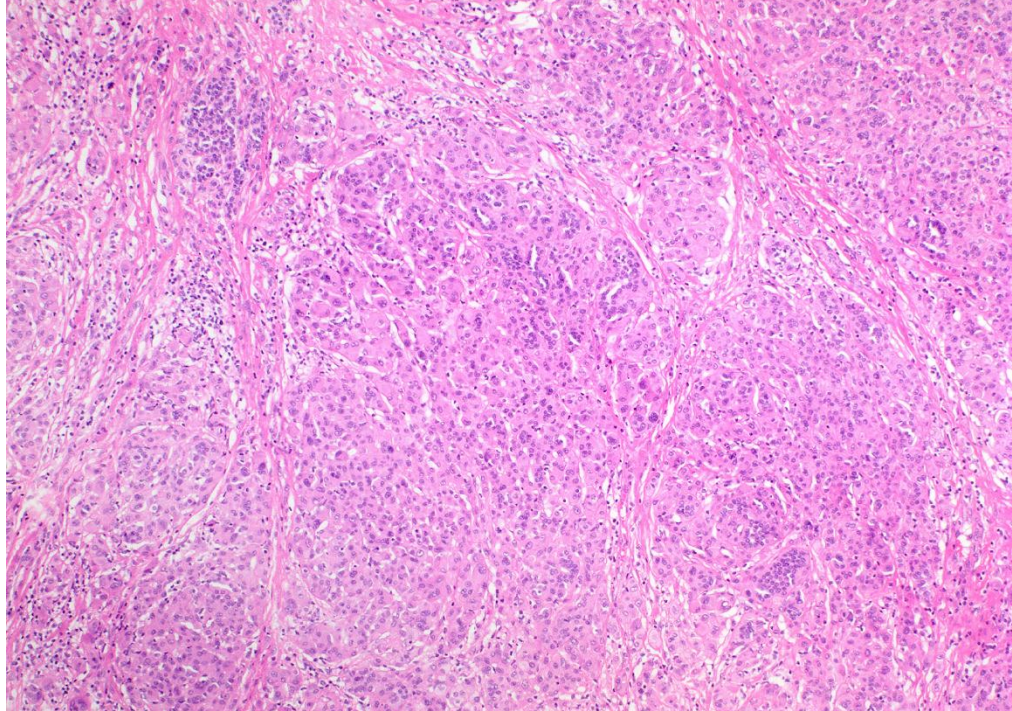
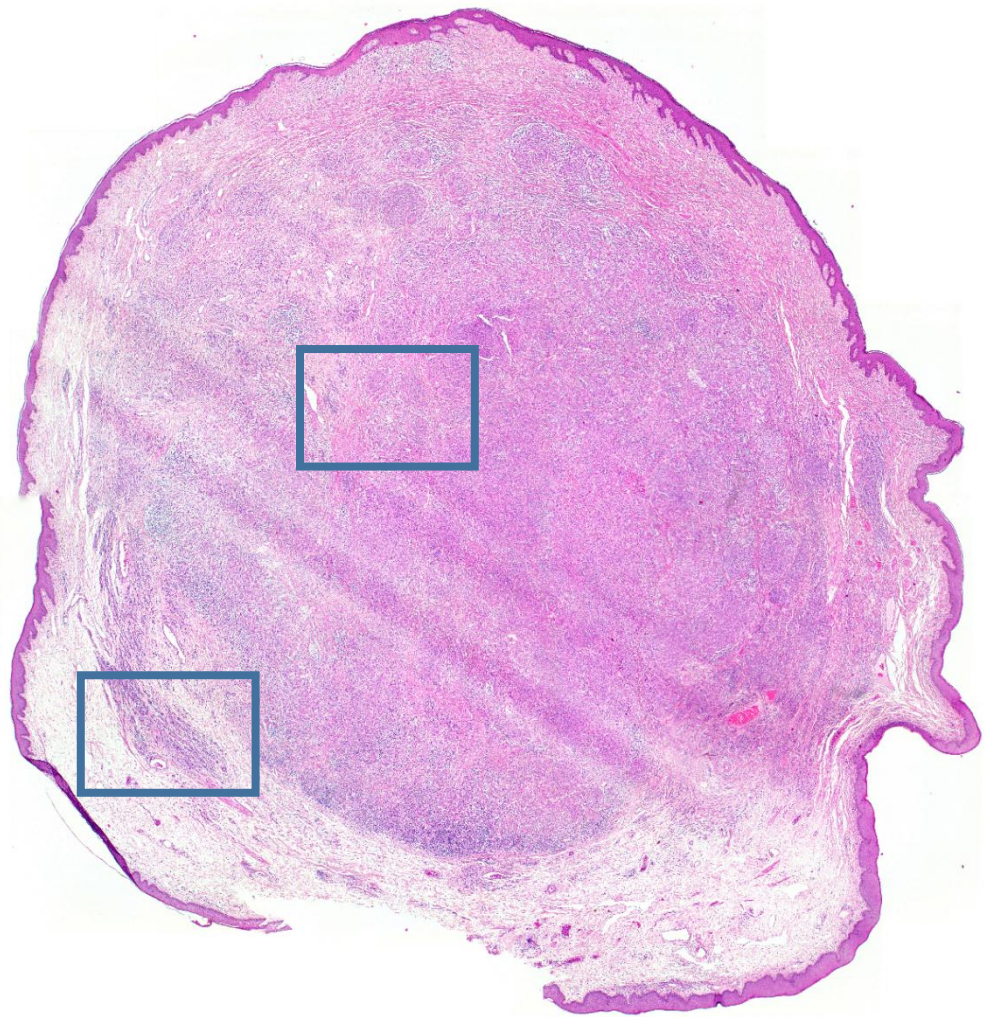
CLINICAL HISTORY

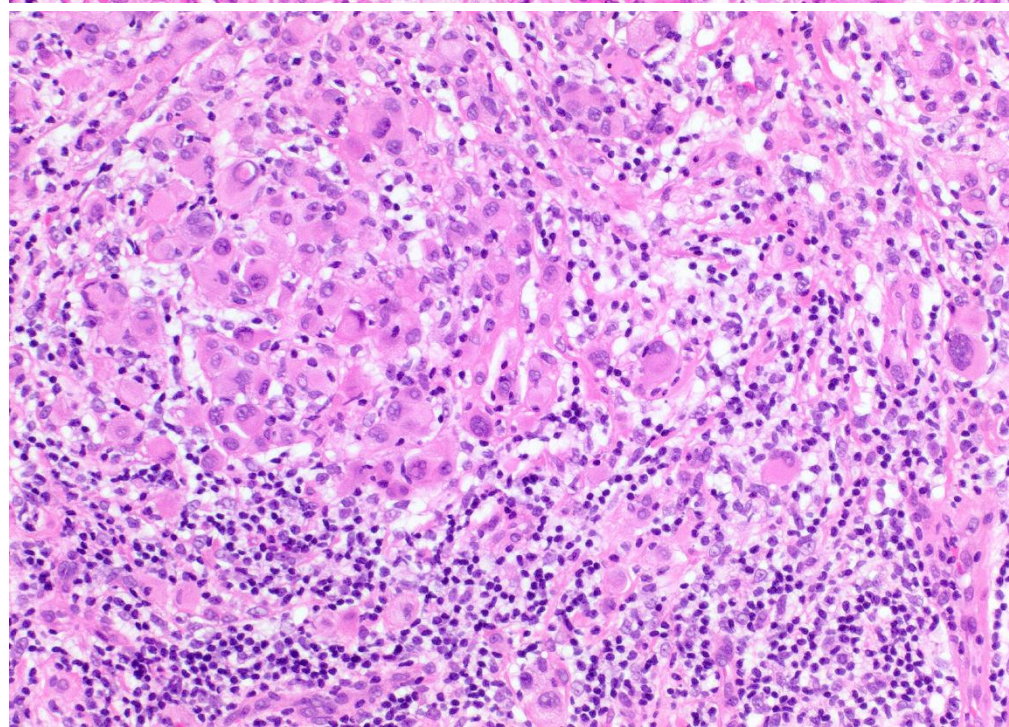
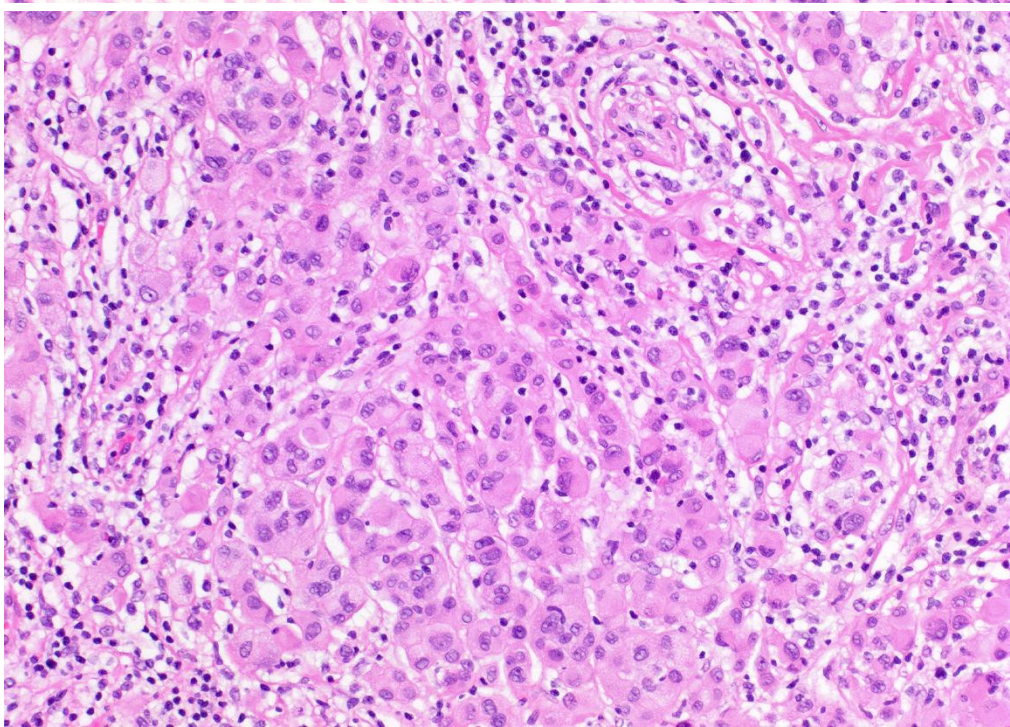
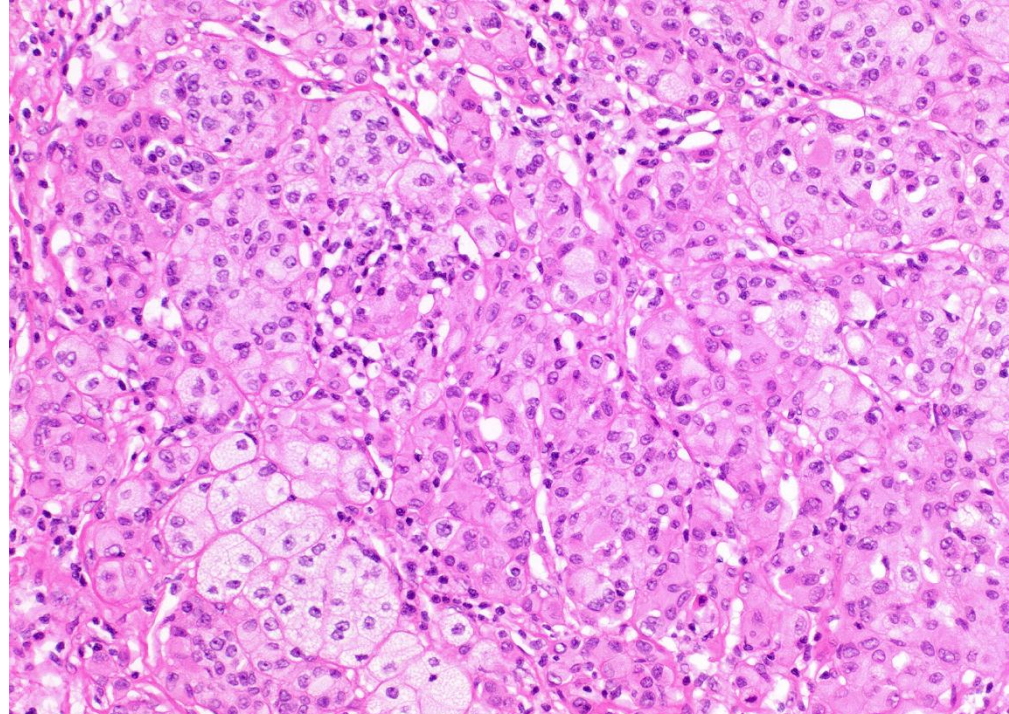
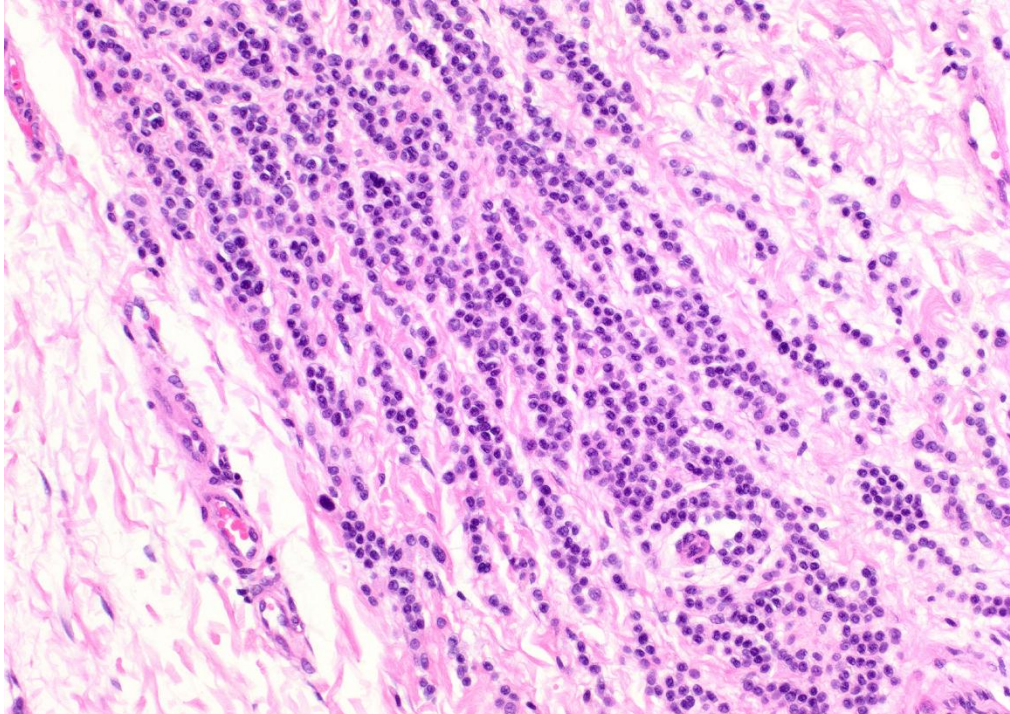
CASE 4

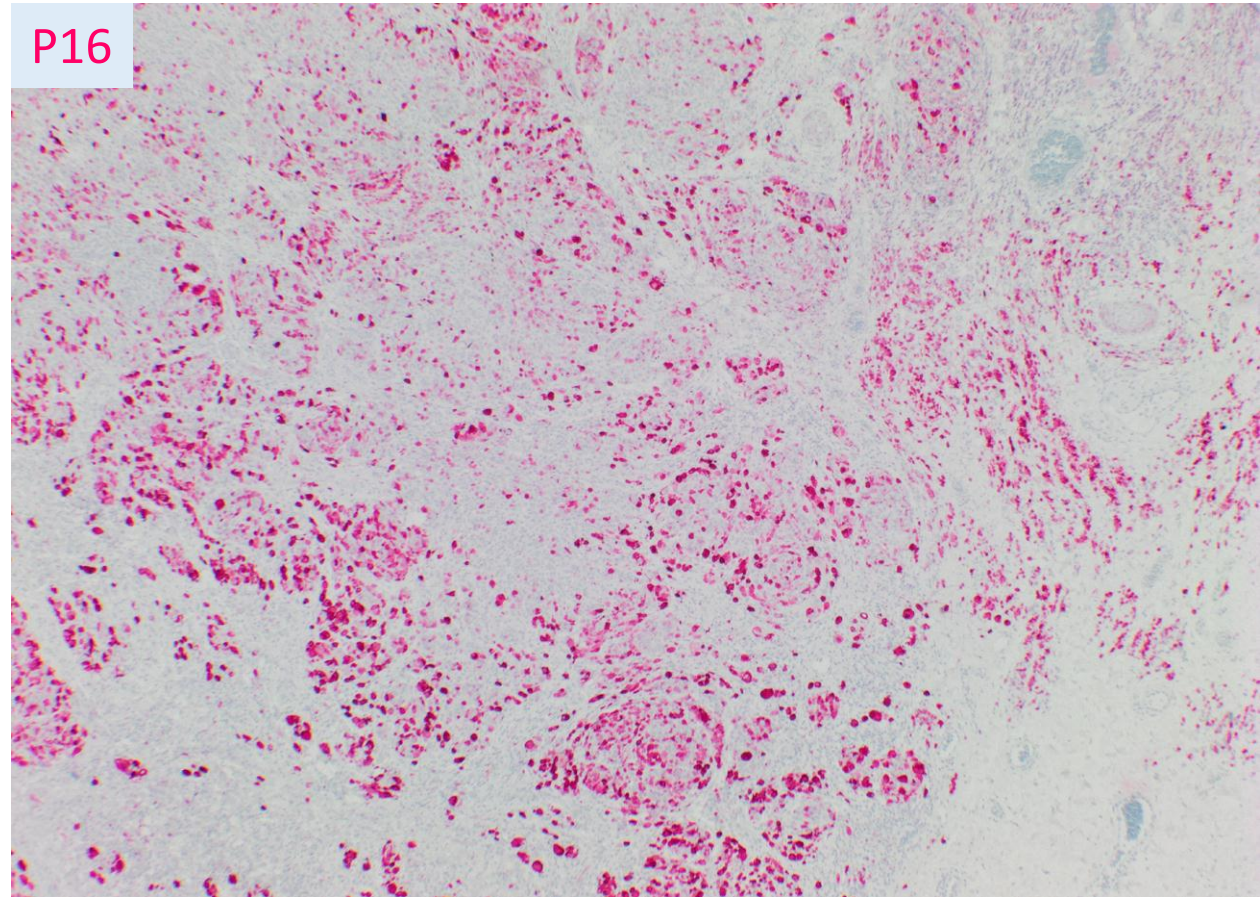
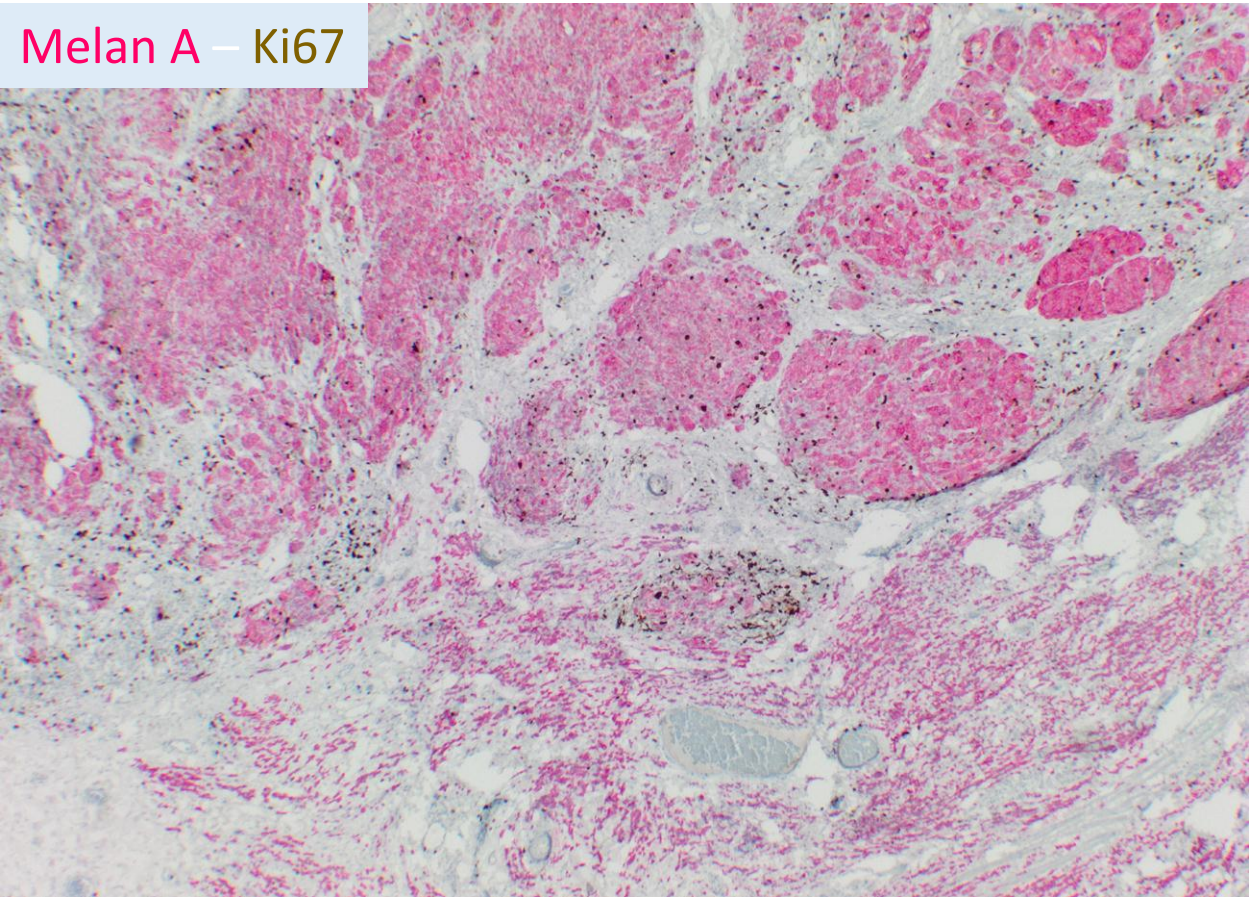
- Female, 22
- Skin tag-like lesion
- Right vulva
- ?Melanoma



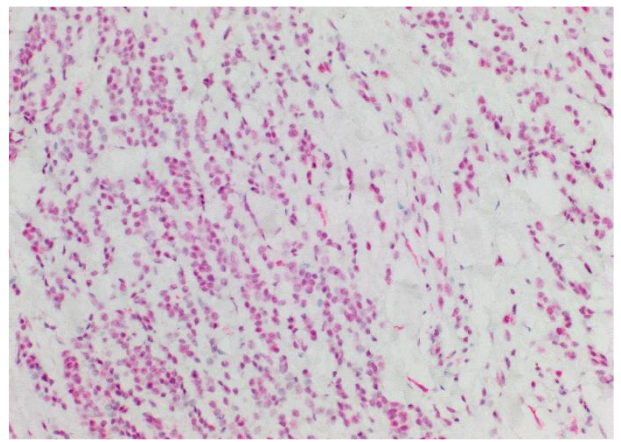
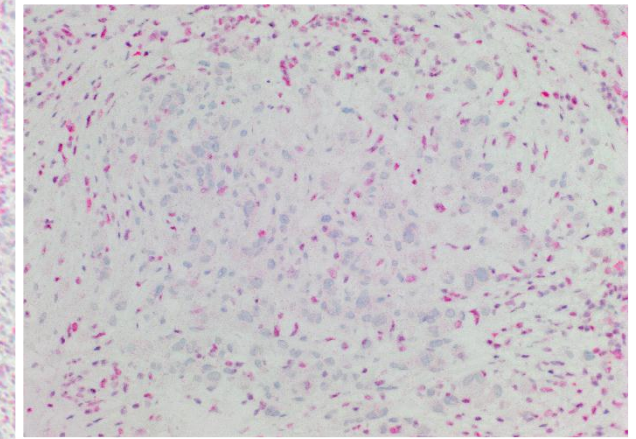
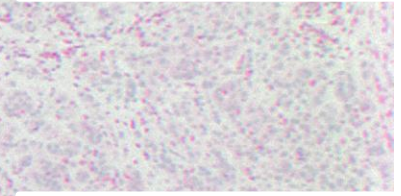
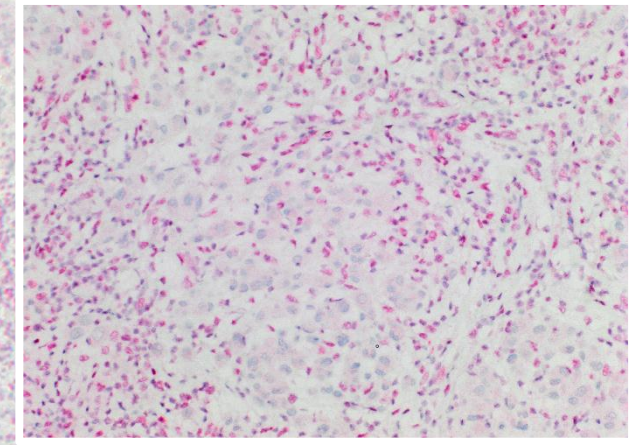
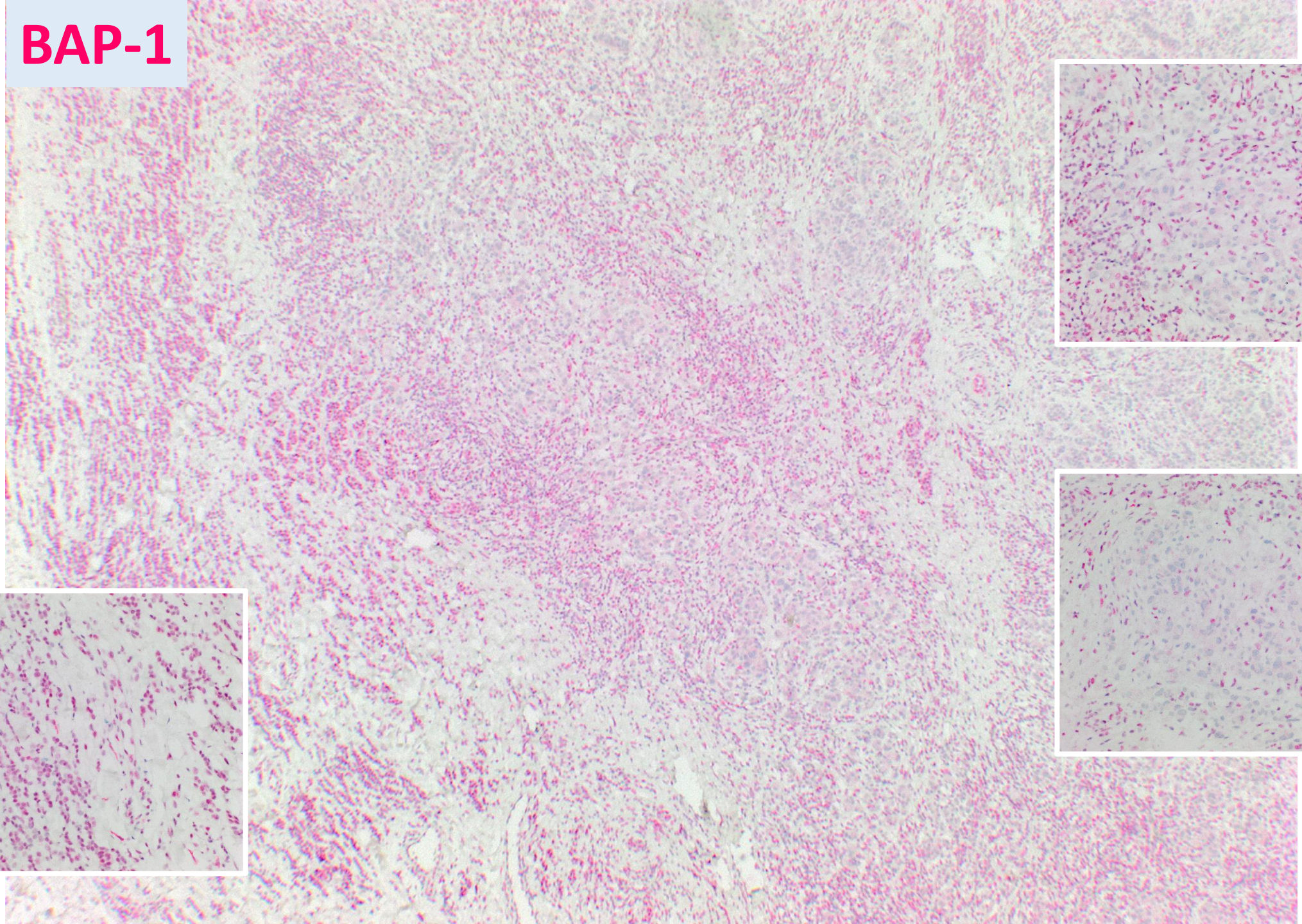








BAP-1



CASE 4

The best diagnosis is:

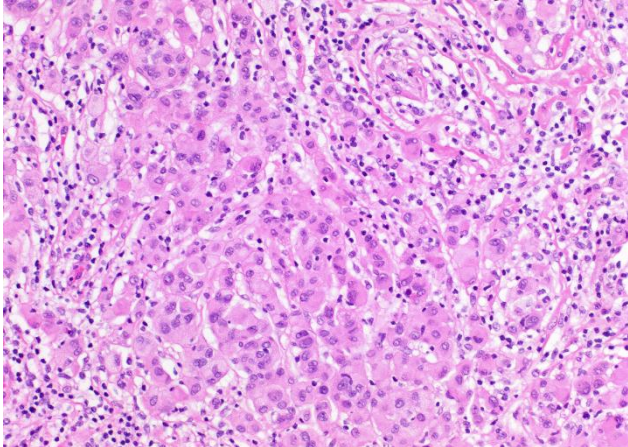
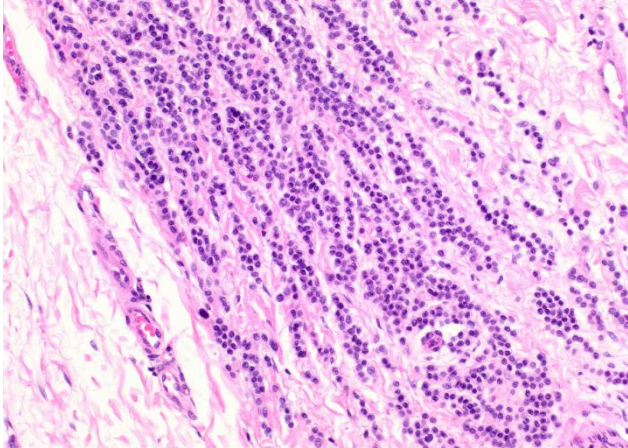
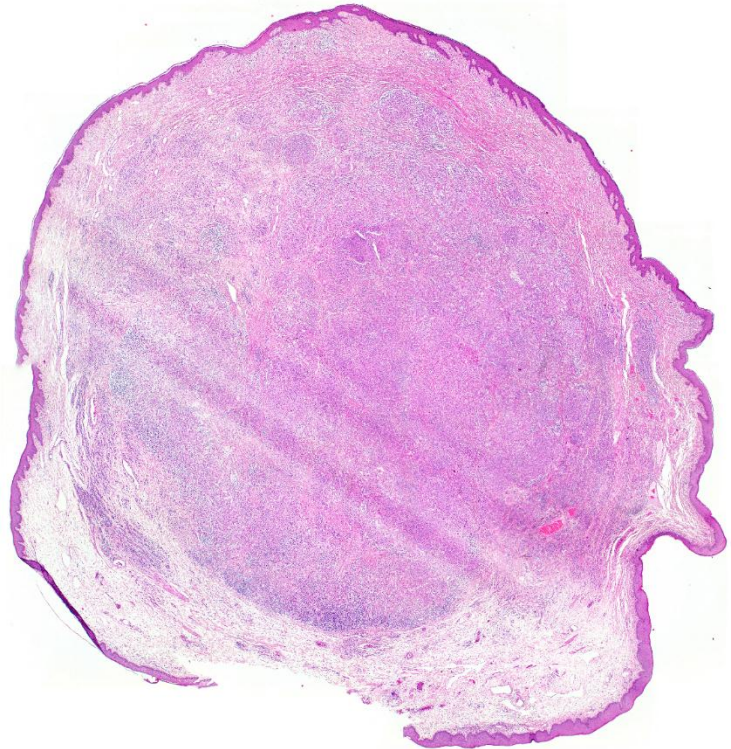1. BAPoma
2. Spitzoid melanoma
3. Combined melanocytic naevus
4. Intradermal Spitz naevus
5. Melanocytic tumour of uncertain malignant potential

CASE 4

The best diagnosis is:

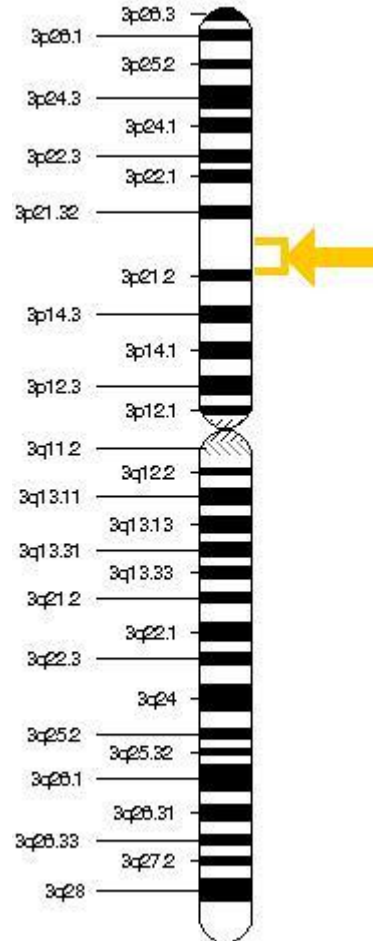
1. **BAPoma**
2. Spitzoid melanoma
3. Combined melanocytic naevus
4. Intradermal Spitz naevus
5. Melanocytic tumour of uncertain malignant potential

Case 4



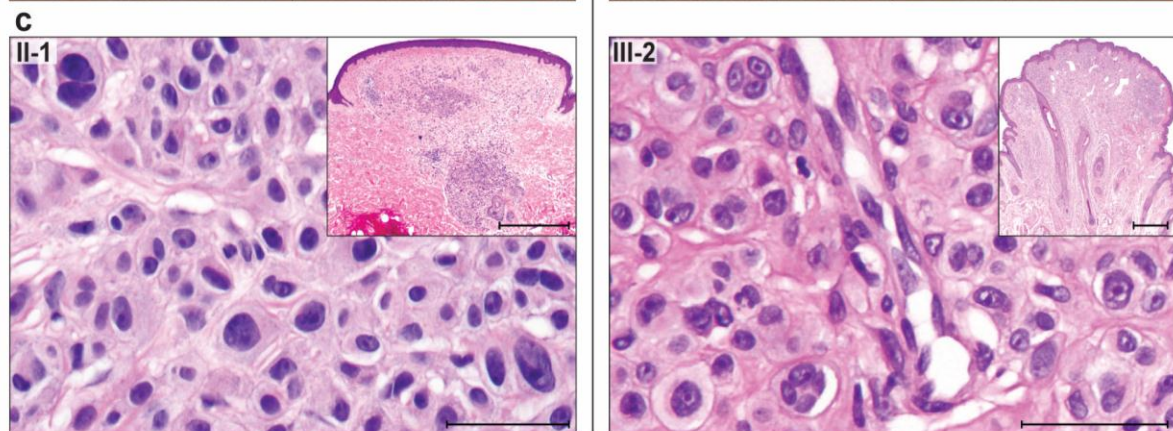
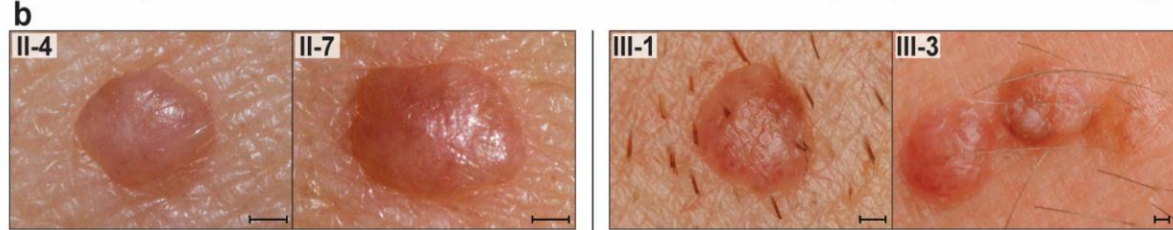
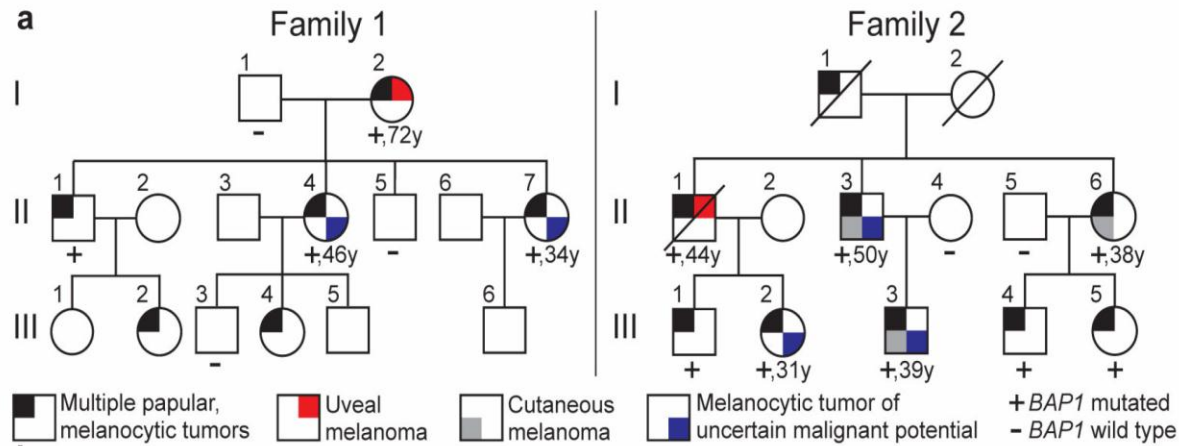
BAPoma

***BAP1* (BRCA-1 associated protein-1)**



- Member of the ubiquitin C-terminal hydrolases (UCH) subfamily of deubiquitylating enzymes (DUBs)
- Tumour suppressor gene
- The *BAP1* gene is located at chromosome region 3p21.124, a genomic region that is deleted in several human malignancies, including approximately 30-60% of mesotheliomas and 85% of metastasizing uveal melanoma

Germline mutations in *BAP1* predispose to melanocytic tumors



autosomal dominant syndrome

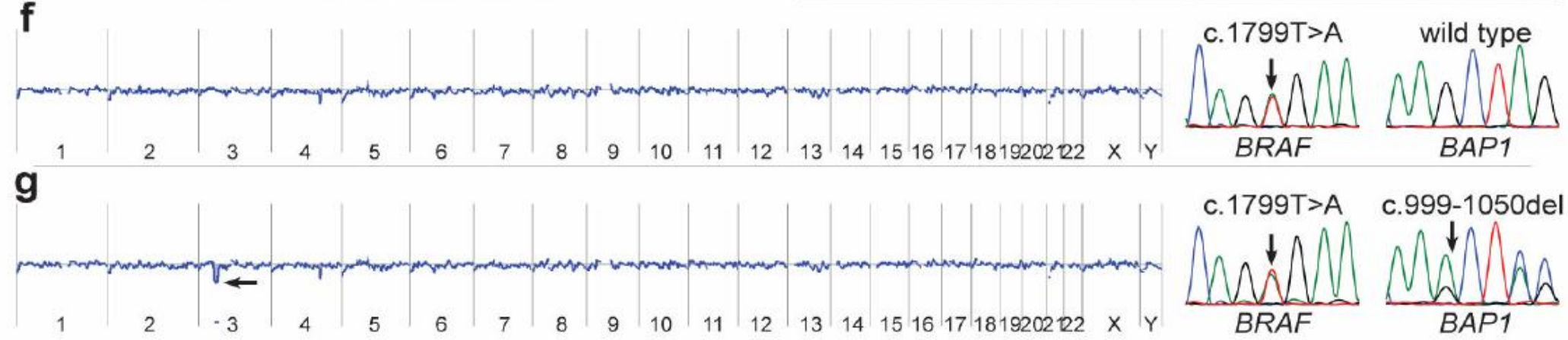
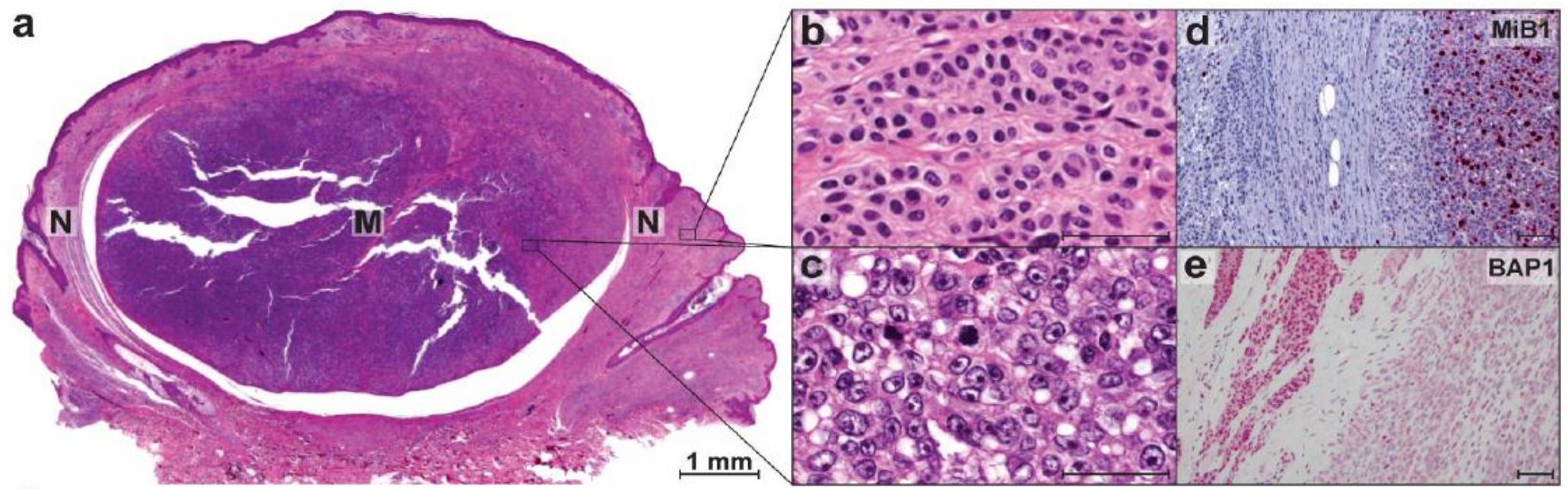
- inactivating germline mutations of the *BAP1* gene
- Some affected patients developed uveal or cutaneous melanomas
- Affected individuals had multiple cutaneous spitzoid melanocytic neoplasms (5 to over 50 tumours. Beginning in the second decade of life)

Melanocytic tumours with loss of BAP1 (BAPoma) Histology

- The cytological features of some of the cells were **reminiscent of Spitz naevi**; however, characteristic features (such as epidermal hyperplasia, hypergranulosis, Kamino bodies, clefting around junctional melanocytic nests, and spindle-shaped melanocytes) frequently seen in Spitz naevi were consistently absent
- 88% of the tumors showed **BRAF mutations**
- Some of the neoplasms exhibited one or more atypical features, such as high cellularity, considerable nuclear pleomorphism, and several chromosomal aberrations. These tumors were classified as **'neoplasms of uncertain malignant potential'**

Role of *BAP1* mutations in sporadic melanocytic neoplasms

- 156 randomly selected tumors without family history
- Common nevi (n=28); Spitz nevi (n=17); “atypical Spitz tumors” (n=18); primary melanomas originating from acral skin (n=15), mucosa (n=15), or skin with (n=15) or without (n=15) chronic sun-induced damage, and uvea (n=33)
- Somatic *BAP1* mutations: (40%) uveal melanomas, (11%) atypical Spitz tumors and (5%) of the melanomas (2 melanoma on skin without chronic sun-induced damage and 1 acral melanoma)
- Two of five sporadic cutaneous melanomas that arose in nevi harbored *BAP1* mutations.



A distinct subset of Atypical Spitz Tumors is characterized by *BRAF* mutation and loss of BAP1 expression

Thomas Wiesner^{1,3,*}, Rajmohan Murali^{1,2,*}, Isabella Fried³, Lorenzo Cerroni³, Klaus Busam², Heinz Kutzner⁴, and Boris C. Bastian^{1,2,5}

- assessed expression of BAP1 by immunohistochemistry
- **32 sporadic Atypical Spitz**
- 46 positive controls (29 common acquired nevi and 17 classical Spitz nevi showing no BAP1 mutations)
- 42 negative controls (epithelioid melanocytic tumors from 2 families with BAP1 germline mutations)

A distinct subset of Atypical Spitz Tumors is characterized by *BRAF* mutation and loss of BAP1 expression

Thomas Wiesner^{1,3,*}, Rajmohan Murali^{1,2,*}, Isabella Fried³, Lorenzo Cerroni³, Klaus Busam², Heinz Kutzner⁴, and Boris C. Bastian^{1,2,5}

Results:

- **Nine (28%) sporadic ASTs showed loss of BAP1 expression**, of which 8 (89%) had concomitant BRAF
- BAP1-negative tumors were primarily located in the dermis
- In 3 of the 9 BAP1-negative **cases (33%), significant numbers of tumor-infiltrating lymphocytes** were identified
- Somatic mutations were found in 5 cases (56%)

Ambiguous Melanocytic Tumors With Loss of 3p21

Iwei Yeh, MD, PhD,† Thaddeus W. Mully, MD,*† Thomas Wiesner, MD,‡
Swapna S. Vemula, MS,*† Sonia A. Mirza, MBBS,*† Alyssa J. Sparatta, BS,†
Timothy H. McCalmont, MD,*† Boris C. Bastian, MD,*† and Philip E. LeBoit, MD*†*

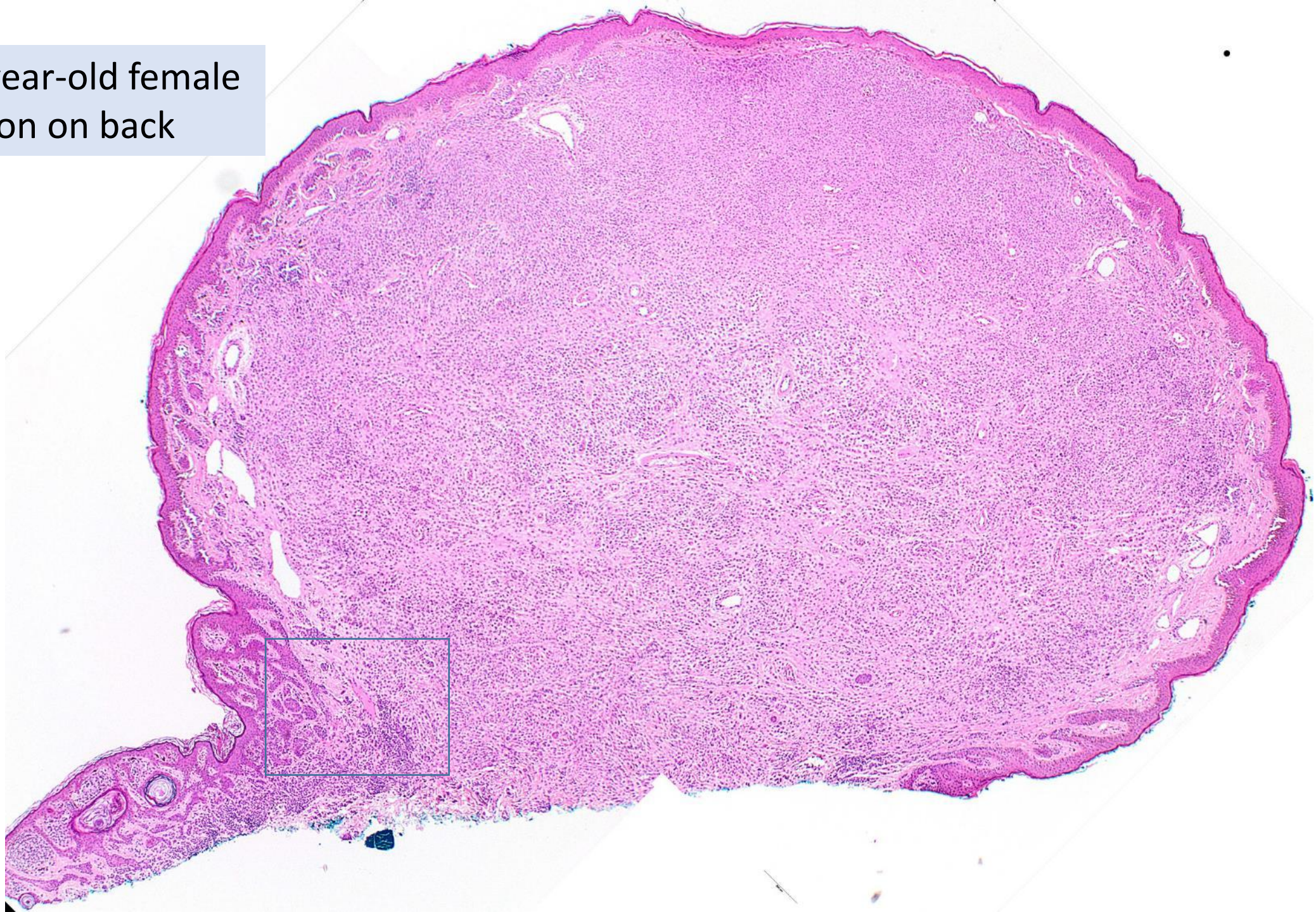
- **436 melanocytic lesions** for which array CGH was performed as part of the diagnostic assessment
- **Genomic loss** of >1Mbp isolated to chromosome 3 spanning **the BAP1 locus was identified in 29 (6.7%) cases**
- Loss of function of BAP1 was confirmed in 17 of these cases either by identification of a BAP1 loss-of-function mutation or loss of BAP1 immunohistochemical staining
- 16 cases **(94%) demonstrated spitzoid cytomorphology**

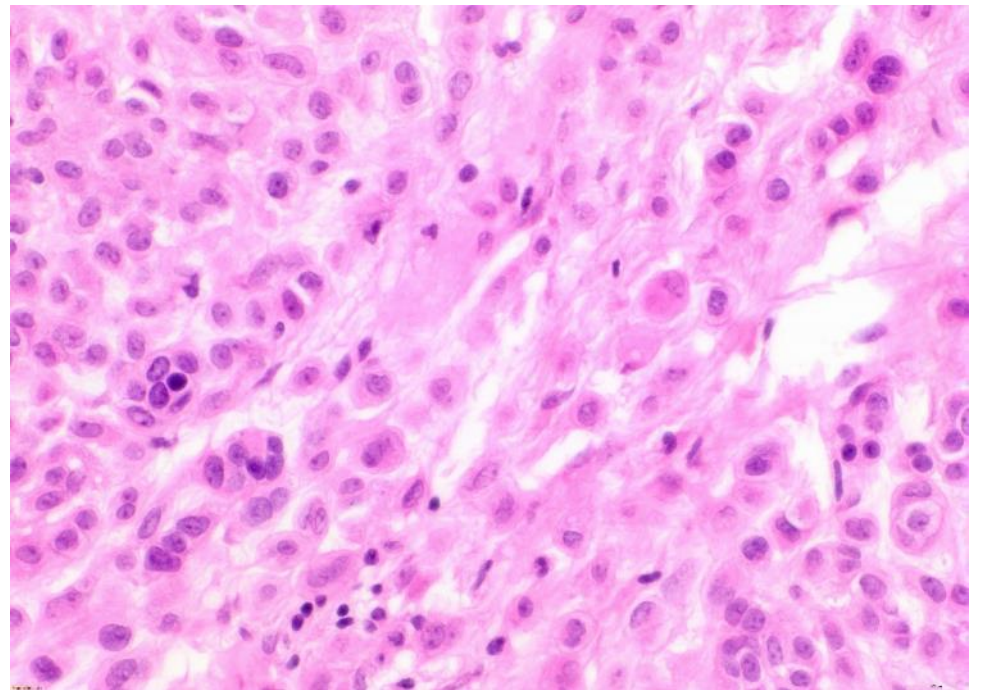
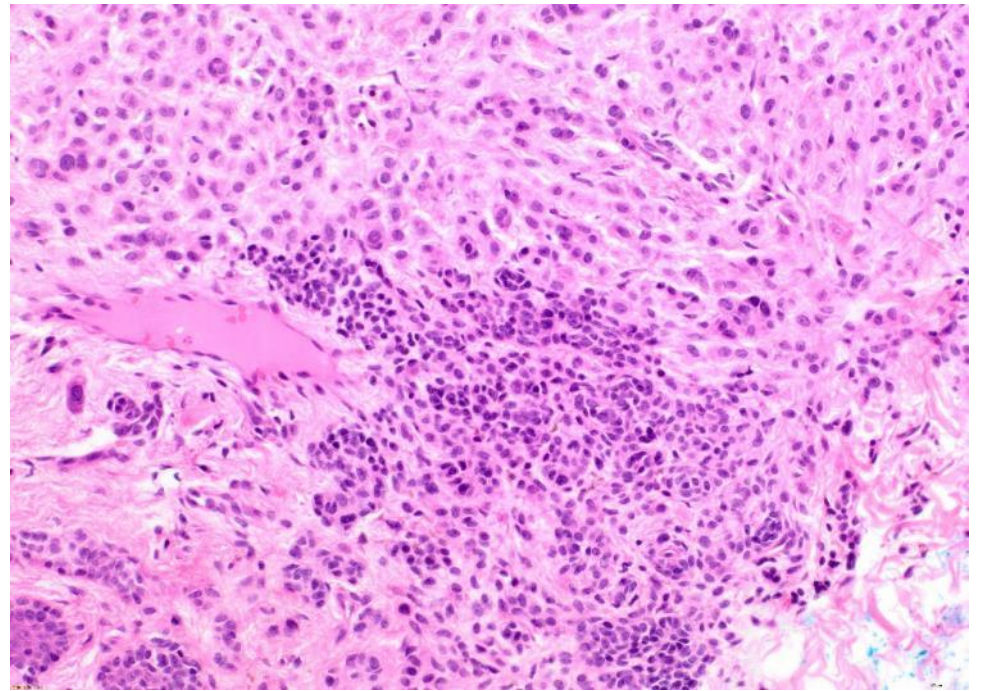
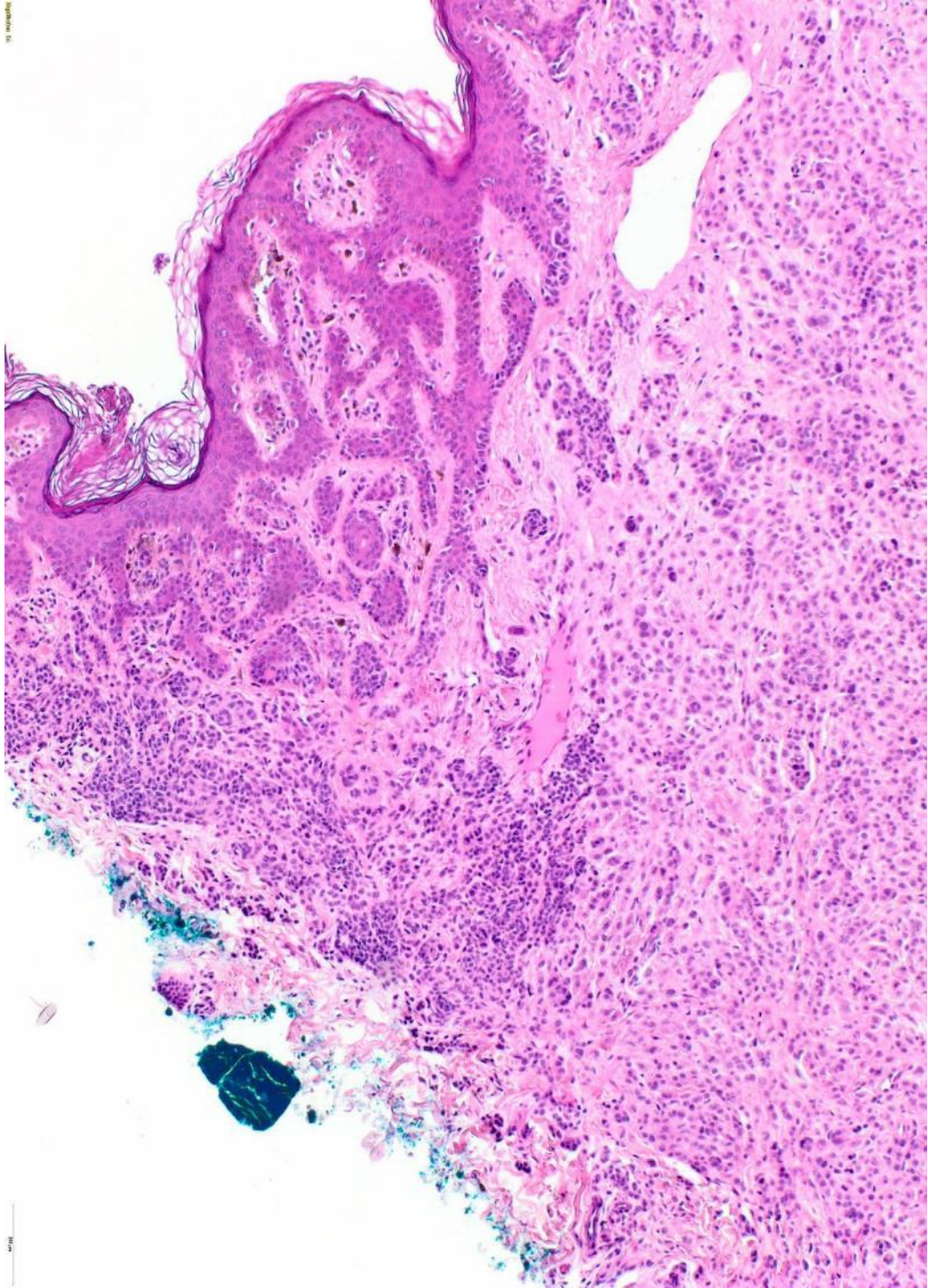
Ambiguous Melanocytic Tumors With Loss of 3p21

Iwei Yeh, MD, PhD, † Thaddeus W. Mully, MD,* † Thomas Wiesner, MD, ‡
Swapna S. Vemula, MS,* † Sonia A. Mirza, MBBS,* † Alyssa J. Sparatta, BS, †
Timothy H. McCalmont, MD,* † Boris C. Bastian, MD,* † and Philip E. LeBoit, MD* †*

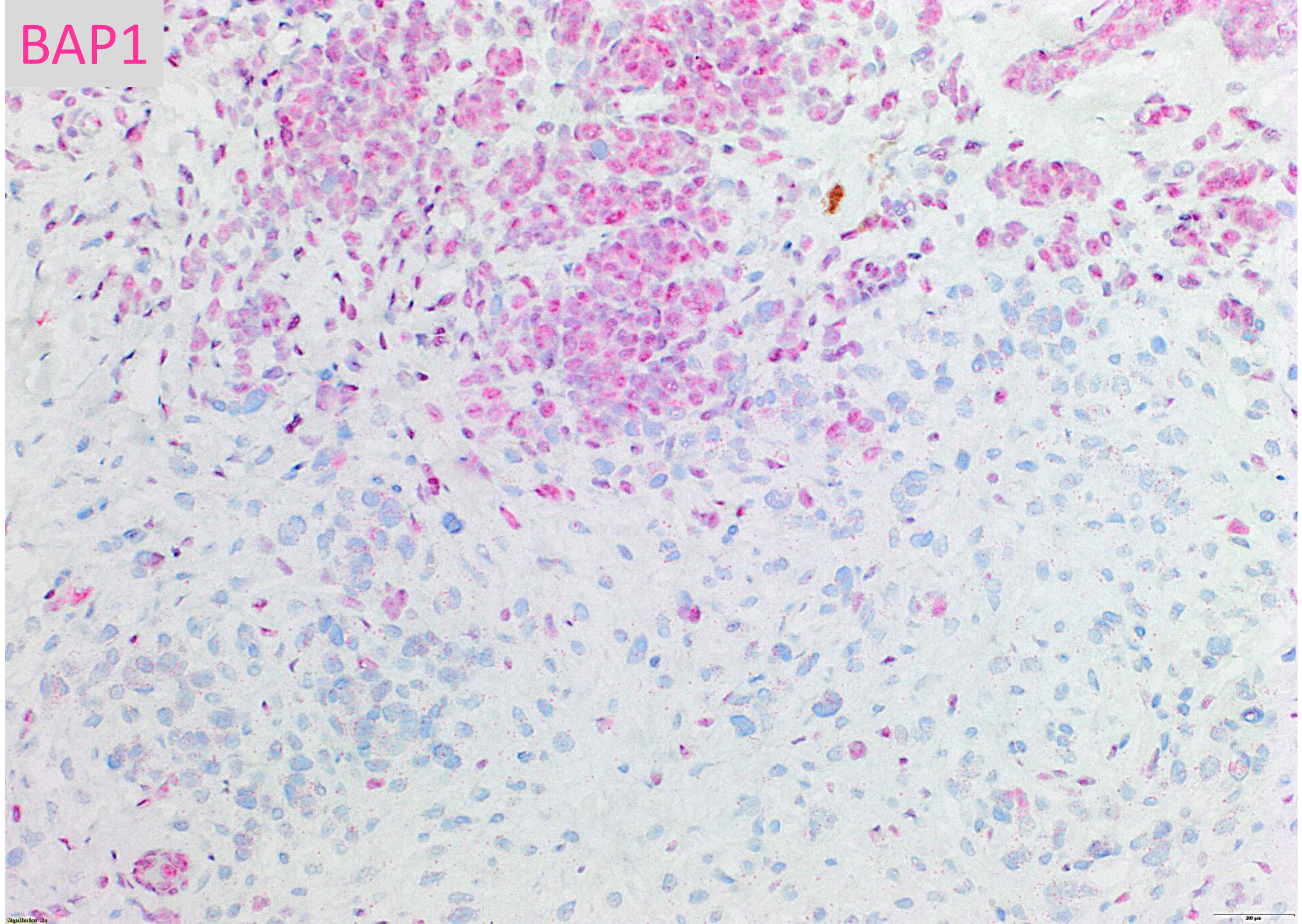
- **Recurrence was not identified** in the subset of patients for whom clinical follow-up was available (n=9)
- “We believe that these lesions are best regarded as a **distinctive form of Spitz nevus**, overlapping with what has previously been reported as **Spitz nevus with a halo reaction**”

22 year-old female
Lesion on back

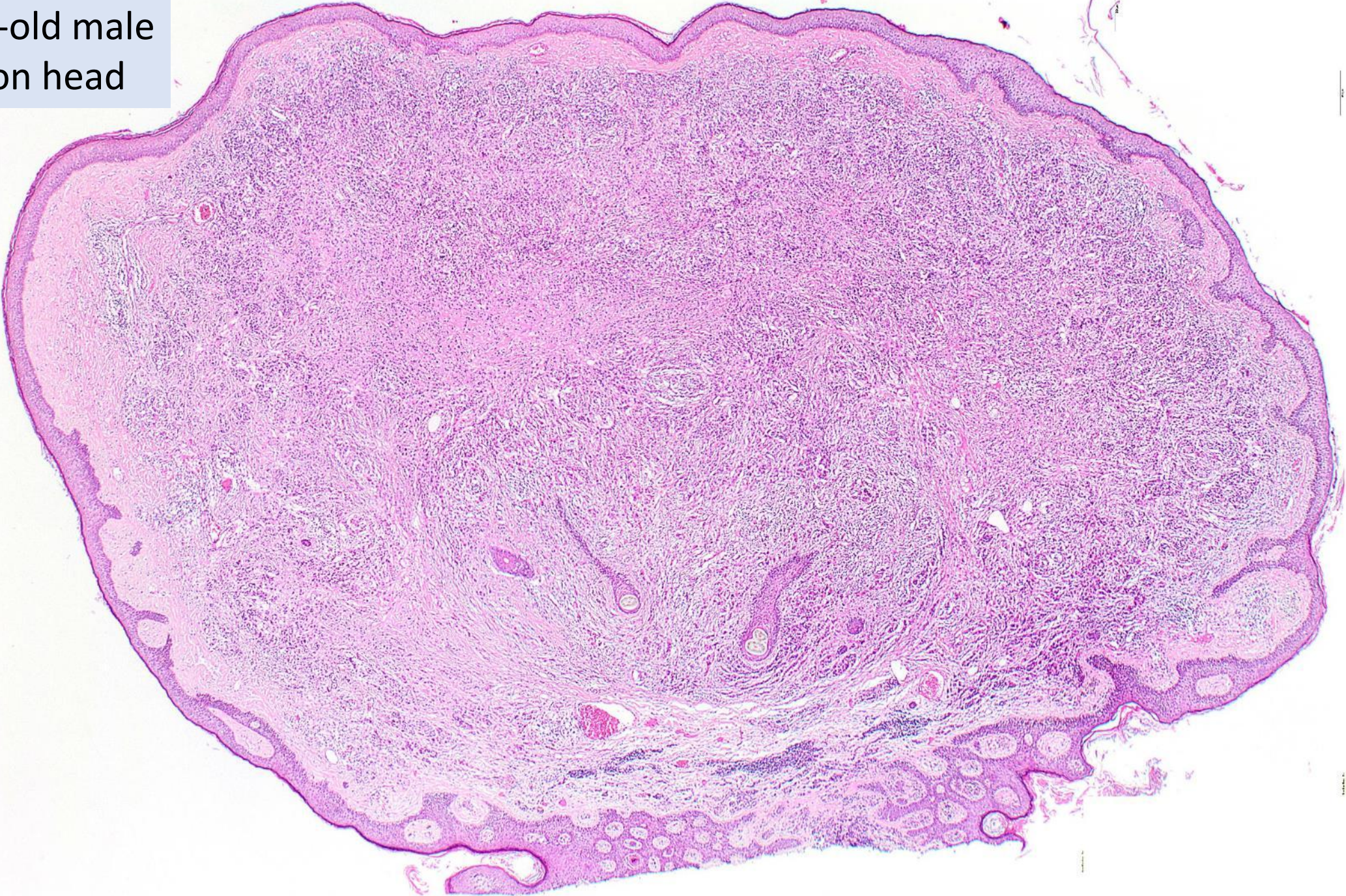


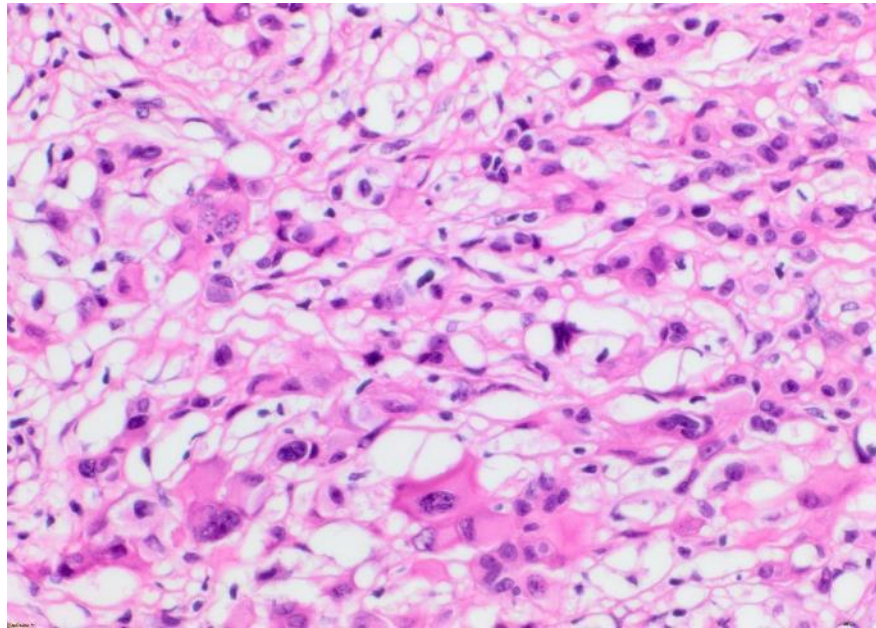
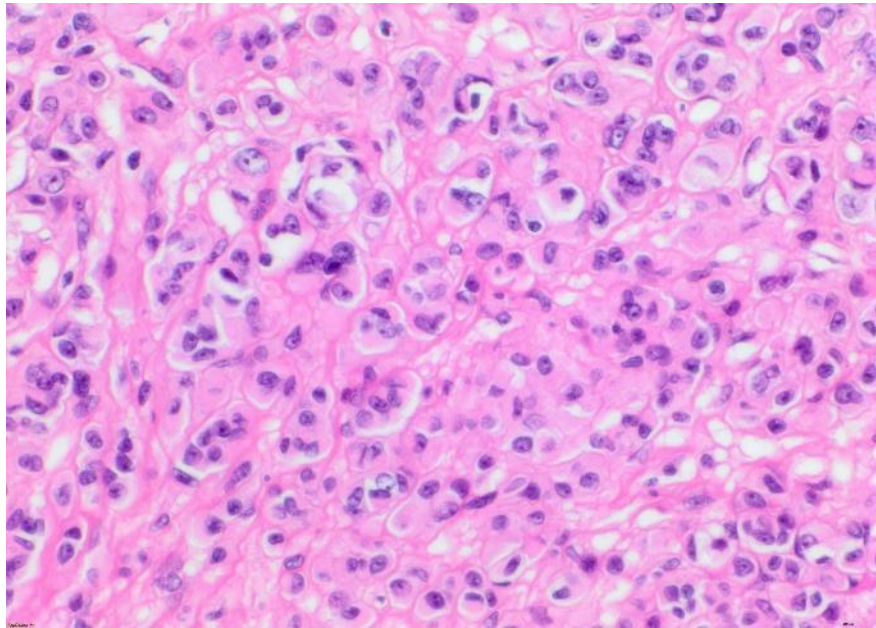
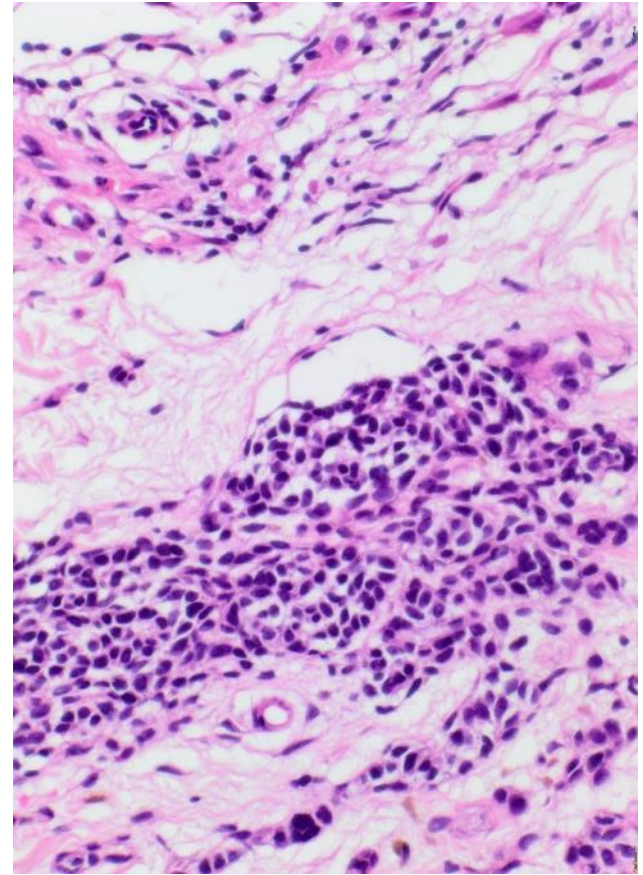
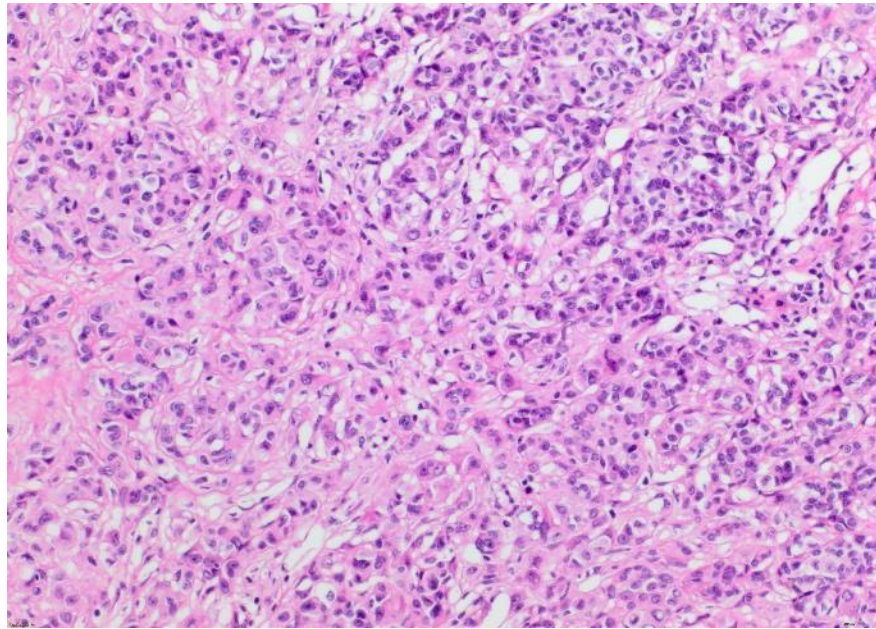
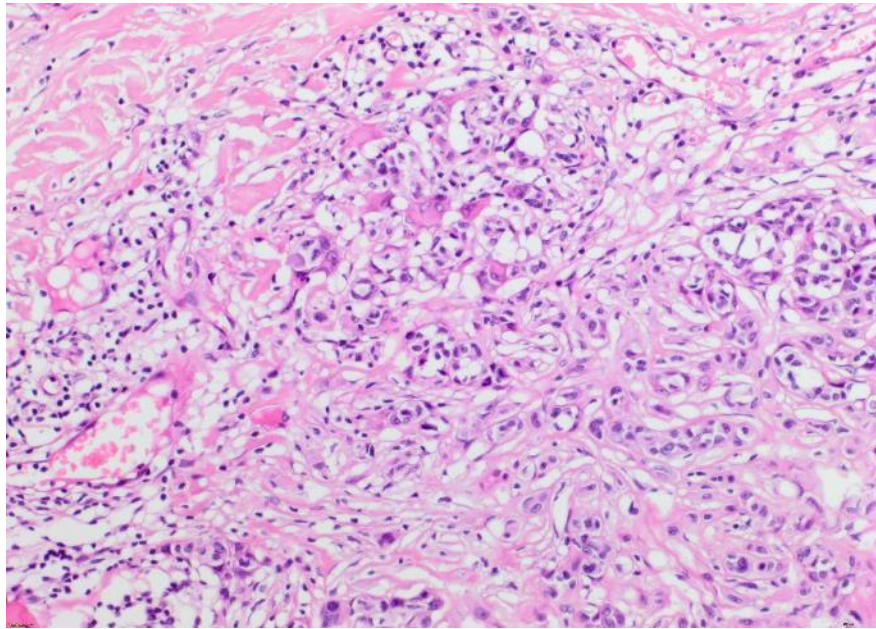


BAP1

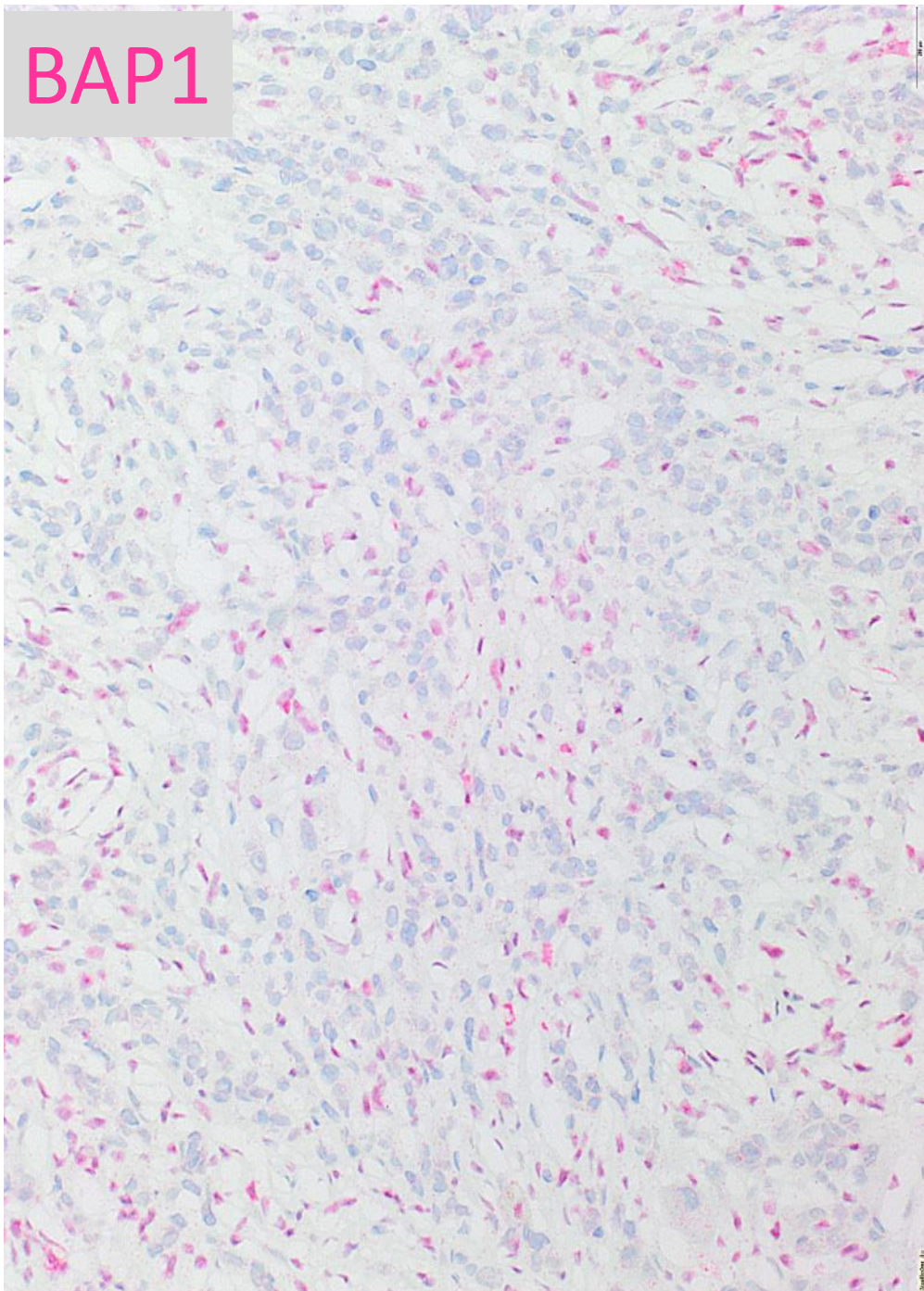


44 year-old male
Lesion on head

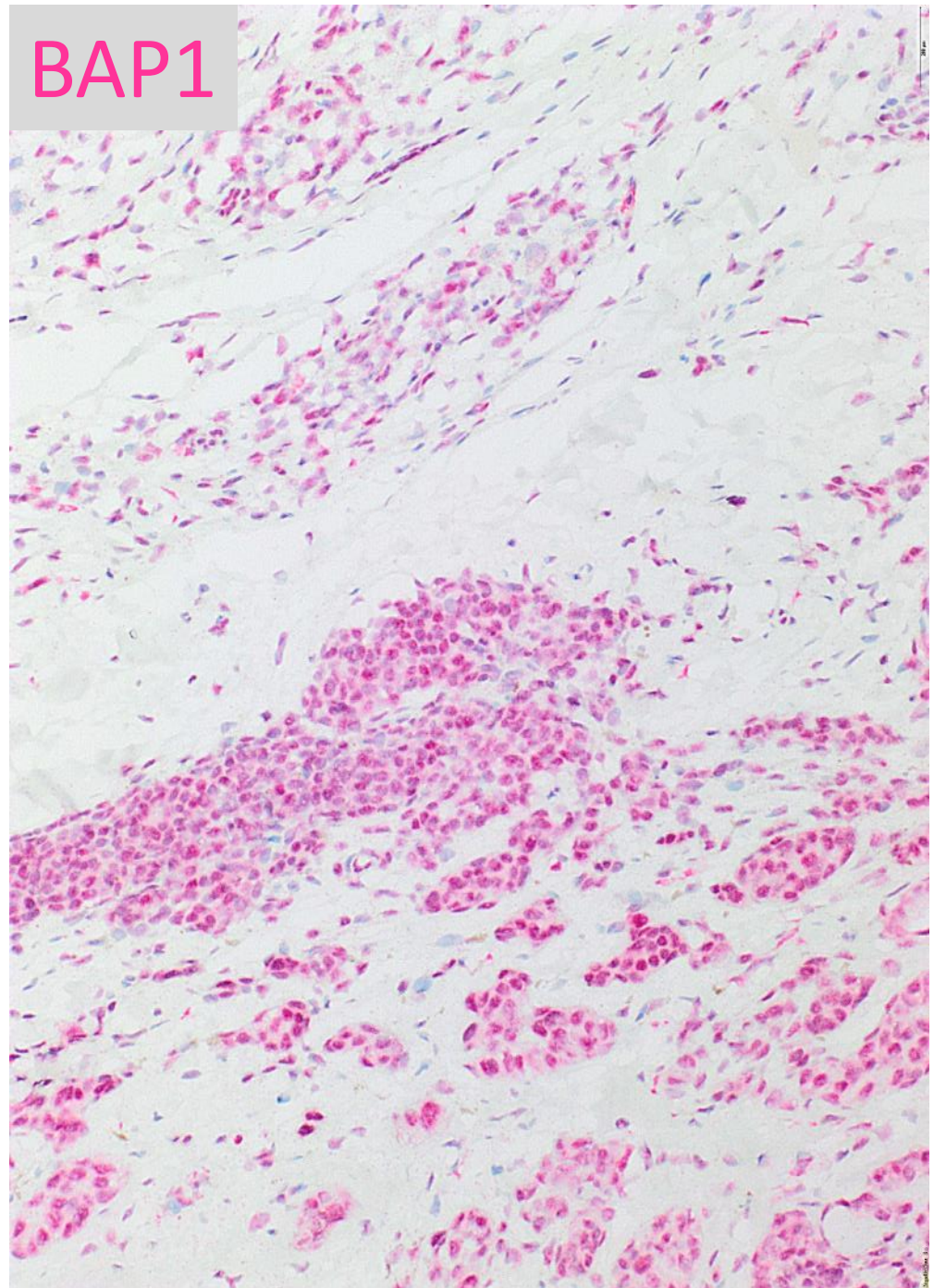




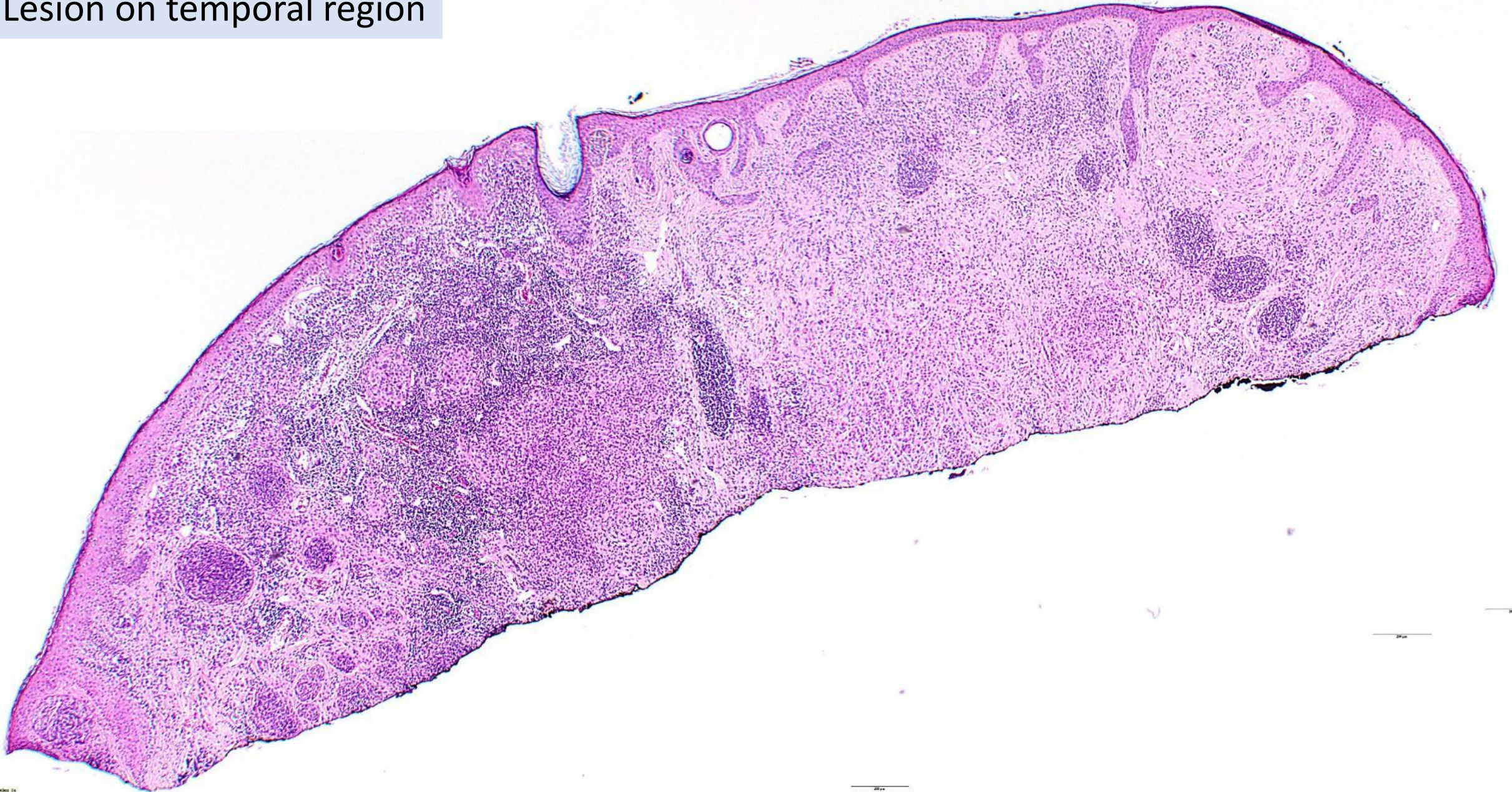BAP1

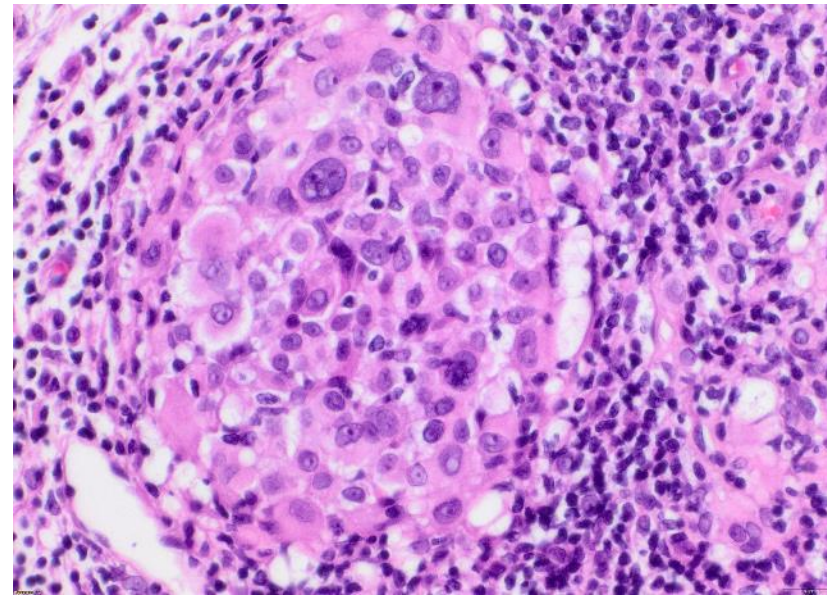
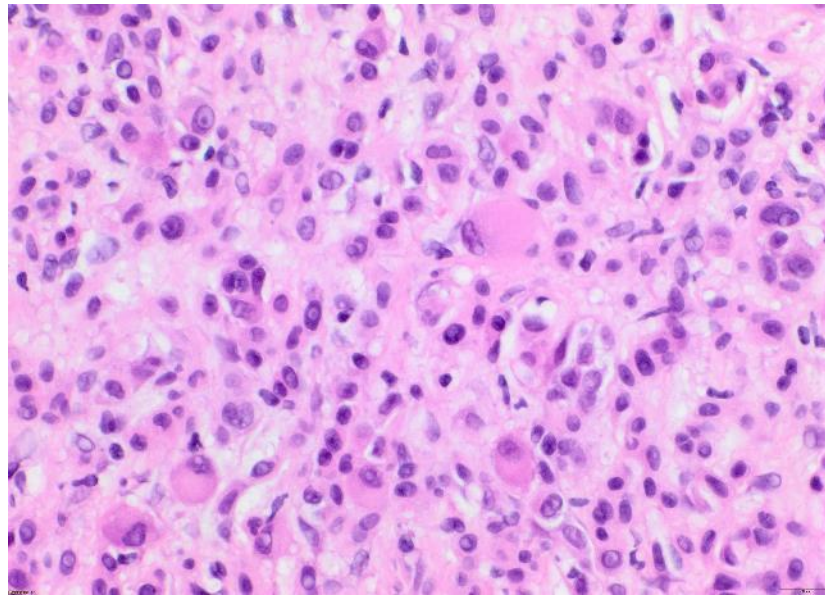
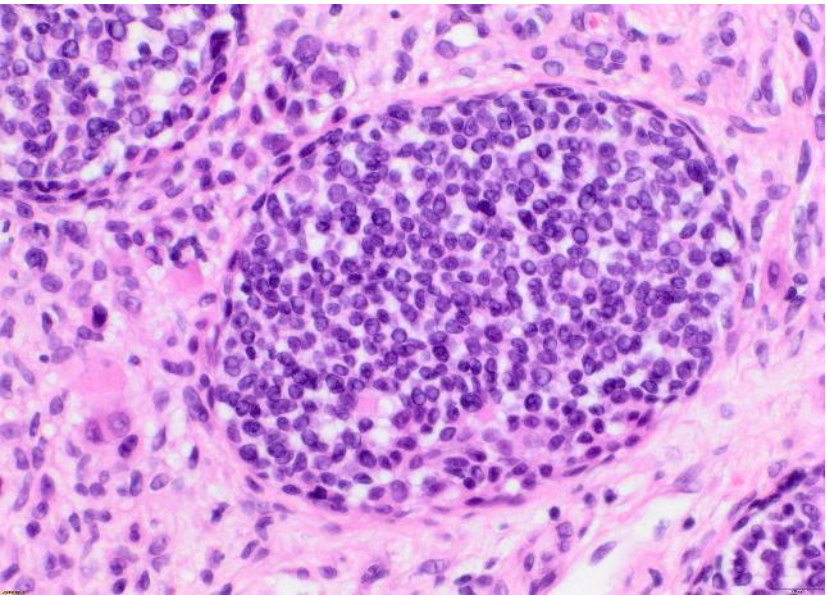
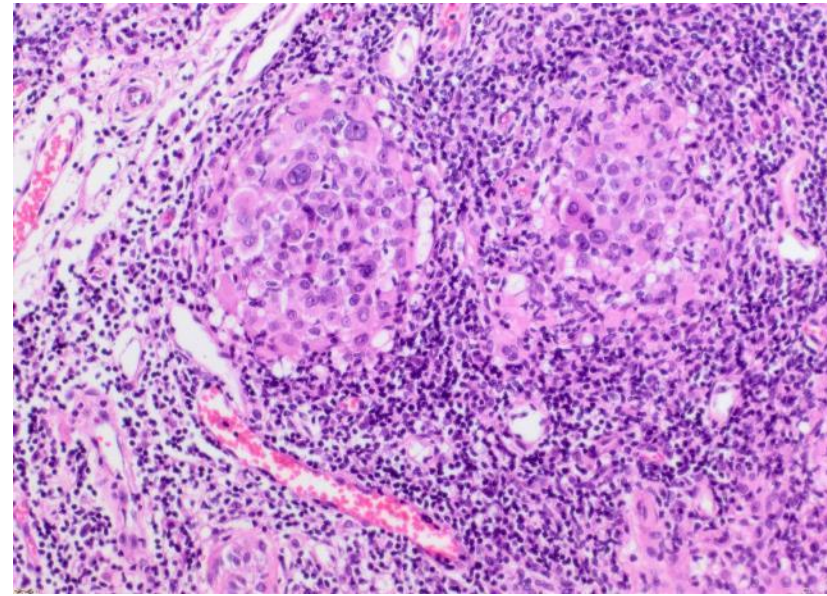
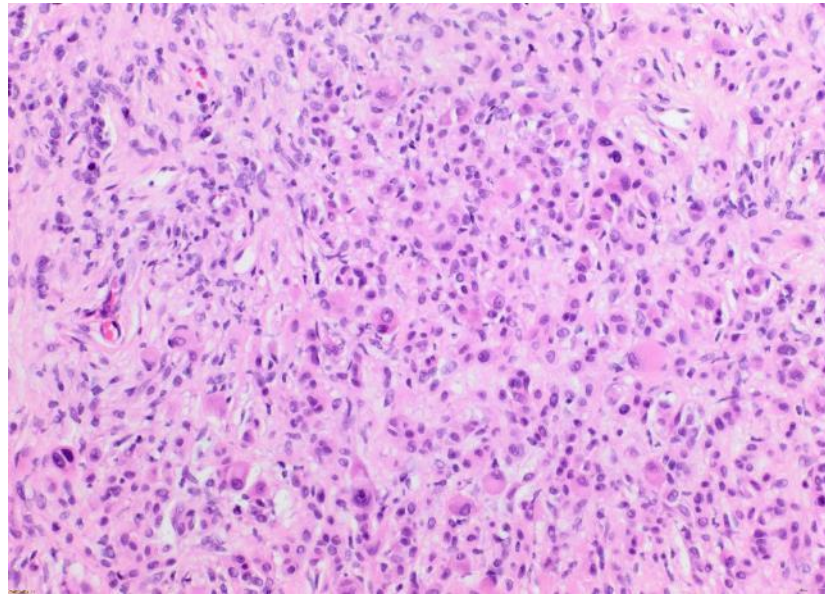
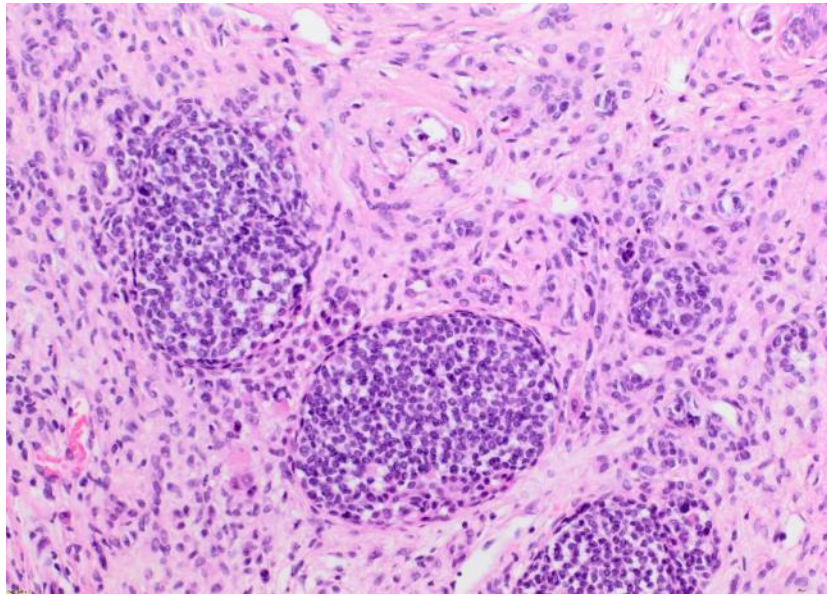


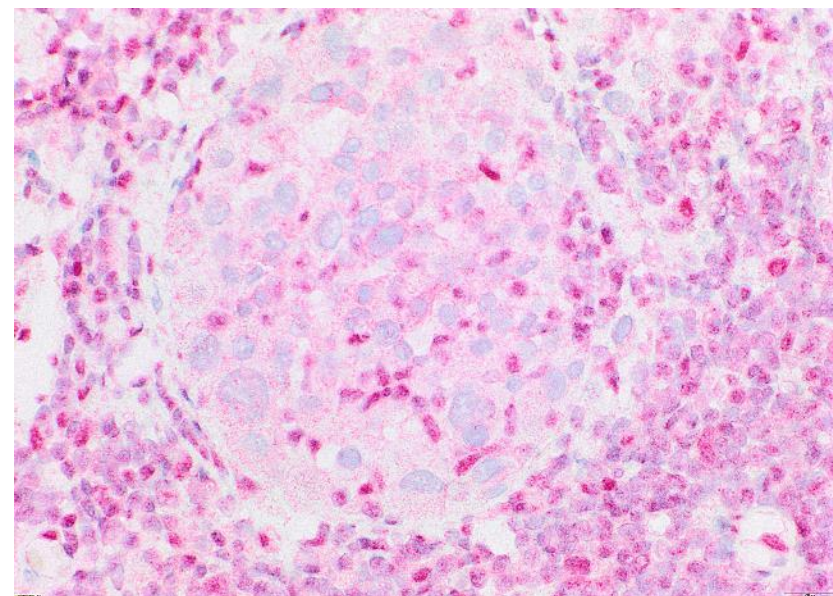
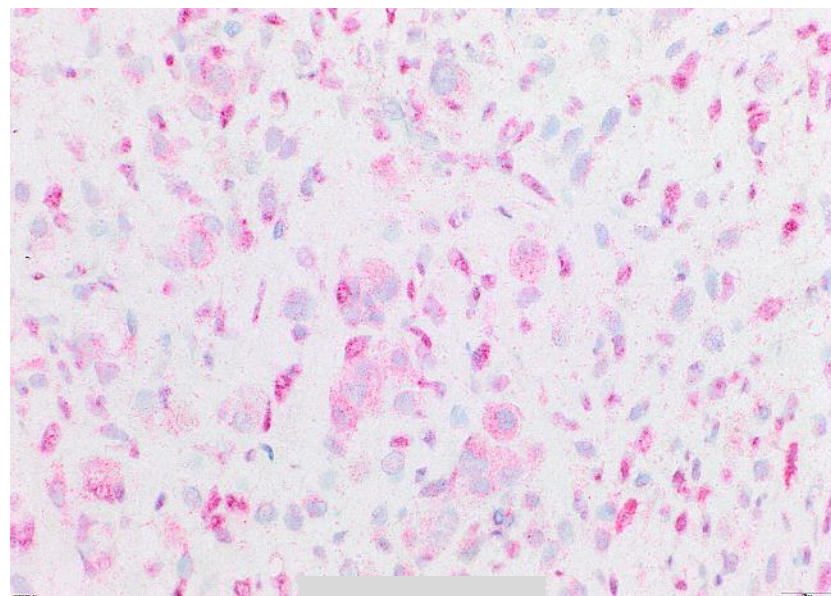
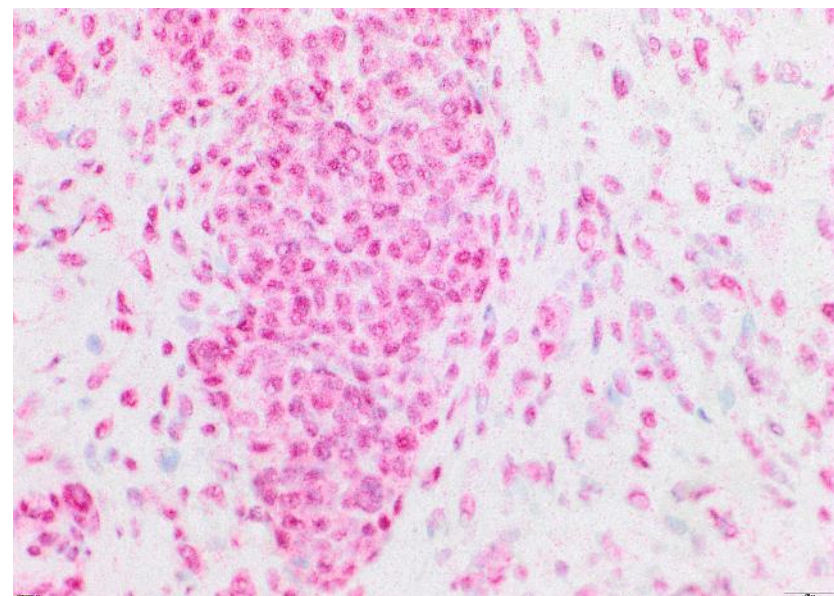
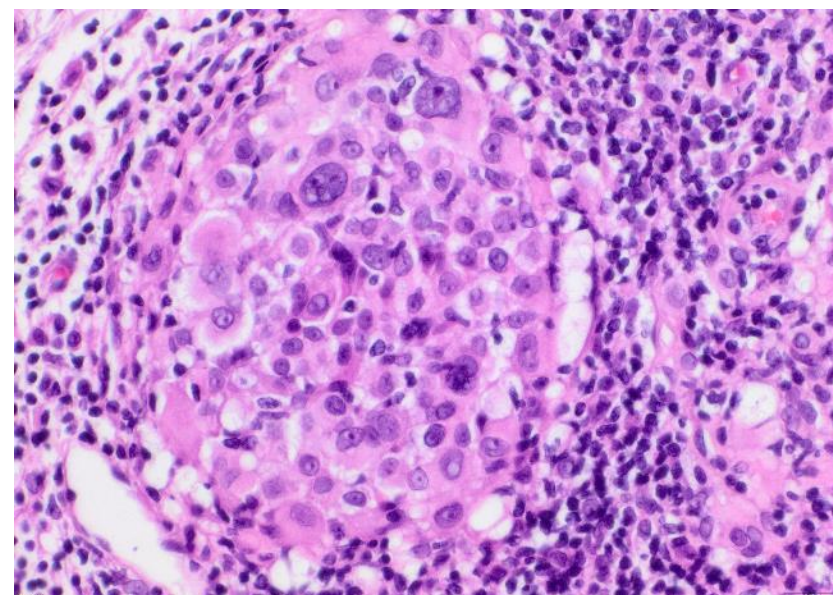
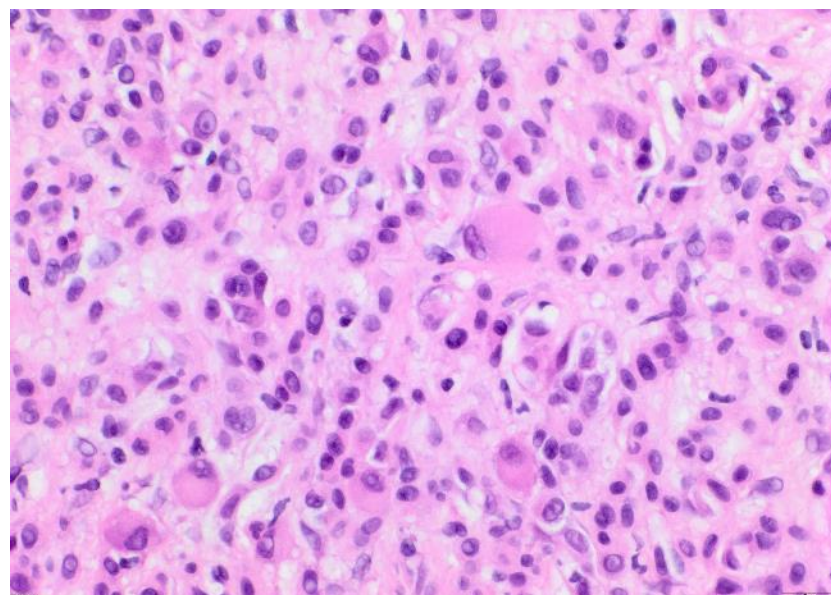
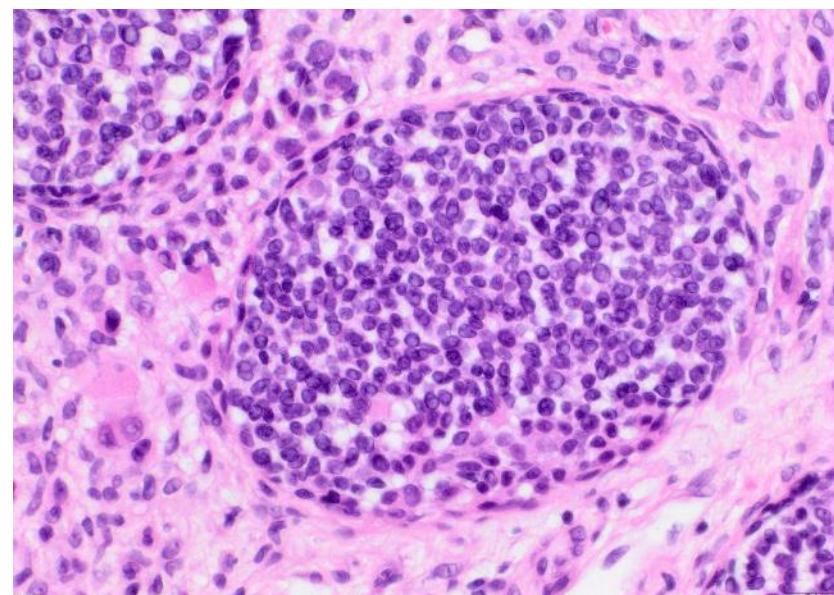
BAP1



18 year-old female
Lesion on temporal region



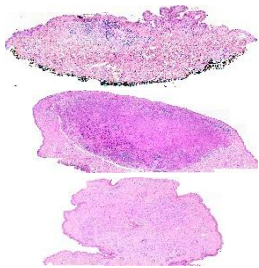




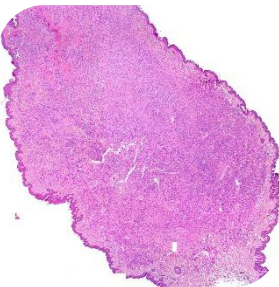
BAP1

BAPoma

Combined (ordinary + Spitz)
Predominantly intradermal (polypoid)
Prominent inflammatory component



Autosomal dominant syndrome: multiple lesions
Personal or family history of mesothelioma, uveal melanoma or skin melanoma

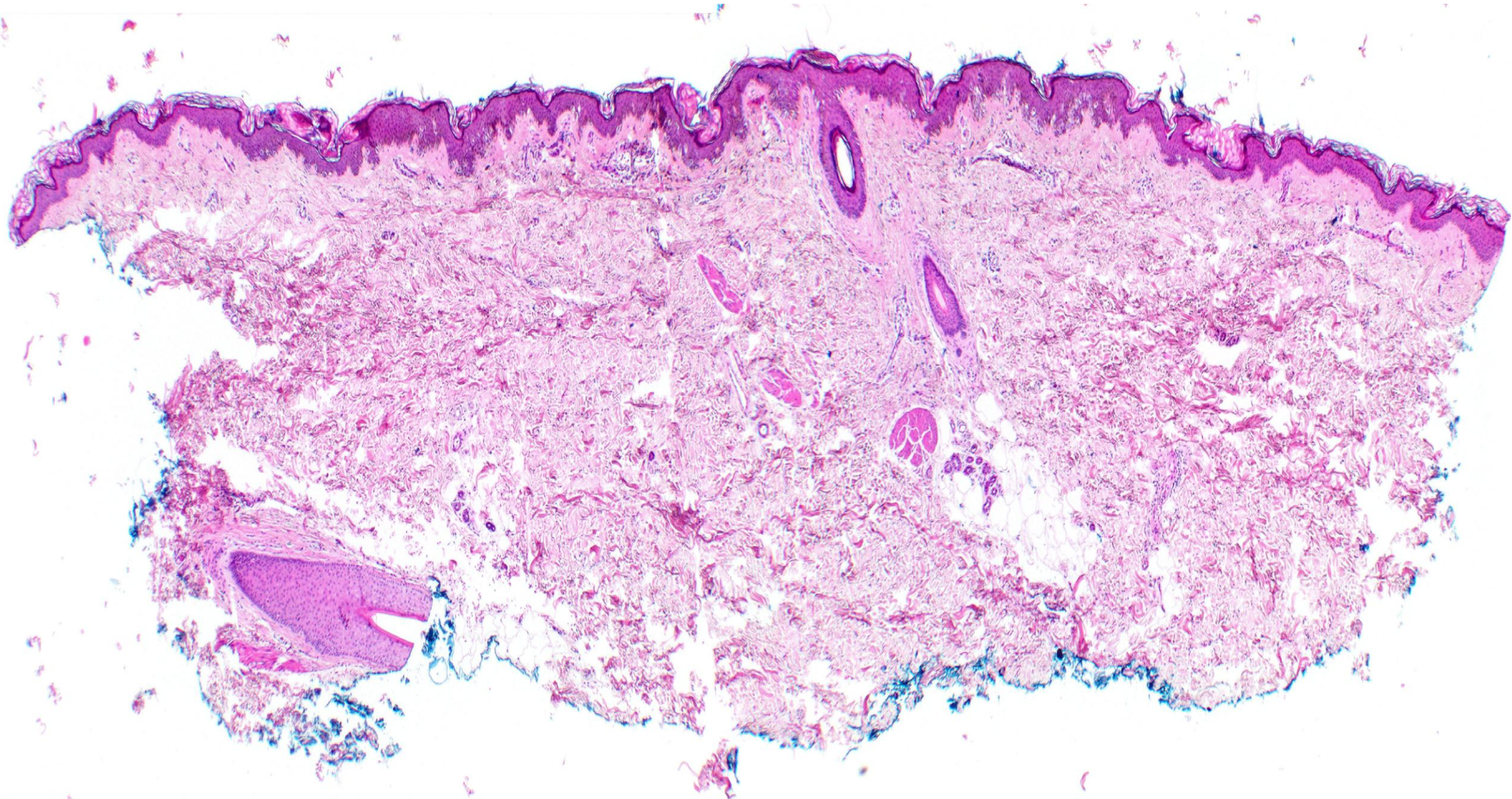


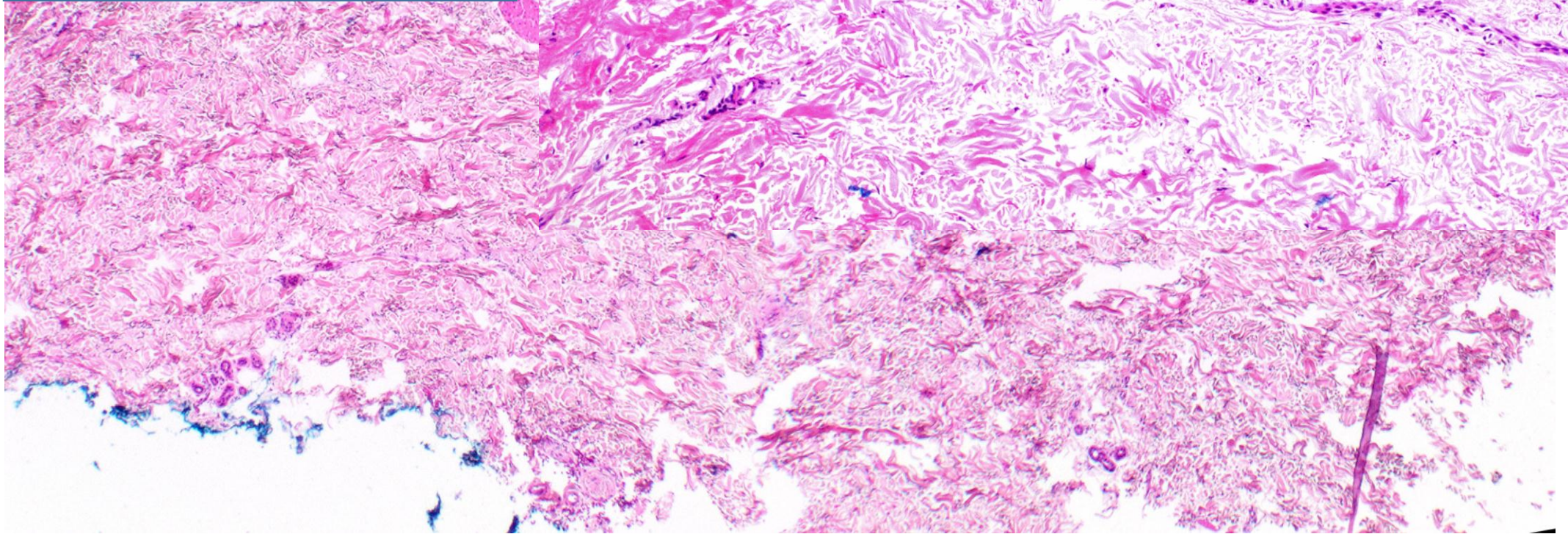
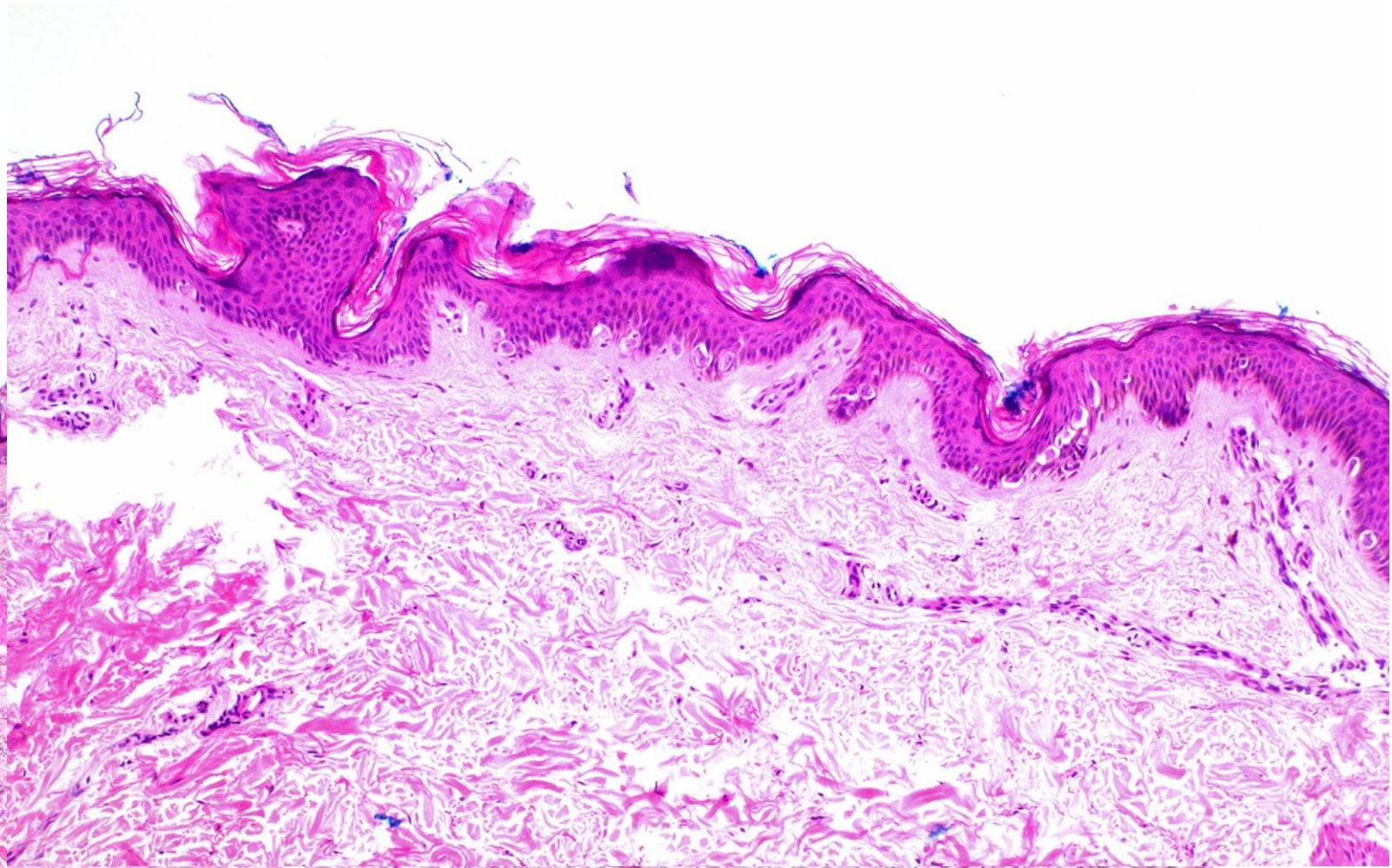
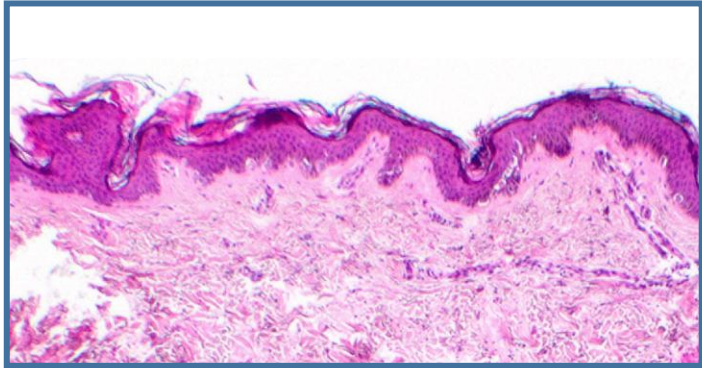
Sporadic: Usually benign
Subset: MELTUMP

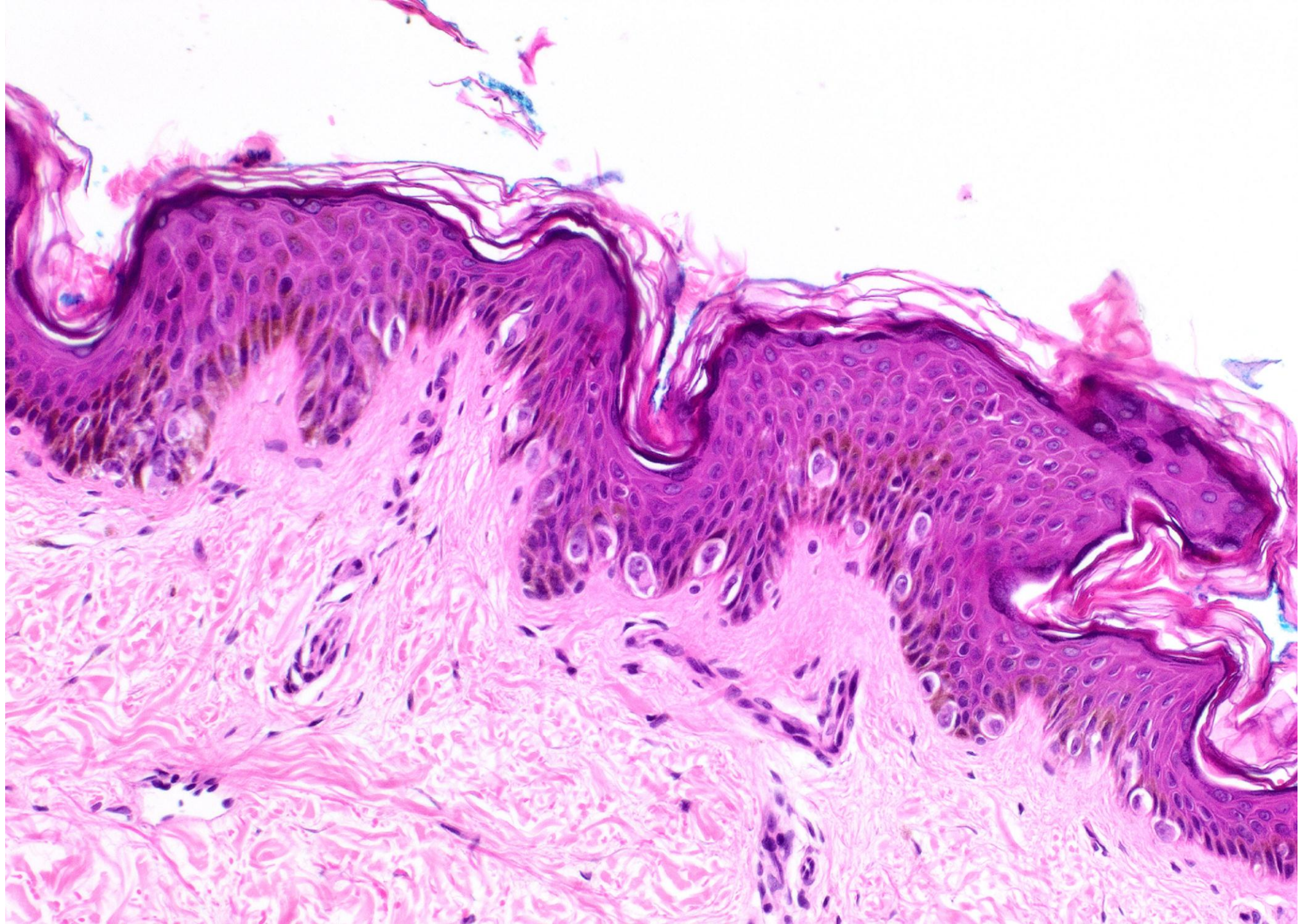
CASE 5

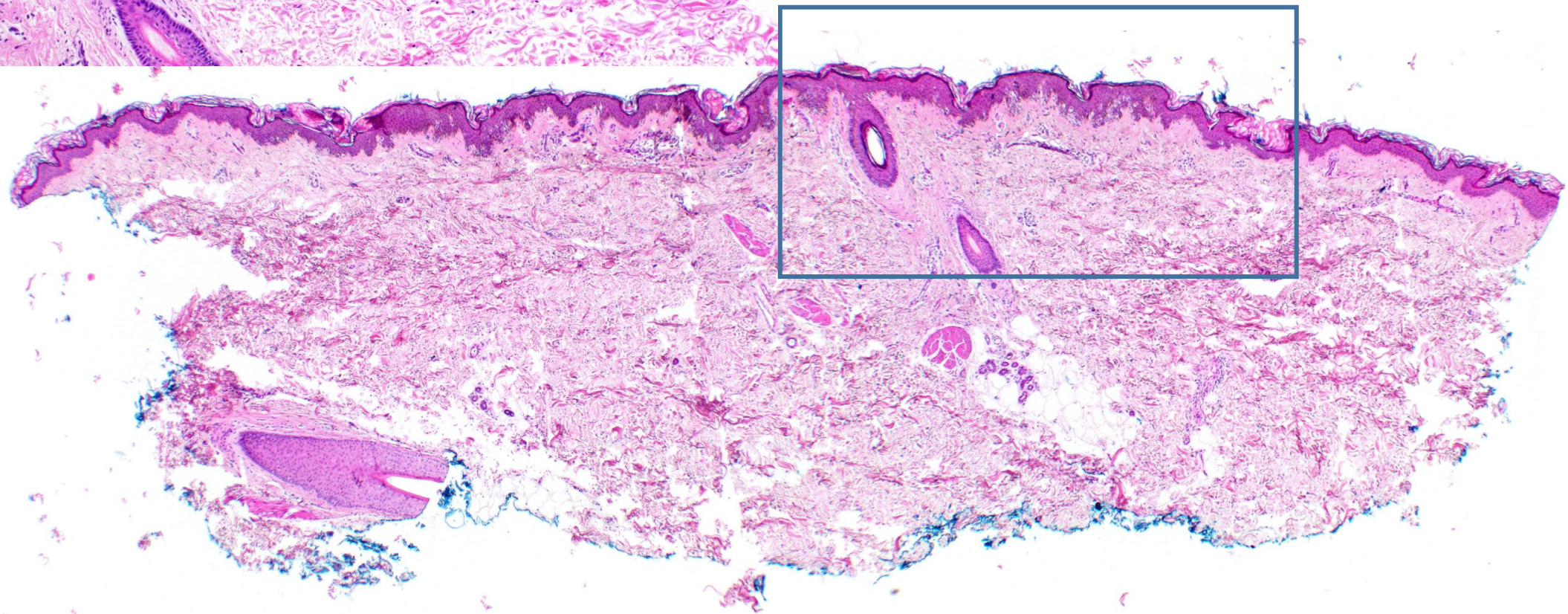
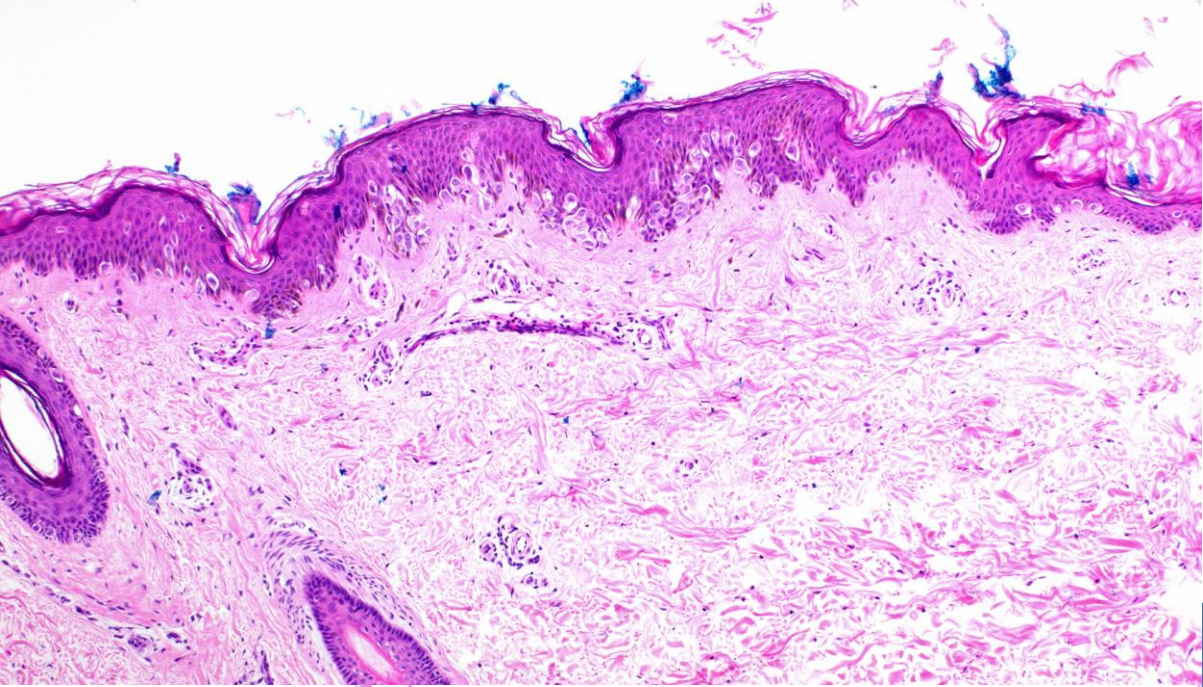
- Female, 33
- Pigmented lesion
- Left thigh
- Recently noted

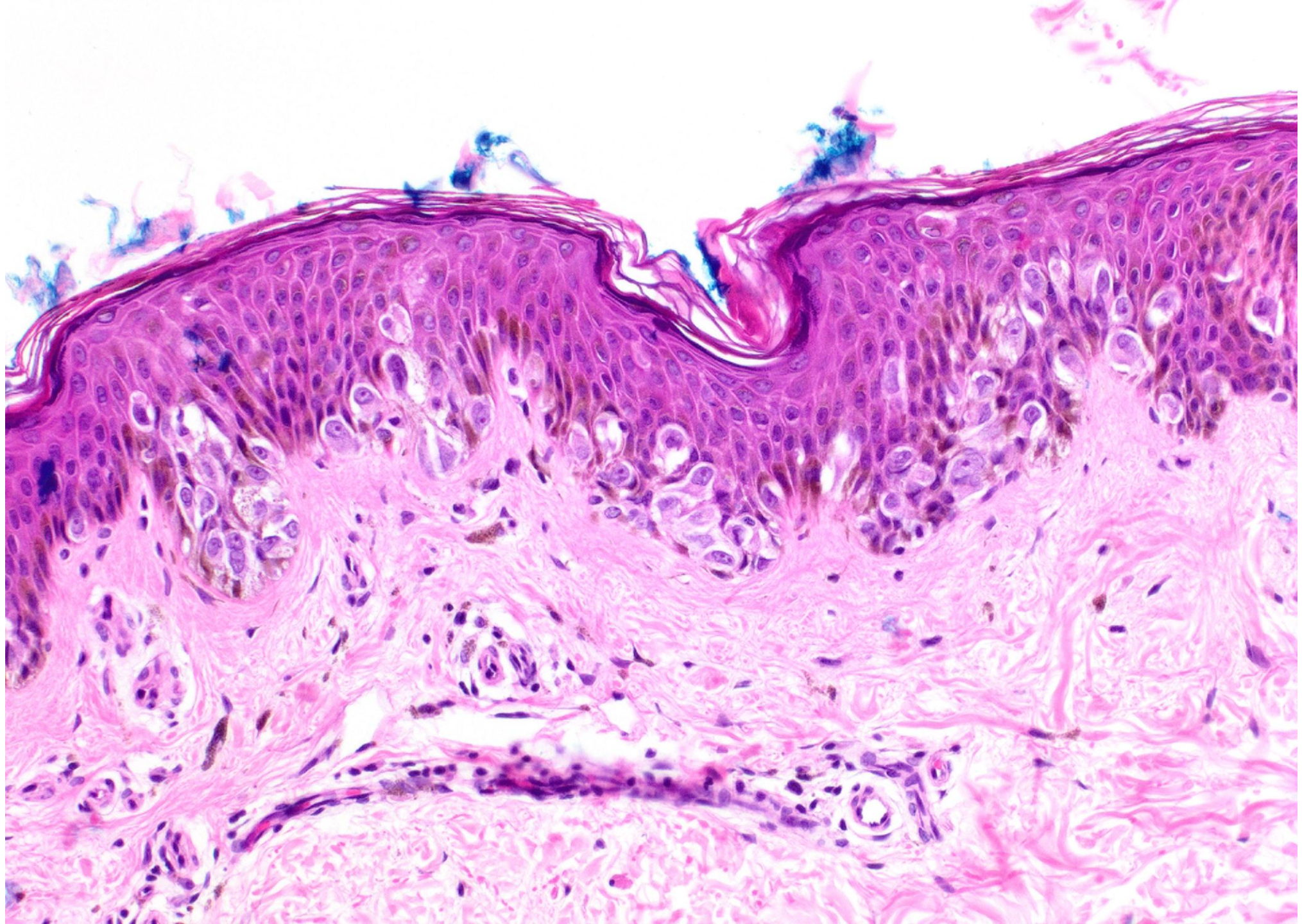
Histopathology









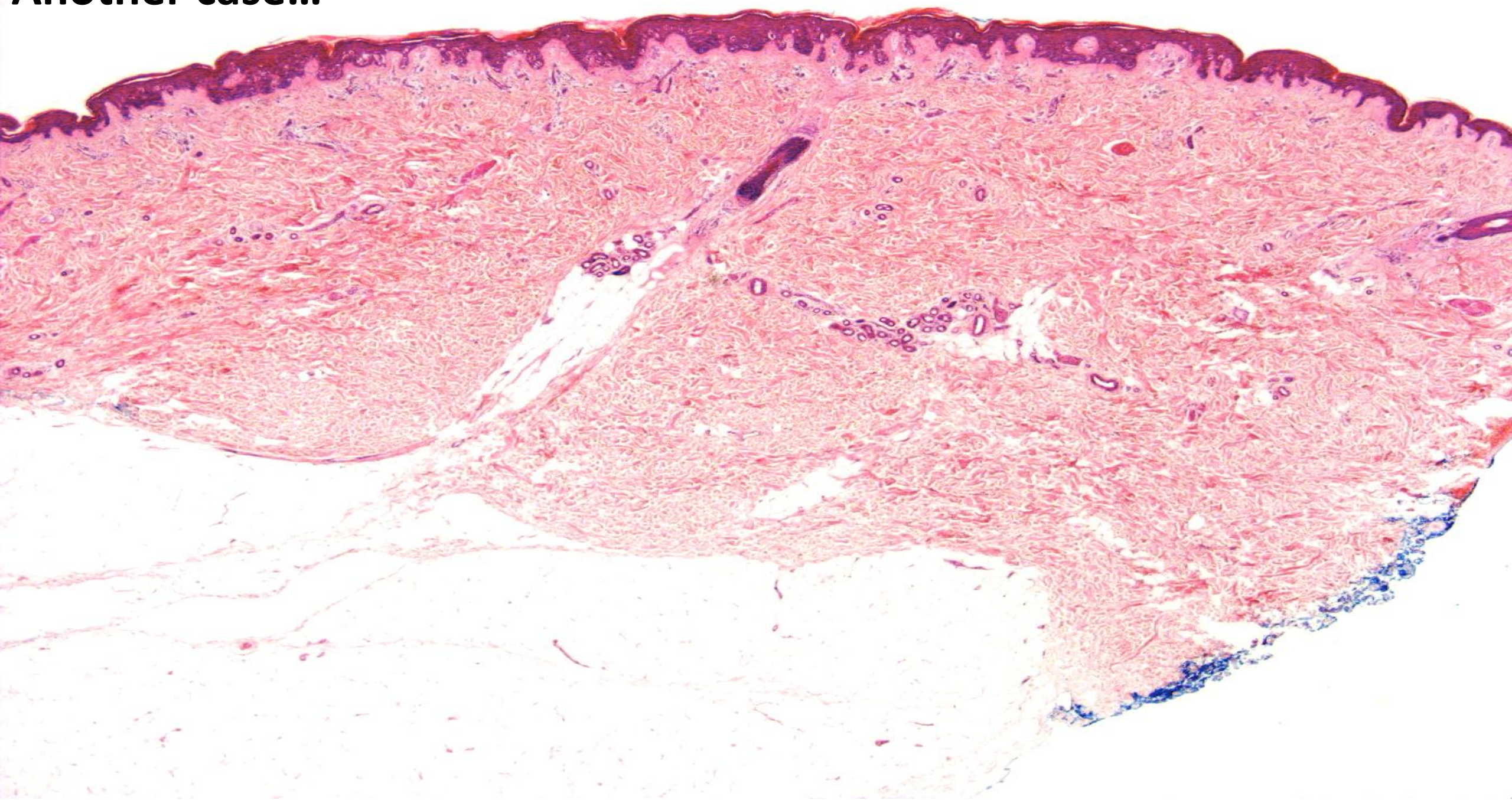


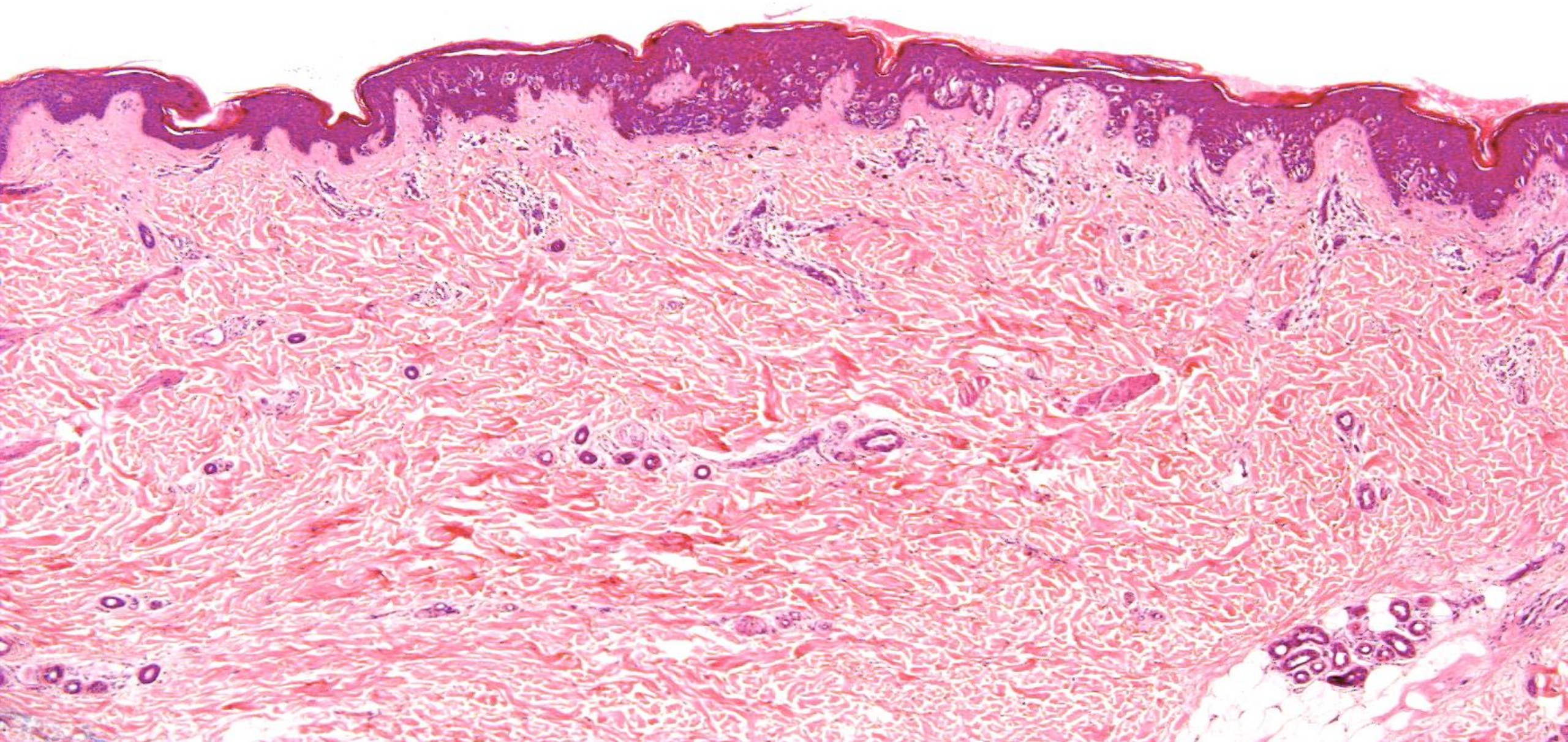
- The best diagnosis is:
 - A. Atypical junctional melanocytic hyperplasia
 - B. Intraepidermal Spitz naevus with pagetoid spread
 - C. Melanoma in-situ
 - D. Pigmented extramammary Paget's disease
 - E. Junctional melanocytic naevus

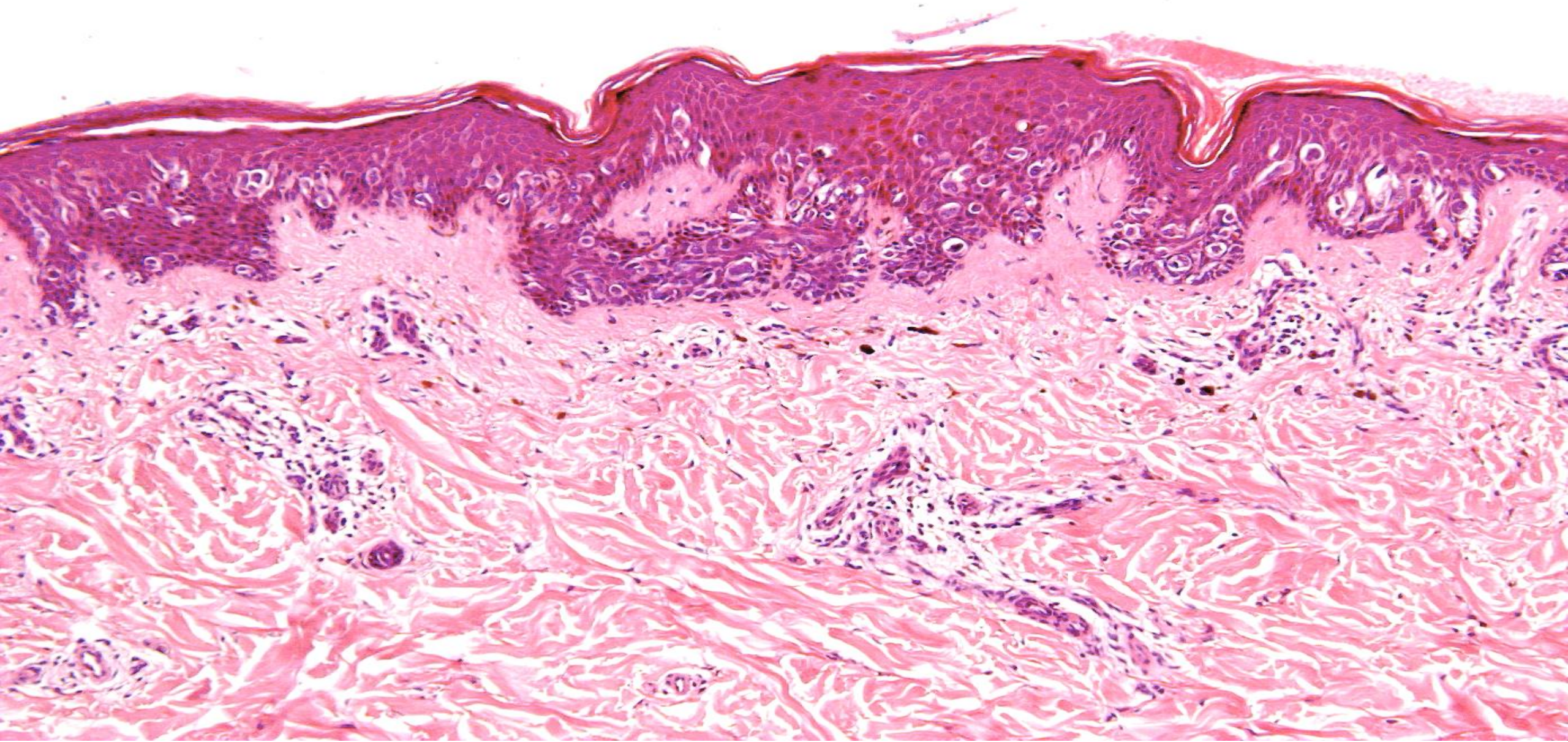
- The best diagnosis is:

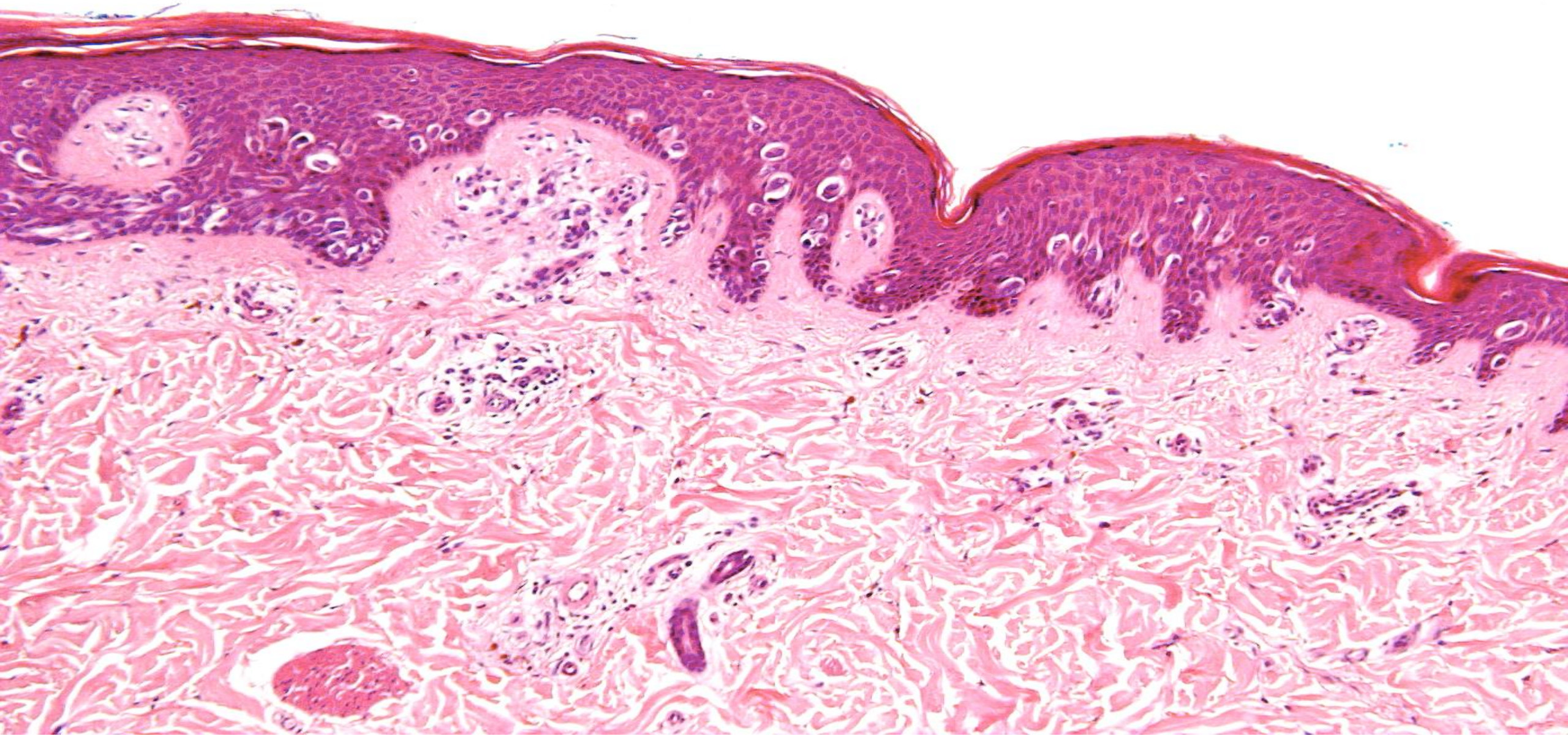
B. Intraepidermal Spitz naevus with pagetoid spread

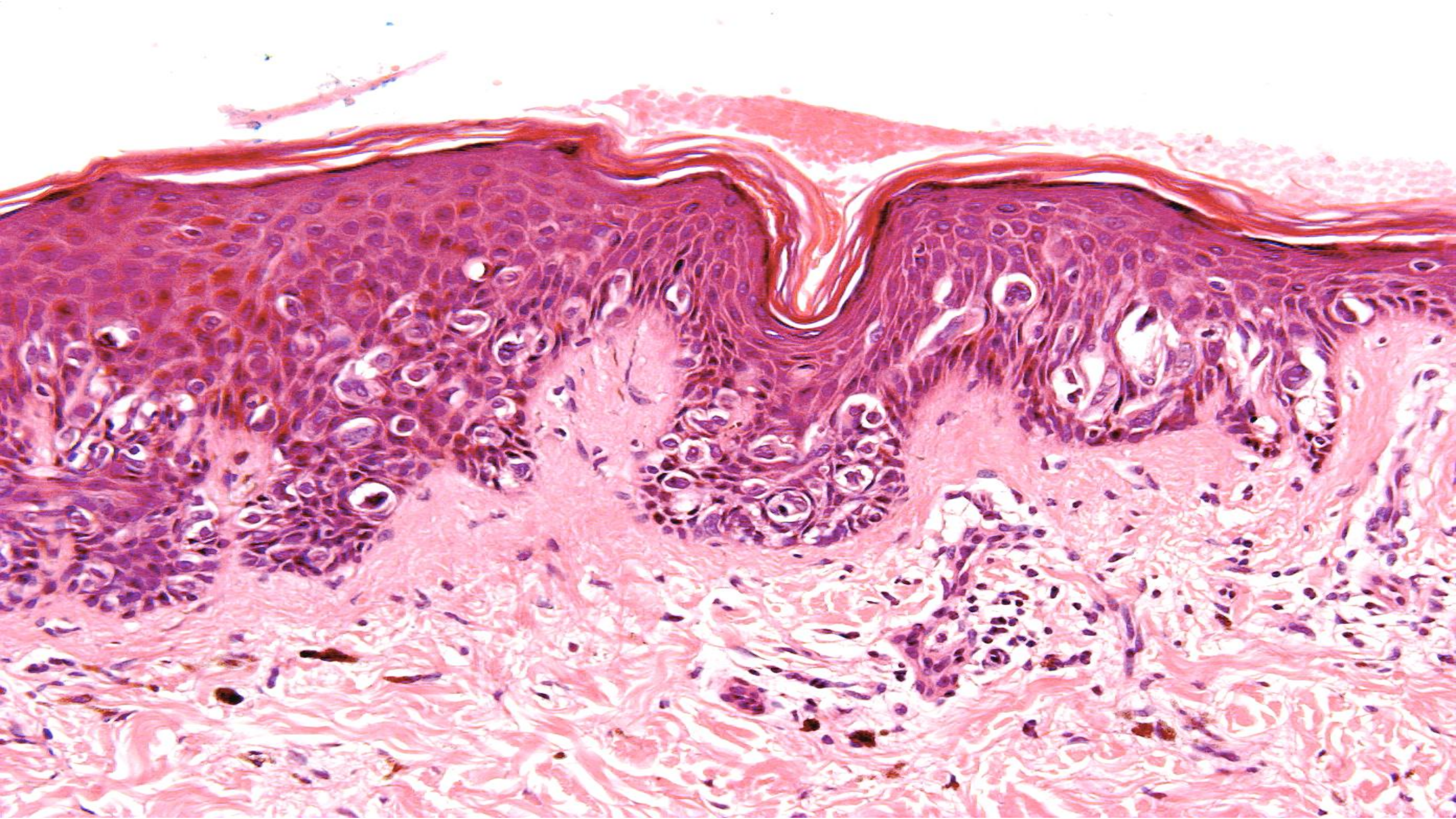
Another case...

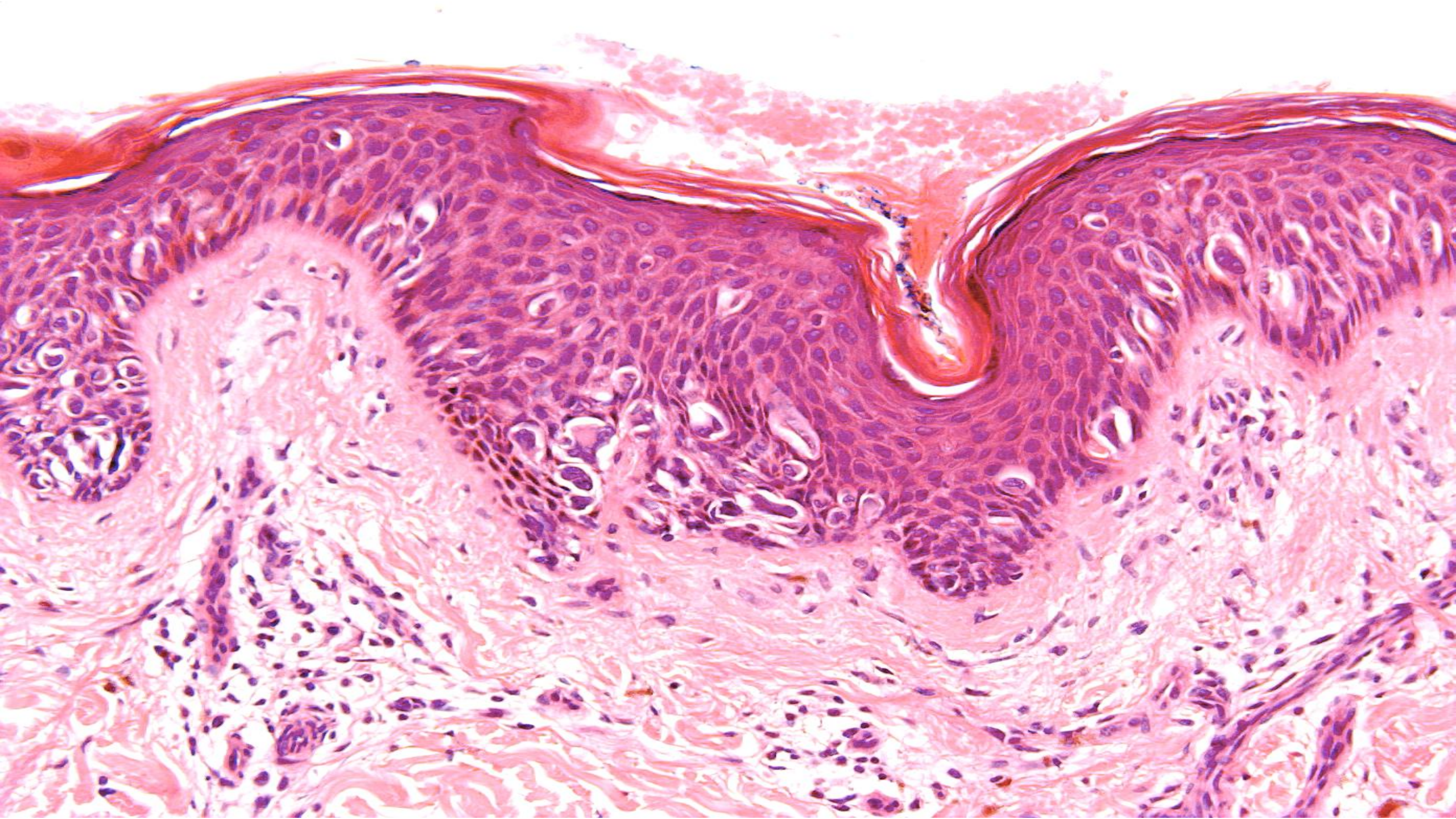


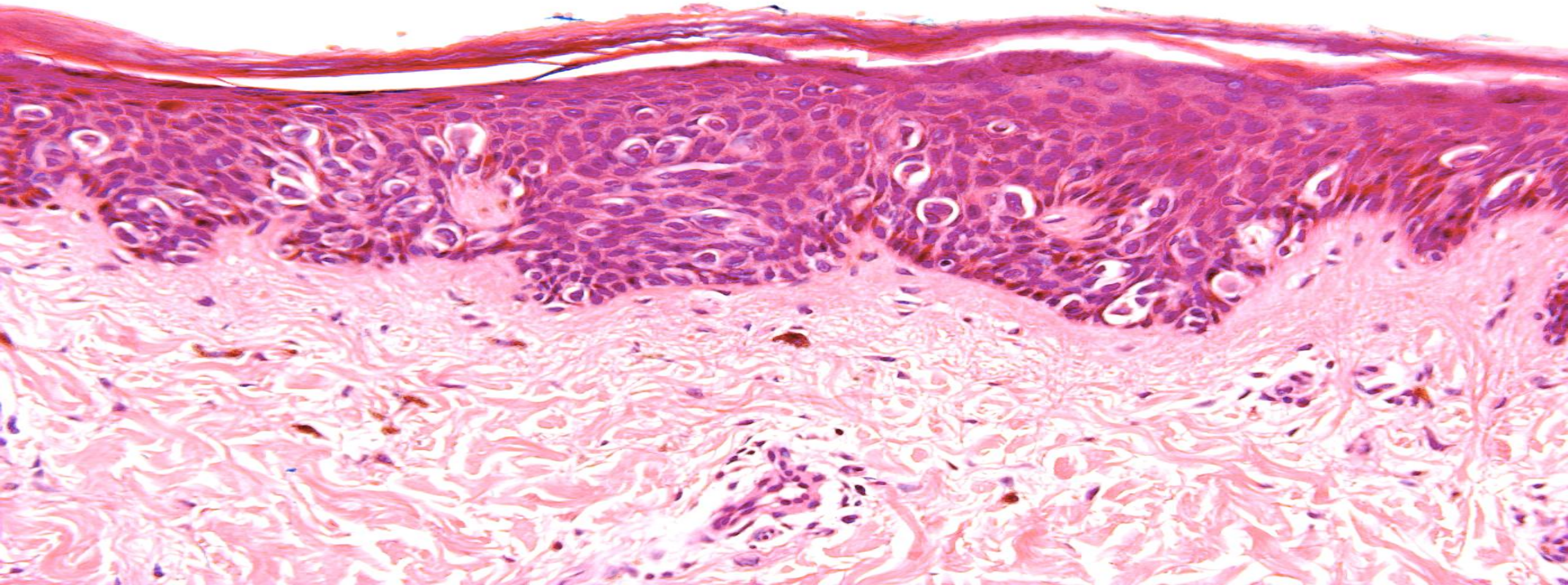












**Junctional Spitz naevus
(pagetoid Spitz naevus)**

INTRAEPIDERMAL SPITZ NAEVUS WITH PAGETOID SPREAD

- **Rare**
- **No distinctive clinical features**
- **Mainly in young patients**
- **Very difficult to distinguish from a superficial spreading melanoma in situ**
- **Most are junctional only**
- **Upward migration in individual units**
- **Angulated epithelioid cells with abundant pink cytoplasm**

Superficial Melanocytic Neoplasms With Pagetoid Melanocytosis

A Study of Interobserver Concordance and Correlation With FISH

Pedram Gerami, MD, Raymond L. Barnhill, MD,† Beth Ann Beilfuss, NA,* Philip LeBoit, MD,‡
Pierre Schneider, MD,† and Joan Guitart, MD**

24 cases

Pagetoid spitz nevi, de novo epithelioid melanocytic dysplasia, and melanoma

There is considerable **discordance (29%) in superficial melanocytic neoplasm with prominent pagetoid melanocytosis** even among expert consultants.

There is likely a subset of such cases where FISH can play a significant role as a diagnostic aid

FISH accurately identified as malignant 5 of 7 cases which had a consensus diagnosis of melanoma

None of the cases with a consensus diagnosis of benign were FISH positive

Two of 11 cases considered indeterminate by the judges were positive by FISH

De novo intraepidermal epithelioid melanocytic dysplasia: a review of 263 cases



J Cutan Pathol 2010; 37: 852–859

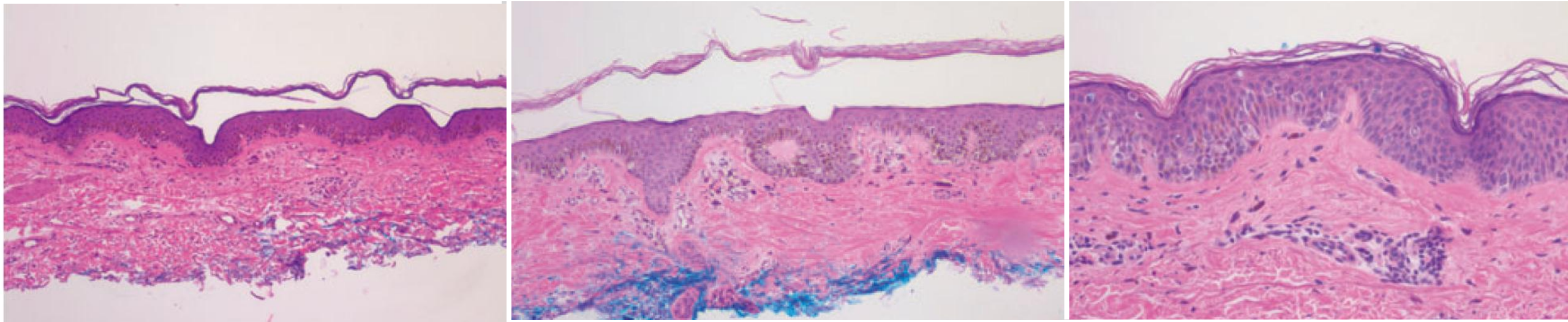


Table 2. Degrees of atypia within 257 described cases of DNIEMDs and 97 cases of DN with their percentages of cases with associated histories of MM per degree of atypia

	Mild	Mild to Moderate	Moderate	Moderate to Severe	Severe
DNIEMD (% assoc. with MM)	9 (11%)	43 (7%)	148 (6%)	35 (9%)	22 (23%)
DN (% assoc. with MM)	55 (15%)	11 (27%)	20 (5%)	5 (0%)	6 (50%)